Epileptologie | 30. Jahrgang
Juni | 2013 ISSN 1660-3656

Epilepsie-Liga
Seefeldstrasse 84
Postfach 1084
CH-8034 Zürich

Inhalt

Schweizerische Liga gegen Epilepsie
Ligue Suisse contre l'Epilepsie
Lega Svizzera contro l'Epilessia
Swiss League Against Epilepsy

Richtlinien für die Autoren

Allgemeines

Epileptologie veröffentlicht sowohl angeforderte als auch unaufgefordert eingereichte Manuskripte über alle Themen der Epileptologie. Es werden in der Regel nur bislang unveröffentlichte Arbeiten angenommen. Die Manuskripte oder wesentliche Teile daraus dürfen auch nicht gleichzeitig anderen Zeitschriften angeboten werden oder anderweitig bereits zur Publikation angenommen worden sein. Alle Manuskripte werden zweifach begutachtet. Von den Beiträgen werden keine Sonderdrucke erstellt, sie werden jedoch als pdf-Datei zusätzlich auf der Liga-Homepage (www.epi.ch) veröffentlicht und können von dort heruntergeladen werden.

Redaktionsanschrift

Unaufgefordert eingereichte Manuskripte (inkl. Briefe an die Herausgeber) sind zu richten an: Frau M. Becker, Redaktion Epileptologie, Schweizerische Liga gegen Epilepsie, Seefeldstr. 84, Postfach 1084, 8034 Zürich. Tel. 043 488 67 79, Fax 043 488 67 78, e-mail: becker@epi.ch.

Hinweise zur Manuskripterstellung

Manuskripte werden nur akzeptiert, wenn sie den folgenden Kriterien entsprechen. Nicht entsprechend abgefasste Manuskripte werden vor der Begutachtung zurückgesandt.

1. **Sprache:** Neben deutsch auch englisch und französisch möglich.
2. **Schreibweise (deutsch):** Als Schreibweise gilt die deutsche Form mit „z“ und „k“ (also z.B. Karzinom), lateinische Fachtermini behalten aber ihre Schreibweise (also z. B. Arteria carotis).
3. **Form:** Der gesamte Text, einschliesslich Literaturverzeichnis, Tabellen und Abbildungslegenden, ist folgendermassen zu formatieren:
   - DIN-A4-Papier, einseitig (1 1/2- oder 2-zeilig mit max. 30 Zeilen je Seite).
   - Literaturverweise werden gemäss der Reihenfolge, in der sie im Text vorkommen, arabisch nummeriert; im Text erscheinen die Verweiszahlen in eckigen Klammern.
   - Tabellen und Abbildungen haben eine jeweils fortlaufende arabische Nummerierung.
4. **Reihenfolge:** 1. Titelblatt (ggf. inkl. Danksagung, Förderung durch Hilfe anderer oder Drittmittelfinanzierung), 2. Zusammenfassung in Deutsch, Résumé in Französisch und Summary in Englisch sowie je drei bis fünf Schlüsselwörter, 3. Text, 4. Literatur, 5. Tabellen, 6. Abbildungslegenden und 7. Abbildungen:
   - Das Titelblatt enthält den vollen Titel der Arbeit (deutsch und englisch), Namen und Titel der Autoren, die Kliniken bzw. Institutionen, an denen alle Autoren arbeiten, sowie die vollständige Adresse des federführenden Autors mit Telefon- und Faxnummer sowie e-mail.
   - **Zusammenfassung, Résumé und englischer Abstract (mit Titel der Arbeit):** Ohne Literaturzitate und Akronyme sowie unübliche Abkürzungen (je maximal 250 Wörter).
   - **Text:** Dabei bei Originalarbeiten Gliederung in Einleitung, Methode (inkl. Untersuchungsmaterial, Patienten, Versuchstiere etc., ggf. auch Angabe über Einwilligung bzw. Einhaltung der Deklaration von Helsinki inkl. Votum einer Ethikkommission), Ergebnisse und Diskussion. Abkürzungen sind bei ihrem ersten Erscheinen im Text voll auszuschreiben.
   - **Literaturverzeichnis:** Am Ende der Arbeit werden die Literaturstellen in der im Text zitierten Reihenfolge aufgeführt und nach untenstehendem Muster zitiert. Persönliche Mitteilungen, unveröffentlichte Befunde oder zur Publikation eingereichte Manuskripte werden nicht aufgenommen, sondern entsprechend im Text vermerkt. Zitierungen „im Druck“ bzw. „in press“ beziehen sich nur auf von einer Zeitschrift bereits angenommene Arbeiten (mit Angabe von Zeitschrift und – soweit bekannt – Band und Erscheinungsjahr. Das Zitieren von Arbeiten als „in Vorbereitung“ oder „in preparation“ ist nicht zulässig. Kongressmitteilungen können nur als zitierbare Abstracts oder Beitrag in Proceedings-Bänden berücksichtigt werden.
   - **Tabellen:** Jede Tabelle steht auf einer neuen Seite und hat eine kurze erklärende Überschrift. Abkürzungen oder Zeichen sind in einer Fussnote zu erklären.
   - **Abbildungslegenden:** Die Legende für jede Abbildung steht auf einer neuen Seite; alle Abkürzungen oder Zeichen sind darin zu erklären.
   - **Abbildungen:** Strichzeichnungen, schattierte Zeichnungen oder Fotografien (SW oder Farbe).
   - **Zitierweise:** Zeitschriftenartikel: Daoud AS, Batieha A, Abu-Ekteish F et al. Iron status: a possible risk factor for the first febrile seizure. Epilepsia 2002; 43: 740-743 (bei bis zu vier Autoren werden alle genannt; Abkürzungen der Zeitschriften nach der „List of Journals indexed in Index Medicus“); Bücher: Shorvon S. Status Epilepticus. Its Clinical Features and Treatment in Children and Adults. Cambridge: Cambridge University Press, 1994; Buchkapitel: Holthausen H, Tuxhorn I, Pieper T et al. Hemispherectomy in the treatment of neuronal migrational disorders. In: Kotagal P, Lüders HO (eds): The Epilepsies. Etiologies and Prevention. San Diego, London, Boston et al.: Academic Press, 1999: 93-102

Was ist an die Redaktion einzureichen?

Alle Manuskripte sind inklusive Abbildungen und Tabellen in dreifacher Ausführung einzureichen. Bevorzugt wird eine elektronische Manuskripteinreichung per e-mail (Textverarbeitung: MS Word), alternativ die Zusendung von drei Ausdrucken und einer Diskette (für Abb. und Tab. ist das verwendete Programm anzugeben).

Des avancées dans le domaine de l'imagerie en épileptologie

Dr méd. Serge Vulliémoz

Cette édition d' « Epileptologie » traite des avancées dans le domaine de l'imagerie en épileptologie.

Les techniques d'enregistrement et d'analyse de l'imagerie cérébrale connaissent des progrès fulgurants et l'épileptologie est certainement une des disciplines cliniques qui profite le plus de ces développements d'imagerie. Les bénéfices sont certainement réciproques.

Le meilleur exemple est celui de l'évaluation pré-chirurgicale de l'épilepsie où l'imagerie est particulièrement cruciale pour détecter une lésion structurelle et localiser l'activité épileptique ainsi que les fonctions corticales éloquentes. Ceci permet de planifier le geste chirurgical ou une investigation invasive et de préciser le pronostic post-opératoire. Réciproquement cette nécessité clinique a largement attiré les applications cliniques de nouveaux outils d'imagerie et leur combinaison multimodale. De plus, la chirurgie de l'épilepsie offre également des possibilités uniques de validation des nouvelles techniques non-invasives grâce aux enregistrements EEG invasifs et à la chirurgie. Comme en témoigne ce numéro, les progrès en analyse quantitative de l'IRM structurelle, les nouveaux traceurs en médecine nucléaire, la validation de l'imagerie de source électro-magnétique EEG/MEG et les possibilités offertes par l'EEG-IRMf simultané illustrent parfaitement ce phénomène. Etant donné la multiplicité des techniques d'imagerie en développement, une validation rigoureuse reste particulièrement importante pour permettre leur application dans d'autres domaines cliniques ou fondamentaux qui ne bénéficient pas de telles possibilités.

Mais l'impact des progrès en imagerie sur l'épileptologie est bien plus profond encore: les différentes techniques montrent également que l'épilepsie focale ne concerne pas qu'une région isolée du cortex mais implique le dysfonctionnement complexe de réseaux corticaux et sous-corticaux étendus. De plus, les techniques de médecine nucléaires permettent une cartographie cérébrale moléculaire des dysfonctions métaboliques et même génétiques liées à l'épilepsie. L'étude de la « connectivité » de ces réseaux grâce à l'imagerie fonctionnelle, structurelle et moléculaire, ainsi que leur influence sur les réseaux d'activité physiologique (motricité, langage, mémoire, etc) est un domaine scientifique en plein essor. Ceci débouchera certainement sur une meilleure compréhension et classification des différentes formes d'épilepsie tout en proposant éventuellement des applications cliniques nouvelles pour influencer l'activité anormale des réseaux épileptiques, par « déconnexion » ou « neuromodulation ».

Je souhaite remercier de tout cœur les collègues et ami(e)s qui ont permis la réalisation de ce numéro grâce à leur contribution enthousiaste. Je suis particulièrement heureux d'avoir pu réunir des experts de différents horizons géographiques et de différentes spécialités médicales (neurologie, radiologie, médecine nucléaire), ce qui reflète l'aspect multidisciplinaire et international du « réseau des réseaux » ! Tous les articles ont été rédigé en anglais afin d'être accessibles au plus large public possible.

Bonne lecture !

Serge Vulliémoz

Dr. med. Serge Vulliémoz

This issue of "Epileptologie" focuses on advances in the field of epilepsy imaging. Strategies for recording and analysis in brain imaging are progressing at a tremendous pace and epileptology is certainly one of the clinical disciplines that benefits the most from these developments. The advantages clearly go both ways.

The best example is the presurgical evaluation of epilepsy, where imaging is particularly crucial for detecting a structural lesion and localising epileptic activity as well as eloquent cortical areas. This allows for better tailoring of surgical resections or invasive studies and for improved prediction of post-operative outcome. Reciprocally, this clinical need has been instrumental in attracting clinical applications of new imaging tools and their multimodal combination. Moreover, epilepsy surgery also offers unique possiblilities for validating new non-invasive techniques using invasive EEG and surgery. As described in this issue, the advances in quantitative post-processing of structural MRI, the new nuclear tracers, the validity of electro-magnetic source imaging (EEG/MEG) and the possibilities offered by simultaneous EEG-fMRI perfectly illustrate this trend. It is important that the multiplicity of imaging techniques currently being developed undergo rigorous validation so that they can be applied in other clinical or basic neuroscience disciplines that are unable to validate them.

But the effect of advances in imaging on epileptology goes far beyond that: the different techniques have also shown that focal epilepsy not only corresponds to an isolated dysfunctional cortical region, but implies a complex dysfunction of widespread cortical and subcortical networks. Moreover, nuclear medicine techniques allow mapping of these networks at the molecular level of neurotransmitter dysfunction and genetic abnomalities related to epilepsy. The use of functional, structural and molecular imaging for studying the "connectivity" of these networks and their influence on physiological networks (memory, language, etc) is a fast-growing scientific field. It will certainly foster a better understanding and classification of epilepsy syndromes, which may lead to new clinical applications for influencing the abnormal activity of epileptic networks, using "disconnection" or "neuromodulation".

I would like to whole-heartedly thank the colleagues and friends who made this issue possible with their enthusiastic contribution. I am particularly happy to have been able to bring together experts from different geographic horizons and from different medical specialties (neurology, radiology, nuclear medicine) reflecting the multidisciplinary and international aspect of the "network of the networks"! All articles have been written in English, with the goal of reaching the widest possible readership.

Bonne lecture !

Serge Vulliémoz

Fortschritte auf dem Gebiet der Bildgebung bei Epilepsie

Dr. med. Serge Vulliémoz

Diese Ausgabe der Zeitschrift "Epileptologie" ist den Fortschritten auf dem Gebiet der Bildgebung bei Epilepsie gewidmet. Die Techniken der Aufnahme und Analyse der Hirnbildgebungsdaten verbessern sich in rasantem Tempo, und Epileptologie ist eine der Disziplinen, die von dieser Entwicklung am meisten profitieren. Die Vorteile gehen sicher in beide Richtungen.

Das beste Beispiel ist die prächirurgische Abklärung bei Epilepsie, wo die Bildgebung besonders entscheidend ist beim Erfassen einer strukturellen Läsion, beim Lokalisieren von epileptischer Aktivität und von funktionnell wichtigen kortikalen Regionen. Sie ermöglicht massgeschneiderte Chirurgie oder präzise invasive Untersuchungen und verbessert die postoperative Prognose. Diese klinischen Interessen haben dazu geführt, dass neue Anwendungen getestet und verschiedene Verfahren kombiniert wurden. Ausserdem bietet Epilepsiechirurgie einmalige Gelegenheiten, neue, nichtinvasive Techniken dank invasivem EEG und Chirurgie zu validieren. Wie in dieser Ausgabe der Zeitschrift beschrieben, wird dieses Phänomen durch die Fortschritte in der Nachverarbeitung der strukturellen MRT, die neuen Tracer in der Nuklearmedizin, die Auswertung der elektro-magnetischen Quellenlokalisation mit EEG/MEG und die Möglichkeiten von simultanen EEG-IRMf eindrücklich illustriert. Angesichts der Vielzahl bildgebender Techniken, die heute zur Verfügung stehen, ist eine kritische Überprüfung sehr wichtig, bevor sie für andere klinische Disziplinen oder die Grundlagenforschung bewilligt werden.

Aber die Bedeutung des Fortschritts in der Bildgebung geht noch weiter: die verschiedenen Techniken haben aufgezeigt, dass fokale Epilepsien nicht nur auf eine dysfunktionale kortikale Region zurückzuführen sind, sondern dass vermutlich eine komplexe Dysfunktion von weiter verbreiteten kortikalen und subkortikalen Netzwerken daran beteiligt ist. Ausserdem bilden Verfahren aus der Nuklearmedizin ebenfalls diese Netzwerke ab und zwar auf der molekularen Ebene der Neurotransmitterdysfunktionen und der genetischen Anomalien, welche mit Epilepsie in Verbindung gebracht werden. Die Verwendung von funktionaler, struktureller und molekularer Bildgebung zur Untersuchung der Verbindung dieser Netzwerke und deren Einfluss auf physiologische Netzwerke wie Gedächtnis und Sprache ist ein rasch wachsendes Forschungsfeld, das gewiss zu einem besseren Verständnis und zur genaueren Klassifikation von Epilepsiesyndromen führen wird. Dies wiederum inspiriert neue klinische Anwendungen in Richtung Beeinflussung der abnormalen Aktivität epileptischer Netzwerke im Sinne von Bahnenunterbrechung oder Neuromodulation.

Ich möchte hier von ganzem Herzen den Kollegen und Freunden danken, welche mit ihren enthusiastischen Beiträgen zur Realisation dieses Hefts beigetragen haben. Besonders freut mich, dass die Autoren aus unterschiedlichen geografischen Regionen und verschiedenen medizinischen Fachgebieten wie Neurologie, Radiologie, Nuklearmedizin stammen, was die Multidisziplinarität und den internationalen Aspekt des „Network of the networks" widerspiegelt. Alle Artikel wurden bewusst auf Englisch verfasst mit dem Ziel, möglichst vielen Leserinnen und Lesern zugänglich zu sein.

Bonne lecture!

Serge Vulliémoz

Postprocessing of Structural MRI in the Presurgical Evaluation of Epilepsy Patients

Hans-Jürgen Huppertz, Judith Kröll, Martin Kurthen and Thomas Grunwald
Schweizerisches Epilepsie-Zentrum Zürich

Summary

Using the example case of a former patient as a guiding line, the article gives an overview of several novel methods of computer-assisted MRI postprocessing and their clinical application in non-invasive and invasive presurgical evaluations of epilepsy patients. Morphometric MRI analysis facilitates the detection and delineation of subtle focal cortical dysplasias and other cortical malformations by highlighting typical structural alterations like thickening of the cortical ribbon, blurring of the grey-white matter junction, and abnormal gyration. Automatic curvilinear reformatting of 3D MRI data calculates serial convex planes across the brain in different depths from the cortical surface. This method improves the display of the gyral structure, permits a precise localization of lesions, and helps to identify subtle abnormalities difficult to detect in planar slices. Pre-operative planning of subdural electrode implantation for invasive EEG recordings by means of realistic 3D representation of electrode contacts is a novel method that allows calculating electrode positions directly on the convexity of the individual cortical surface and in correct spatial proportions with respect to brain size. Thereby it permits rapid and exact determination of optimal electrode positions and supports planning and execution of electrode implantation. After implantation, the positions of subdural electrodes can be determined by help of an automated fast method for volume rendering of 3D MRI at the level of the implanted electrodes. The results of all presented methods can be integrated into intra-operative neuronavigation systems to support final lesion resection. After surgery, coregistration of pre- and postoperative images makes it possible to confirm the completeness of lesion resection. In conclusion, a variety of MRI postprocessing methods aids in the presurgical evaluation and surgical management of medically refractory epilepsy patients.

Epileptologie 2013; 30: 90 – 100

Key words: Epilepsy, magnetic resonance imaging, MRI postprocessing, morphometric analysis, focal cortical dysplasia, electrode implantation

Digitale Nachverarbeitung von strukturellen MRI-Aufnahmen in der prächirurgischen Diagnostik von Epilepsiepatienten

Am Beispiel einer früheren Patientin gibt der Artikel einen Überblick über verschiedene neuartige Verfahren der computergestützten MRI-Nachverarbeitung und ihre klinische Anwendung in der nicht-invasiven und invasiven prächirurgischen Abklärung von Epilepsiepatienten. Morphometrische MRI-Analyse erleichtert die Erkennung und Abgrenzung von diskreten fokalen kortikalen Dysplasien und anderen kortikalen Fehlbildungen durch Hervorhebung typischer struktureller Veränderungen wie zum Beispiel einer abnormen Dicke der Hirnrinde, einer verwaschenen Markrindengrenze oder einer abnormen Gyrierung. Die automatisierte kurvilineare Reformatierung von 3D MRI-Daten berechnet serielle konvexe Schnittebenen durch das Gehirn in unterschiedlichen Tiefen unterhalb der kortikalen Oberfläche. Das Verfahren verbessert die Darstellung der Gyrierung und Sulkuszeichnung, ermöglicht eine genaue Lokalisation von Läsionen und hilft, diskrete Fehlbildungen zu entdecken, die in herkömmlichen planaren Schichtaufnahmen schwer zu identifizieren sind. Die präoperative Planung subduraler Elektrodenimplantationen für invasive EEG-Aufzeichnungen mittels realistischer 3D-Darstellung der Elektrodenkontakte ist ein neuartiges Verfahren, das es erlaubt, Elektrodenpositionen direkt auf der Konvexität der individuellen kortikalen Oberfläche und in korrekten Grössenverhältnissen in Bezug auf das Patientenhirn zu berechnen. Dadurch ermöglicht es eine schnelle und genaue Bestimmung der optimalen Elektrodenpositionen und unterstützt die Planung und Durchführung der Elektrodenimplantation. Nach der Implantation werden die Positionen der subduralen Elektroden mit Hilfe eines schnellen automatisierten Verfahrens bestimmt, welches ein Volumen-Rendering von 3D MRI-Aufnahmen auf Ebene der implantierten Elektroden durchführt. Die Ergebnisse aller vorgestellten Methoden können in intraoperative Neuronavigationssysteme integriert werden, um die abschliessende Resektion der Läsion zu unterstützen. Danach kann mittels Koregistrierung der prä- und postoperativen MR-Bilder überprüft werden, ob die Läsion vollständig entfernt wurde. Zusammenfassend hilft eine Vielzahl von Methoden zur Nachverarbeitung von MRI-Aufnahmen bei der präoperativen Evaluation

und chirurgischen Behandlung von medikamentös therapieresistenten Epilepsie-Patienten.

Schlüsselwörter: Epilepsie, Magnetresonanztomografie, MRT-Nachverarbeitung, morphometrische Analyse, fokale kortikale Dysplasie, Elektrodenimplantation

Traitement numérique et quantitatif des images IRM structurelles dans le bilan pré-chirurgical des patients atteints d'épilepsie

Par l'exemple d'un ancien patient, l'article donne un aperçu des nouvelles méthodes d'analyse assistée par ordinateur de l'IRM cérébrale et leurs applications cliniques dans le bilan pré-chirurgical non invasif et invasif des patients atteints d'épilepsie. L'analyse morphométrique IRM facilite la détection et la différenciation des dysplasies corticales focales discrètes et d'autres malformations corticales en mettant en évidence les changements structurels typiques tels que l'épaisseur anormale du cortex, une limite floue entre substance grise et substance blanche, ou une gyrification anormale. Le reformatage automatique curvilinéaire des données 3D IRM est calculé par une série convexe de plans de coupe à travers le cerveau à différentes profondeurs sous la surface corticale. La procédure améliore l'apparence de des gyri et sulci, permet une localisation précise des lésions et permet de détecter des anomalies discrètes qui sont difficiles à identifier dans les images planaires conventionnelles. La planification de l'implantation d'électrodes sous-durales pour les enregistrements EEG invasifs à l'aide d'une représentation 3D réaliste des contacts des électrodes est une nouvelle méthode, qui permet de calculer directement la position des électrodes sur la convexité de la surface corticale individuelle dans les rapports de taille correcte par rapport au cerveau du patient. Cela permet la détermination rapide et précise de la position optimale des électrodes et aide la planification et la mise en œuvre de l'implantation. Après l'implantation, les positions des électrodes sous-durales sont déterminées en utilisant une méthode automatisée rapide qui est un rendu de volume 3D de l'IRM au niveau des électrodes implantées. Les résultats de toutes les méthodes peuvent être intégrés dans des systèmes de neuronavigation peropératoires pour soutenir la résection finale de la lésion. Par la suite, une coregistration pré- et post-opératoire de l' IRM permet de vérifier si la lésion a été complètement enlevée. En résumé une variété de méthodes de post-traitement des images IRM offre une aide précieuse dans le bilan préopératoire et la planification de la chirurgie chez les patients atteints d'épilepsie pharmaco-résistante.

Mots clés : Epilepsie, imagerie par résonance magnétique, analyse complémentaire de l'IRM, dysplasie corticale focale, implantation d'électrodes

Abbreviations

MRI	= magnetic resonance imaging
SPM	= statistical parametric mapping
VBM	= voxel-based morphometry
FLAIR	= fluid attenuated inversion recovery
FCD	= focal cortical dysplasia
SBH	= subcortical band heterotopia
PNH	= periventricular nodular heterotopia
HS	= hippocampal sclerosis

Introduction

During the past years computer-assisted digital postprocessing of structural MRI data has increasingly found entrance into routine clinical diagnostics. In epileptology, a variety of methods are available, not only to improve detection and visualization of subtle epileptogenic lesions but also to plan invasive EEG recordings, to localize implanted electrodes and to assist intra-operative neuronavigation. This article gives an overview of these methods and their clinical application in the presurgical evaluation of epilepsy patients. The methods presented here are in daily use at the Swiss Epilepsy Centre and mostly based on algorithms and standard procedures of the SPM5 software package (SPM = statistical parametric mapping, Wellcome Trust Centre for Neuroimaging, London, UK; http://www.fil.ion.ucl.ac.uk/spm). In principle, however, they can also be implemented in other freeware image-processing environments such as, for example, the FMRIB Software Library (FSL; http://www.fmrib.ox.ac.uk/fsl) or the AFNI software (http://afni.nimh.nih.gov/afni). The subsequent presentation follows the typical sequence of diagnostic procedures in a former patient with drug-resistant epilepsy who underwent non-invasive and invasive presurgical evaluations. The overview roughly sketches the methods and describes what results can be expected from MRI postprocessing and how they contribute during the diagnostic workup. The available space does not allow explaining technical details of the postprocessing techniques; however, the interested reader is referred to the primary literature on this topic (cf. references).

Description of the Example Case

The example case is a former patient, a 30year-old female, who suffered from left-sided tonic and secondarily generalized tonic-clonic seizures since the age of two years. EEG and semiology pointed to an epileptogenic focus in the right frontal or right precentral region. Results from nuclear medicine (i.e. SPECT) supported this hypothesis. However, at referral the patient's epilepsy was considered to be cryptogenic since two MRI investigations in the past had been regarded as normal.

Morphometric MRI Analysis

Although MRI techniques have markedly improved over the last years, conventional MRI frequently does not reveal the underlying pathology in focal epilepsy. The detection of an epileptogenic lesion on MRI, however, is crucial since the selection of candidates for possible epilepsy surgery is easier and postoperative outcome is significantly better in MRI-positive patients [1, 2]. Therefore, attempts have been made to facilitate lesion detection by modern image post-processing strategies like curvilinear reformatting of 3D MRI [3], quantifying the regional distribution of gray and white matter by voxel-based morphometry or autoblock analysis [4 - 9], measuring the thickness of the cerebral cortex [10], texture analysis [11 - 13], or quantitative intensity analysis [14 - 16]. In addition, there have been promising approaches for automated lesion detection, for example by searching for maximum deviations with respect to a normal database [17, 18], by using a Bayesian classifier [12], by thresholding z score maps [19], by applying classifiers based on neural networks [20], or by statistical parametric mapping either applied to structural data in the framework of voxel-based morphometry or combined with signal intensity analysis. An overview of the different approaches can be found in the review by Bernasconi and co-workers in 2011 [21].

One of these approaches is a method for *morphometric* MRI analysis based on algorithms of SPM5 and comparing voxel-wisely individual brain anatomy with a normal database. The whole processing is performed by a fully automated MATLAB® script. The starting point is a high-resolution 3D MRI dataset covering the whole head and brain. Usually, a T1-weighted volume data set is used which is part of the recommended routine MRI protocol for epilepsy patients [22, 23], but the technique has also been successfully applied to T2-weighted images [24]. Following the principles of VBM [25], the MRI data is normalized to the standard brain of the Montreal Neurological Institute (MNI) included in the SPM5 distribution, segmented into different brain compartments, i.e. grey matter (GM), white matter (WM), and cerebrospinal fluid, and simultaneously corrected for small intensity inhomogeneities. Normalization means that the individual brain is brought into a common anatomical space to make it comparable with a dedicated normal database, i.e. MRI data of healthy controls processed in the same way and preferably also acquired at the same MR scanner and with the same sequence as the patient's data. The segmentation results are compared with the distribution of GM and WM in the normal database, and three new morphometric maps (called "extension", "junction", and "thickness image") are derived, which characterize three different potential features of focal cortical dysplasia (FCD) and also other cortical malformations: abnormal extension of grey matter into white matter (i.e. abnormal deep sulci, abnormal gyration), blurring of the grey-white matter junction, and abnormal thickness of the cortical ribbon. By highlighting suspicious brain regions, these maps can guide a second look at the MRI and thereby increase the sensitivity for detecting subtle epileptogenic lesions [17, 18, 26 - 31]. The results can be integrated into intra-operative neuronavigational systems [32, 33] to guide the placement of subdural or depth electrodes or the final lesion resection.

Although this method has proven to facilitate the recognition of various malformations of cortical development, such as subcortical band heterotopia, polymicrogyria, and periventricular nodular heterotopia [34, 35], it is primarily meant to support the detection and visualization of FCD, which are the most frequent histopathologic substrate in children and the second most common etiology in adult epilepsy surgery patients [36]. The diagnostic yield has recently been investigated in a large study on 91 patients with histologically proven FCD operated on between 2000 and 2010 at the epilepsy centre of Bonn. Compared to visual MRI analysis alone, the additional application of morphometric analysis could increase lesion detection by about 12% [31]. However, since the study also included MRI data acquired 10 years ago, i.e. at a time when quality of MRI acquisition as well as radiological knowledge and awareness of dysplastic lesions probably were not as high as today, the study may overestimate the diagnostic yield. In addition, the detection rate is smaller in an unselected population, comprising for example also patients with non-epileptic seizures or with idiopathic epilepsies. At the Swiss Epilepsy Centre, morphometric analysis is applied to all MRI containing a T1-weighted 3D data set, and the additional diagnostic yield currently (after almost 3000 patients since 2006) ranges between 5 and 6% (unpublished data). This may appear small but for the involved patients it is most relevant. Resective surgery is considered the most effective therapy [37], and with the detection of a dysplastic lesion in a patient with formerly cryptogenic and medically refractory epilepsy it often comes within reach for the first time thus radically changing the prognosis of possible seizure freedom.

With regard to possible false-positive results it is important to take into account that morphometric analysis as well as the other postprocessing methods presented here are meant to be informative on a single patient level. In contrast to group studies with scientific goals, in which the risk of type I error (i.e. false-positive results) has to be minimized, it is more important to reduce the risk of type II errors, i.e. the possibility of false-negative results, in the clinical setting of an epilepsy surgery program. This is due to the fact that the detection of an epileptogenic lesion is often the only chance for the patient to enter such a program, and it determines the probability of being admitted to surgical therapy. The trade-off of a higher sensitivity, i.e. the increased risk of false-positive findings, is accept-

able because before surgery, the epileptogenicity of a probable lesion has to be proven not by MRI findings or postprocessing results but from compatible results of EEG and seizure semiology. Moreover, lesion detection is not the only goal. An improved visualization and delineation of lesion extent is also important because post-operative seizure freedom particularly depends on the completeness of lesion resection [38].

In our example patient, morphometric analysis highlighted a small structural alteration and possible lesion at the lower end of the right central region (**Figure 1**), with features typical for an FCD, such as abnormal gyration, blurring of the GM-WM junction and abnormal cortical thickness.

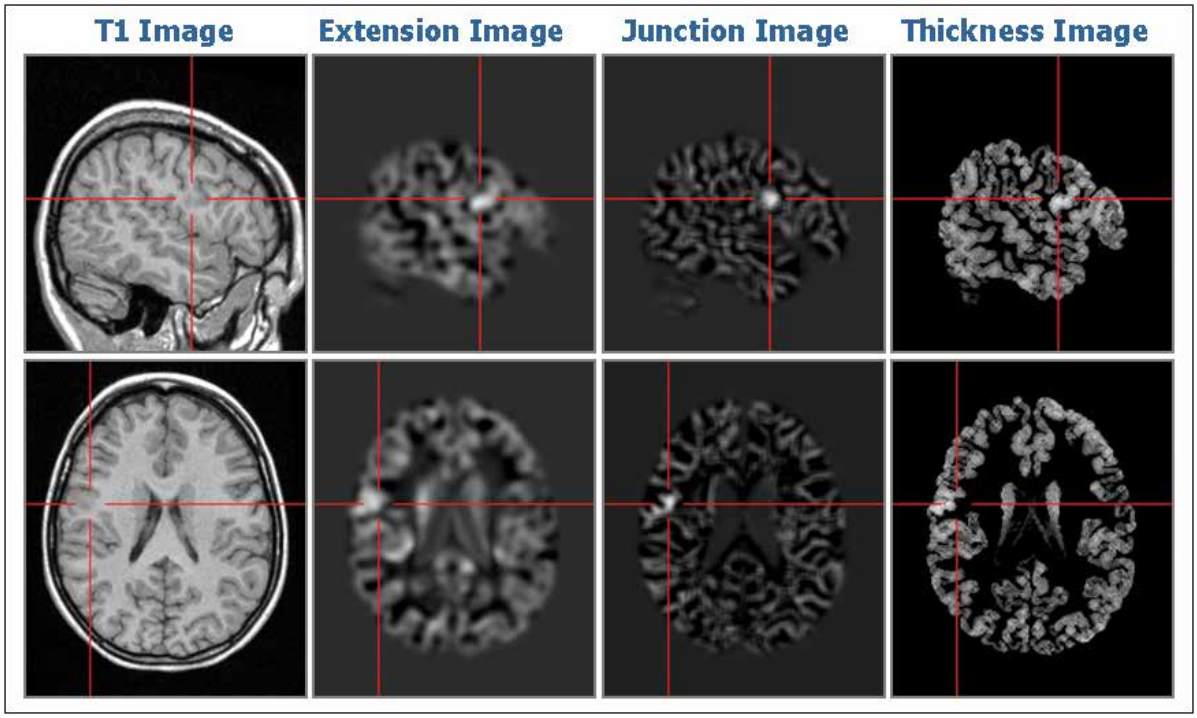

Figure 1: Morphometric MRI analysis: From the original T1 volume data set (left column), three new feature maps were calculated, which in our example patient who suffered from so far cryptogenic focal epilepsy highlighted abnormal gyration/an abnormally deep sulcus (cf. Extension Image), blurring of the GM-WM junction (Junction Image) and abnormal cortical thickness (Thickness Image) in the lower central region of the right hemisphere, suggestive of a focal cortical dysplasia (FCD).

Quantitative FLAIR Analysis

Apart from structural changes, cortical malformations like FCDs may also be accompanied by hyperintensities in T2 images or FLAIR (= fluid attenuated inversion recovery) scans, i.e. images with T2-weighted contrast but complete suppression of the high signal intensity of cerebrospinal fluid (CSF). Since morphometric analysis only refers to *structure*, an additional postprocessing method for exploiting also *signal* alterations would be advantageous. Focke and coworkers have recently described a new method for quantitative analysis of FLAIR scans [16, 39]. Their method essentially performs a rescaling and intensity normalization of the FLAIR image to a common mean level so that the patient FLAIR image can be compared with a normal database of FLAIR scans which have been intensity normalized in the same way. The approach avoids difficulties due to partial volume effects with CSF which are to consider for alternative quantitative methods like T2 relaxometry [40 - 42]. Compared to T2 mapping with FLAIR CSF suppression [14, 15], it does not require a special FLAIR T2 map, which has a long acquisition time and is often not available, but takes a standard clinical 2D or 3D FLAIR spin echo sequence as input. The further processing includes both a spatial and intensity normalization of the FLAIR images by using internal reference regions and spatial normalization parameters derived from combined normalization and segmentation of a coregistered T1-weighted image. The normalized and rescaled FLAIR images are then the starting point for a whole brain FLAIR analysis, which has been shown to be successful in the detection of focal cortical dysplasia [16].

In our example patient, quantitative FLAIR analysis highlighted a subtle hyperintensity at the location of the suspected dysplasia which had been overlooked in the original FLAIR images (**Figure 2**).

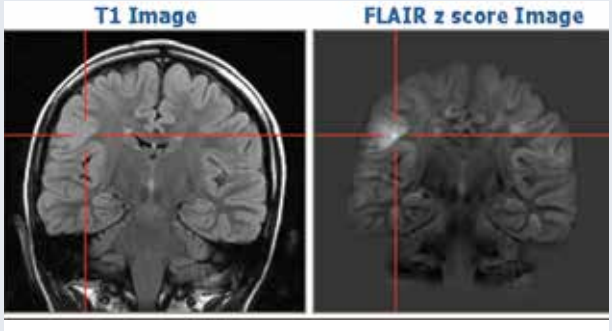

Figure 2: Quantitative FLAIR analysis: The original FLAIR scan (left side), which had been regarded as normal, was rescaled, intensity normalized, and compared with a normal database. In the resulting FLAIR z score image (right side) the suspicion of a dysplastic lesion was further corroborated by the finding of subtle signal hyperintensity.

to be sensitive for secondary epileptogenesis. For that purpose, the normalized and rescaled FLAIR images are thresholded and weighted by a probabilistic hippocampal mask to determine the average FLAIR intensities of the left and the right hippocampus. In a recent study, this method was applied to MRI data of 103 patients with hippocampal sclerosis (HS) and 131 controls. A 95% confidence region calculated from the FLAIR intensities of controls was used as threshold to discriminate both groups. One hundred patients, and among those all 23 patients with histologically confirmed HS, fell outside the 95% confidence region, thus amounting to 97.1% sensitivity. All but 6 controls (= 95.4%) were found within the confidence region, corresponding to the expected specificity. Right and left HS were separated without overlap. This approach could also distin-

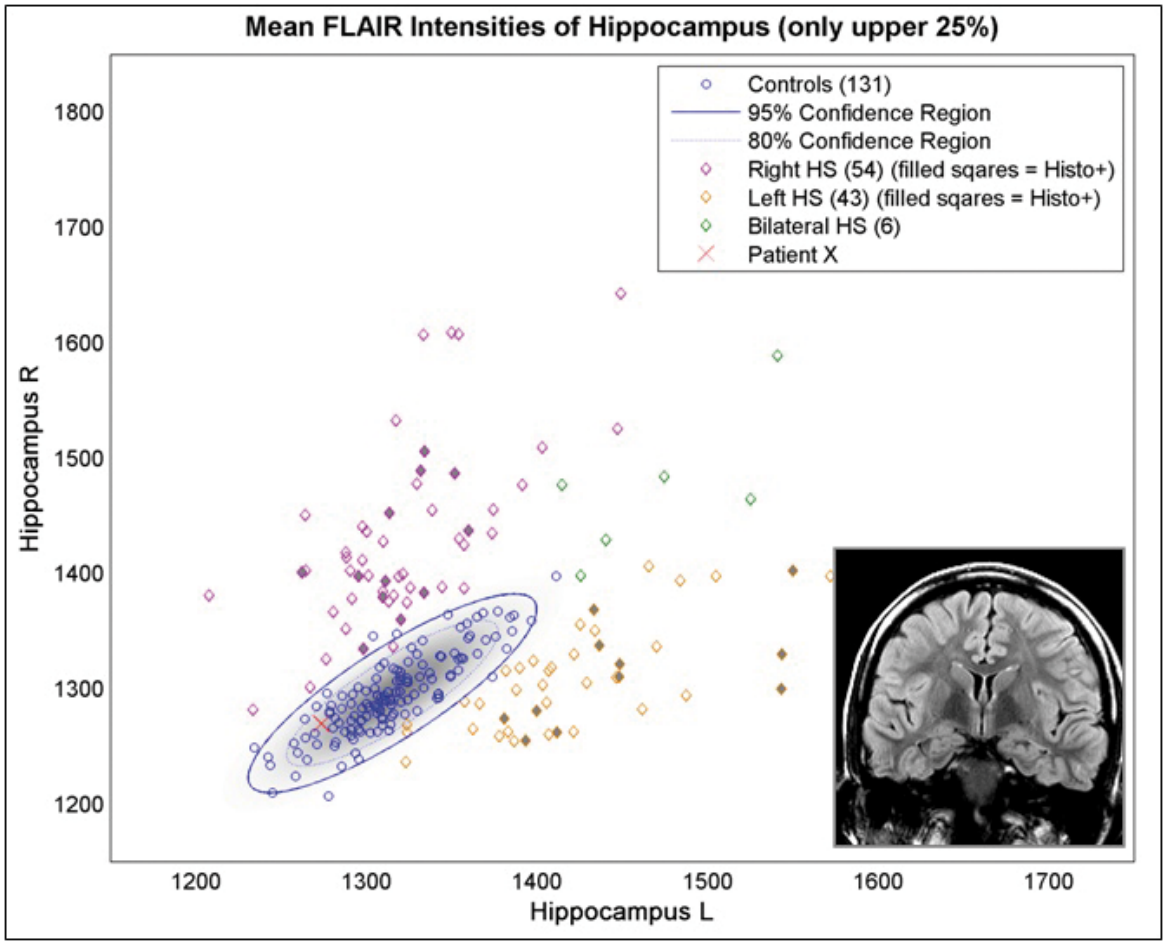

Figure 3: Quantitative hippocampal FLAIR analysis: The results of the example patient falling in the middle of the 95% confidence region of healthy controls confirm the visual impression that there is no dual pathology in terms of an additional hippocampal sclerosis.

As a further development of the *whole* brain FLAIR analysis described above, the quantitative evaluation can also be focussed on regions of interest, for example the hippocampi, to disclose or exclude an accompanying sclerosis in these structures which are known

guish cases of bilateral HS in which a side comparison is hampered, and it visualized signal changes over time after status epilepticus. The automated image processing steps render the method objective and time-efficient while the use of conventional T1 and FLAIR im-

ages already belonging to MRI protocols for epilepsy is economic [43].

In clinical routine, the main advantage lies in the fact that quantitative FLAIR analysis can corroborate the results of visual assessment in HS and – perhaps even more important – can strengthen confidence that the hippocampi are *not* affected. The presence of HS can be regarded as very unlikely when FLAIR analysis results in a location in the middle of the 95% confidence region, as in our example patient (**Figure 3**). This helps to rule out the possibility of a dual pathology.

Curvilinear Reformatting

Curvilinear reformatting of three-dimensional MRI data is a well-established technique to calculate serial convex image planes across the brain and parallel to the cortical surface [3]. Several advantages have been attributed to this method: a better display of gyral contours, precise localisation of lesions, improved visualization of lesion extent, and better assessment of spatial relations between lesions, anatomical landmarks, and implanted subdural electrodes [44], thus supporting surgical planning [45, 46]. Since this method also helps to identify subtle abnormalities, which are difficult to detect in planar slices due to the brain's complex convolutional pattern, it has been proposed for detecting small FCDs [3, 47]. Alternative 2D techniques [48] and the commonly used "pancake" representation of the cortex, sometimes also called "curved reconstructions" [49] or "brain surface reformatted imaging" [50 - 52], lack the 3D visualization of the gyral surface and suffer from relative distortions of distances. However, the initial implementation of curvilinear reformatting required an interactive delineation of the brain surface contour by manual placing of supporting points at the cortical surface. Then, a program calculated several new curved cutting planes across these points and below of them, allowing an overview of the brain in different depths. To spare the manual and time-consuming placement of supporting points, a fully automated alternative approach based again on SPM algorithms has been developed [53]. When the patient's brain is normalized to a standard brain (as has been done for morphometric analysis described above), predefined masks of different sizes can be applied in the same stereotactic space to cover and remove the skull and the outer brain regions in different depths from the brain surface. The residual inner part of the brain can then be presented 3-dimensionally by volume rendering (**Figure 4**). If necessary (e.g., for intraoperative navigation), the normalized data can be easily transferred back to the original stereotactic space.

Today, the results of automated curvilinear reformatting of 3D MRI data are primarily used to improve the visualization of epileptogenic lesions and the assessment of lesion extent and spatial relations to eloquent cortical regions. Lesion detection has receded in importance due to more successful methods like morphometric analysis. However, confirmation of a suspected lesion is still valuable. In our example patient, the method revealed that the suspected lesion was located at the lateral end of the right central sulcus and indeed accompanied by blurring of the gray-white matter junction (**Figure 4**).

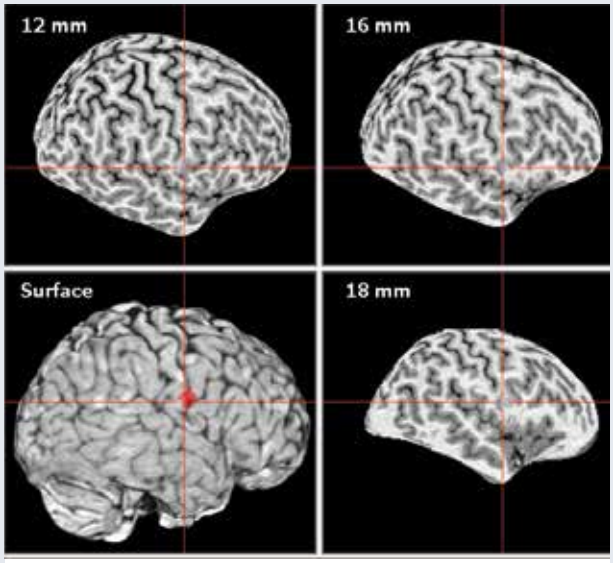

Figure 4: Curvilinear reformatting of 3D MRI data: The figure shows several new curved cutting planes in different depths from the cortical surface and at different viewing angles. The results of morphometric analysis can be projected into these images (cf. the red patch at the surface level). The location of the suspected dysplastic lesion at the lateral end of the right central sulcus is much easier to ascertain than on conventional planar images.

Planning of Electrode Implantation

Since the suspected lesion was located in the central region, presurgical evaluations had to proceed with invasive EEG recordings and mapping of sensory-motor functions to differentiate the epileptogenic zone from possible eloquent cortical areas that are to spare in the final resective surgery. For invasive EEG recordings optimal topographic concordance of implanted subdural electrodes with suspected epileptogenic and relevant eloquent cortical areas is essential. The implantation of subdural strip and grid electrodes is usually planned by designing schematic drawings where 2-dimensional electrode images are placed on pseudo-3D images of a standard brain. The disadvantage is obvious: there is no correlation between the size of the electrodes and the size of the individual patient brain. An improvement would be an image of the individual patient's brain surface (as derived from simple skull-stripping of 3D MRI data), brought together with electrode images of corre-

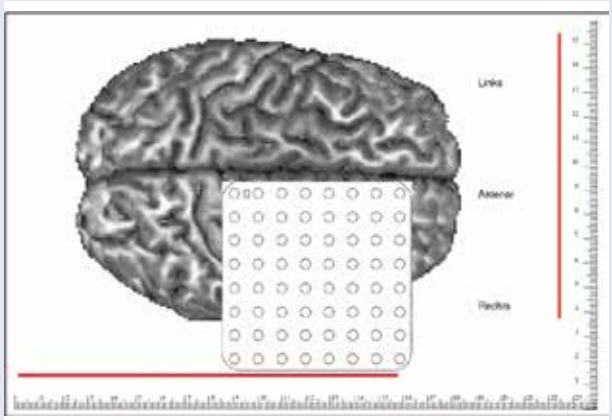

Figure 5: Planning of electrode implantation using an image of the individual patient's brain surface together with 2-dimensional electrode images of corresponding size in a common coordinate system, but still disregarding the convexity of the brain (figure by courtesy of Dr. Peter Hilfiker, Swiss Epilepsy Centre).

sponding size in a common coordinate system (**Figure 5**).

However, this approach still does not take into account the convexity of the brain, and does not indicate whether the electrode grid is large enough for the cerebral area to be mapped – or perhaps too large. An alternative method overcomes these drawbacks and calculates the geometry of the electrode three-dimensionally and in correct spatial relation to the curvature of the individual brain surface [54]. The position of the first electrode contact is manually chosen on the brain surface, and a second point is marked to indicate the direction of the strip electrode or the first row of a grid electrode. Then, an in-house-developed program automatically calculates the positions of the other electrode contacts in between and makes them follow the curvature of the brain surface. This is also possible for grid electrodes. In a mathematical sense the electrode contacts are treated like marbles that are forced to keep contact to each other and to maintain the grid structure but are free to rotate around each other and to bend to the convexity of the brain. After this calculation, the electrode positions are available as separate objects. They can be projected into another data set, for example the original image with the skull still in place. This helps the surgeon to plan the correct approach for craniotomy, i.e. the optimal area for trepanation of the skull. In conclusion, this method allows a rapid and exact determination of optimal electrode positions on the individual patient's brain surface and supports planning and execution of subdural electrode implantation. In our example patient it helped to position a subdural grid of 8x8 electrode contacts over the right frontal and central area (**Figure 6**).

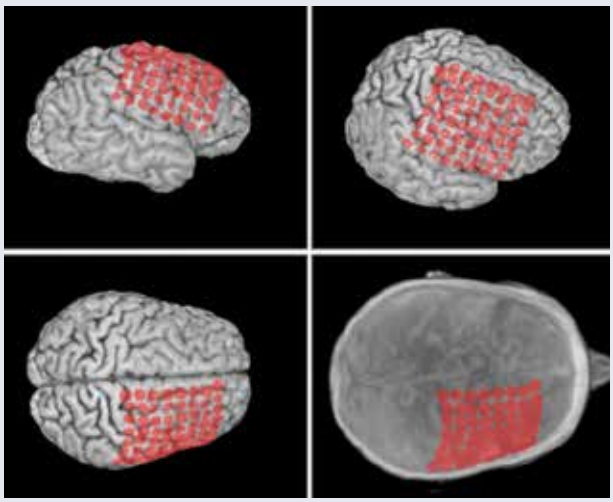

Figure 6: Planning of electrode implantation by calculating the geometry of the electrode grid three-dimensionally and in correct spatial relation to the curvature of the individual brain surface. The electrode positions can also be projected into other MRI data sets, for example with the skull still in place (cf. lower right subfigure). This is helpful for planning the correct approach for craniotomy, i.e. the optimal area for trepanation of the skull.

Localization of Subdural Electrodes

After implantation of subdural electrodes it is important to localize the real position of electrodes and to confirm congruence with prior planning. For correct interpretation of invasive EEG data and mapping results, it is crucial to be sure about the location of each electrode contact. Planar MR sections often pose problems with regard to electrode localization due the convexity of the cortical surface. The alternative approach, i.e. 3-dimensional rendering of the cortical surface, requires computational removal of the skull in the MRI data. Normally, one would expect that simply removing the skull by help of a brain extraction program (e.g., BET = brain extraction tool from the FMRIB Software Library) renders the underlying electrodes visible. Unfortunately, this form of skull-stripping not only removes the bone but also the signal extinction artefacts by help of which the electrodes become visible. Therefore, a trick is needed: the combined use of a pre-implantation and a post-implantation image. Both data sets (usually 3D T1-weighted images) are coregistered. In the data set acquired before implantation, the skull is removed using the aforementioned ‚brain extraction tool' [55]. The resulting "skull-stripped" image is used as a mask to also remove the skull (but only the skull) in the second MRI acquired after implantation. This leaves the signal extinction of the electrode contacts in place. By volume rendering, the extracted brain can then be presented 3-dimensionally with the electrodes directly visible because of their signal extinction artefacts.

Compared to planar MRI slices, this offers a markedly superior visualization of topographic relations between subdural electrodes and cortical structures. In addition, the possibility of different view angles facilitates the planning of operations. We can also visualize the lesion and its spatial relation to the electrodes, and we can even show electrodes at the basal surface of the brain, between cerebrum and cerebellum [56, 57]. **Figure 7** displays the results of electrode localization in our example patient.

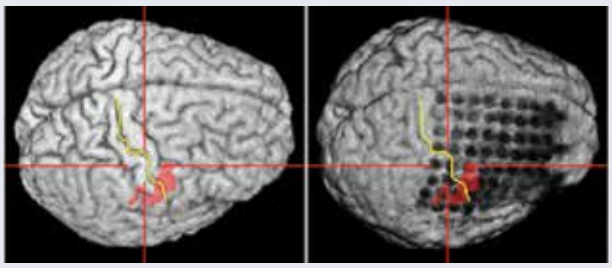

Figure 7: Localization of implanted electrodes: Three-dimensional rendering of the cortical surface gives an overview of the whole brain with and without the implanted subdural electrode grid and confirms that the grid position is congruent with prior planning. The central sulcus (yellow line) has been manually traced in the pre-implantation MRI (left side) and projected into the post-implantation image (right side). In addition, the suspected lesion as delineated in the junction image has been projected into both images. Compared to conventional planar MR slices, it is now much easier to determine which electrode contacts are immediately in the vicinity of the lesion or which are located over the central sulcus or the motor cortex.

Invasive Diagnostics, Epilepsy Surgery and Histological Results

Invasive EEG monitoring confirmed the onset of habitual seizures over and in the surroundings of the suspected dysplastic lesion. As already expected from the lesion's location in the central region, mapping of motor functions showed a partial overlap of the seizure onset zone with motor areas. However, this overlap was limited to regions responsible for tongue movement. Due to their bilateral representation, these motor functions are usually not at risk in case of unilateral resection. Finally, therefore, epilepsy surgery in our example patient aimed at complete removal of the seizure onset zone around the lesion. In the resected specimen, focal cortical dysplasia type II according to Palmini and Lüders was histologically confirmed [58].

Validation of Postoperative Results

After epilepsy surgery it is important to validate the post-operative results and to examine whether the epileptogenic lesion has been completely removed. As stated above, the completeness of lesion resection has a decisive influence on the post-operative outcome [38]. Pure visual analysis of MR images may not be sufficient to detect residual lesional tissue. The examination is greatly enhanced if pre- and post-operative MRI data are coregistered and inspected together in the same coordinate space. If the lesion is only hardly recognizable on conventional MR images, it can be advantageous to coregister also the results of morphometric analysis presented above. In patients who fail to become seizure-free after surgery the proof of residual dysplastic/lesional tissue might offer the chance to achieve complete lesion resection in a second operation [59].

In our example patient coregistration of pre- and post-operative MRI data confirmed that the lesion had been completely removed. Since then, the patient has remained seizure-free and meanwhile has also tapered off the antiepileptic medication (**Figure 8**).

Conclusion

Postprocessing of structural MRI data has increasingly found entrance into routine clinical diagnostics and especially into the presurgical evaluation of epilepsy patients. In cases of medically refractory epilepsy it helps to determine the underlying pathology and to identify candidates for epilepsy surgery with a correspondingly higher chance of seizure freedom and improved quality of life for these patients. However, postprocessing MRI data does not only serve to capture epileptogenic lesions that are difficult to discern by eye, but can be useful at various stages during the course of presurgical evaluations and epilepsy surgery. Overall, computer-assisted MRI postprocessing complements conventional visual analysis and helps to manage and work up the increasing load of MRI data in epileptology (**Figure 9**).

References

1. *Berg AT, Vickrey BG, Langfitt JT et al. The multicenter study of epilepsy surgery: recruitment and selection for surgery. Epilepsia 2003; 44: 1425-1433*
2. *Bien CG, Szinay M, Wagner J et al. Characteristics and surgical outcomes of patients with refractory magnetic resonance imaging-negative epilepsies. Arch Neurol 2009; 66: 1491-1499*
3. *Bastos AC, Comeau RM, Andermann F et al. Diagnosis of subtle focal dysplastic lesions: curvilinear reformatting from three-dimensional magnetic resonance imaging. Ann Neurol 1999; 46: 88-94*
4. *Sisodiya SM, Free SL, Stevens JM et al. Widespread cerebral structural*

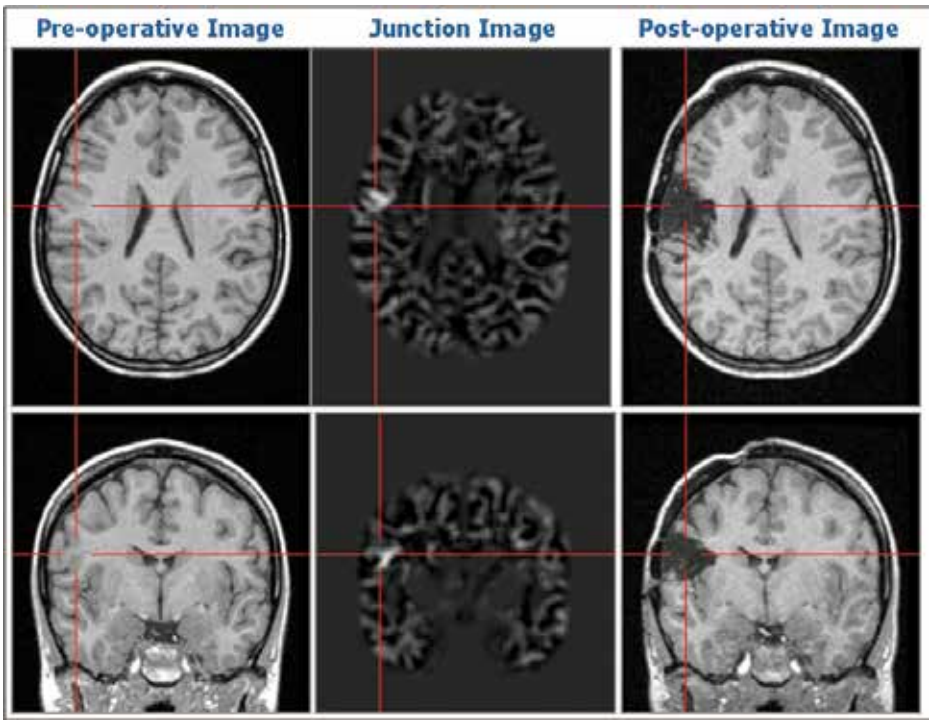

Figure 8: Validation of post-operative results: The coregistration of the pre-operative MRI data (left subfigure) and the results of morphometric analysis (i.e. junction image in the middle subfigure) with the post-operative MR image (right subfigure) helps to confirm that no residual dysplastic tissue has been left in situ.

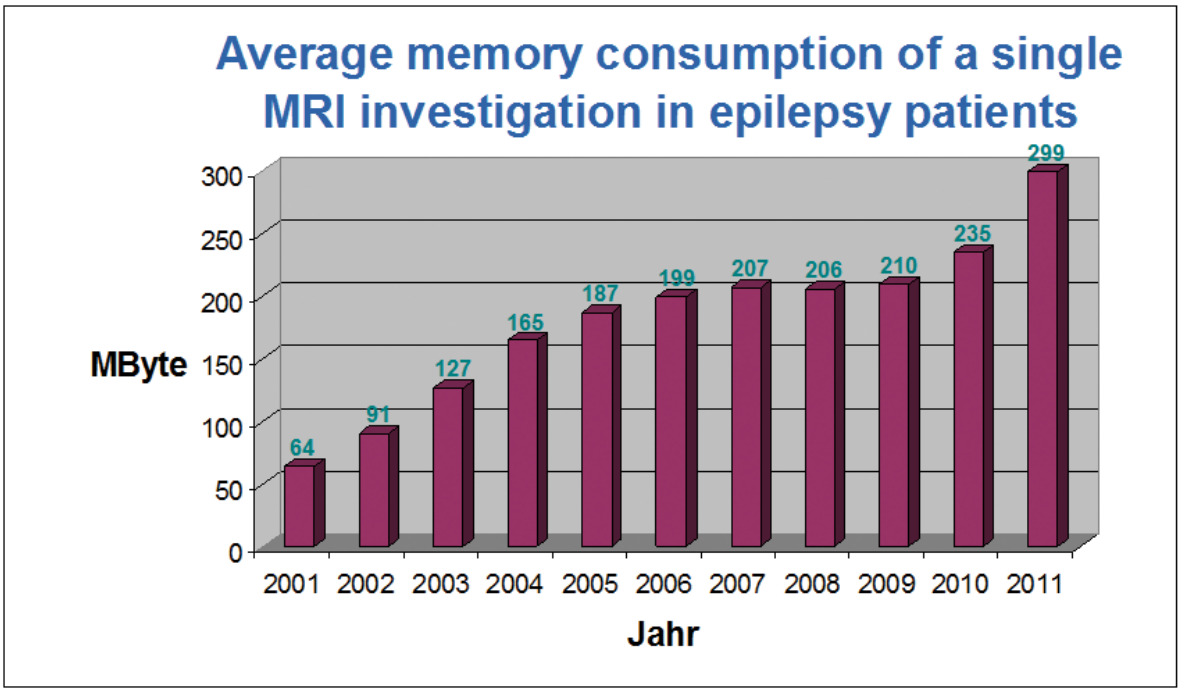

Figure 9: Progress of the average memory consumption of a single MRI measurement in epilepsy patients (data from the Swiss Epilepsy Centre in Zurich).

changes in patients with cortical dysgenesis and epilepsy. Brain 1995; 118: 1039-1050

5. *Bonilha L, Montenegro MA, Rorden C et al. Voxel-based morphometry reveals excess gray matter concentration in patients with focal cortical dysplasia. Epilepsia 2006; 47: 908-915*
6. *Bruggemann JM, Wilke M, Som SS et al. Voxel-based morphometry in the detection of dysplasia and neoplasia in childhood epilepsy: combined grey/white matter analysis augments detection. Epilepsy Res 2007; 77: 93-101*
7. *Merschhemke M, Mitchell TN, Free SL et al. Quantitative MRI detects abnormalities in relatives of patients with epilepsy and malformations of cortical development. Neuroimage 2003; 18: 642-649*
8. *Woermann FG, Free SL, Koepp MJ et al. Voxel-by-voxel comparison of automatically segmented cerebral gray matter – A rater-independent comparison of structural MRI in patients with epilepsy. Neuroimage 1999; 10: 373-384*
9. *Sisodiya SM, Free SL, Fish DR, Shorvon SD. Increasing the yield from volumetric MRI in patients with epilepsy. Magn Reson Imaging 1995; 13: 1147-1152*
10. *Fischl B, Dale AM. Measuring the thickness of the human cerebral cortex from magnetic resonance images. Proc Natl Acad Sci U S A 2000; 97: 11050-11055*
11. *Antel SB, Bernasconi A, Bernasconi N et al. Computational models of MRI characteristics of focal cortical dysplasia improve lesion detection. Neuroimage 2002; 17: 1755-1760*
12. *Antel SB, Collins DL, Bernasconi N et al. Automated detection of focal cortical dysplasia lesions using computational models of their MRI characteristics and texture analysis. Neuroimage 2003; 19: 1748-1759*
13. *Bernasconi A, Antel SB, Collins DL et al. Texture analysis and morphological processing of magnetic resonance imaging assist detection of focal cortical dysplasia in extra-temporal partial epilepsy. Ann Neurol 2001; 49: 770-775*
14. *Rugg-Gunn FJ, Boulby PA, Symms MR et al. Whole-brain T2 mapping demonstrates occult abnormalities in focal epilepsy. Neurology 2005; 64: 318-325*
15. *Salmenpera TM, Symms MR, Rugg-Gunn FJ et al. Evaluation of quantitative magnetic resonance imaging contrasts in MRI-negative refractory focal epilepsy. Epilepsia 2007; 48: 229-237*
16. *Focke NK, Symms MR, Burdett JL, Duncan JS. Voxel-based analysis of whole brain FLAIR at 3T detects focal cortical dysplasia. Epilepsia 2008; 49: 786-793*
17. *Wilke M, Kassubek J, Ziyeh S et al. Automated detection of gray matter malformations using optimized voxel-based morphometry: a systematic approach. Neuroimage 2003; 20: 330-343*
18. *Kassubek J, Huppertz HJ, Spreer J, Schulze-Bonhage A. Detection and localization of focal cortical dysplasia by voxel-based 3-D MRI analysis. Epilepsia 2002; 43: 596-602*
19. *Colliot O, Bernasconi N, Khalili N et al. Individual voxel-based analysis of gray matter in focal cortical dysplasia. Neuroimage 2006; 29: 162-171*
20. *Besson P, Bernasconi N, Colliot O et al. Surface-based texture and morphological analysis detects subtle cortical dysplasia. Med Image Comput Comput Assist Interv 2008; 11: 645-652*
21. *Bernasconi A, Bernasconi N, Bernhardt BC, Schrader D. Advances in MRI for „cryptogenic" epilepsies. Nat Rev Neurol 2011; 7: 99-108*
22. *Kurthen M, Grunwald T, Huppertz HJ. Präoperative Diagnostik und chirurgische Therapie von Epilepsien. Schweiz Med Forum 2008; 8: 836-843*
23. *Serles W, Baumgartner C, Feichtinger M et al. Richtlinien für ein standardisiertes MRT-Protokoll für Patienten mit epileptischen Anfällen in Österreich. Mitteilungen der Österreichischen Sektion der Internationalen Liga gegen Epilepsie 2003; 3: 2-13*
24. *House P, Lanz M, Holst B et al. Comparison of morphometric analysis based on T1- and T2-weighted MRI data for visualization of focal cortical dysplasia. Abstract at the „Gemeinsame Jahrestagung der Deutschen und Österreichischen Gesellschaft für Epileptologie und der Schweizerischen Liga gegen Epilepsie", 08 -11 Mai 2013, Interlaken, Schweiz. Sonderheft Epileptologie Dreiländertagung 2013: 18*
25. *Ashburner J, Friston KJ. Voxel-based morphometry – The methods. Neuroimage 2000; 11: 805-821*
26. *Bast T, Huppertz HJ, Bilic S et al. Iktale Magnetoenzephalographie (MEG) und modernste multimodale Diagnostik führen zur Operationsindikation nach 40 Jahren pharmakorefraktärem Verlauf einer scheinbar kryptogenen Frontallappenepilepsie. Z Epileptol 2007; 20: 41-48*
27. *Kröll-Seger J, Grunwald T, Mothersill IW et al. Lachen ohne Heiterkeit – Morphometrische MRT-Analyse in der prächirurgischen Abklärung einer MRT-negativen kindlichen Epilepsie mit gelastischen Anfällen. Epileptologie 2011; 28: 78-83*
28. *Wang ZI, Jones SE, Ristic AJ et al. Voxel-based morphometric MRI postprocessing in MRI-negative focal cortical dysplasia followed by simultaneously recorded MEG and stereo-EEG. Epilepsy Res 2012; 100: 188-193*
29. *Huppertz HJ, Kurthen M, Kassubek J. Voxel-based 3D MRI analysis for the detection of epileptogenic lesions at single subject level. Epilepsia 2009; 50: 155-156*
30. *Huppertz HJ, Grimm C, Fauser S et al. Enhanced visualization of blurred gray-white matter junctions in focal cortical dysplasia by voxel-based 3D MRI analysis. Epilepsy Res 2005; 67: 35-50*
31. *Wagner J, Weber B, Urbach H et al. Morphometric MRI analysis improves detection of focal cortical dysplasia type II. Brain 2011; 134: 2844-2854*
32. *Wellmer J, Parpaley Y, von Lehe LM, Huppertz HJ. Integrating magnetic resonance imaging postprocessing results into neuronavigation for electrode implantation and resection of subtle focal cortical dysplasia in previously cryptogenic epilepsy. Neurosurgery 2010; 66: 187-194*
33. *Altenmüller DM, Huppertz HJ. Kombinierter Einsatz von morphometrischer MRT-Analyse und gezielter invasiver EEG-Diagnostik bei fokaler kortikaler Dysplasie. Epileptologie 2006; 3: 117-125*
34. *Huppertz HJ, Wellmer J, Staack AM et al. Voxel-based 3D MRI analysis helps to detect subtle forms of subcortical band heterotopia. Epilepsia 2008; 49: 772-785*
35. *Pascher B, Kröll J, Mothersill I et al. Automated morphometric magnetic resonance imaging analysis for the detection of periventricular nodular heterotopia. Epilepsia 2013; 54: 305-313*
36. *Lerner JT, Salamon N, Hauptman JS et al. Assessment and surgical outcomes for mild type I and severe type II cortical dysplasia: a critical review and the UCLA experience. Epilepsia 2009; 50: 1310-1335*
37. *Fauser S, Schulze-Bonhage A, Honegger J et al. Focal cortical dysplasias: surgical outcome in 67 patients in relation to histological subtypes and dual pathology. Brain 2004; 127: 2406-2418*
38. *Krsek P, Maton B, Jayakar P et al. Incomplete resection of focal cortical dysplasia is the main predictor of poor postsurgical outcome. Neurology 2009; 72: 217-223*
39. *Focke NK, Bonelli SB, Yogarajah M et al. Automated normalized FLAIR imaging in MRI-negative patients with refractory focal epilepsy. Epilepsia 2009; 50: 1484-1490*
40. *Woermann FG, Barker GJ, Birnie KD et al. Regional changes in hippocampal T2 relaxation and volume: a quantitative magnetic resonance imaging study of hippocampal sclerosis. J Neurol Neurosurg Psychiatry 1998; 65: 656-664*

41. Briellmann RS, Jackson GD, Pell GS et al. Structural abnormalities remote from the seizure focus: a study using T2 relaxometry at 3 T. Neurology 2004; 63: 2303-2308
42. von Oertzen J, Urbach H, Blümcke I et al. Time-efficient T2 relaxometry of the entire hippocampus is feasible in temporal lobe epilepsy. Neurology 2002; 58: 257-264
43. Huppertz HJ, Wagner J, Weber B et al. Automated quantitative FLAIR analysis in hippocampal sclerosis. Epilepsy Res 2011; 97: 146-156
44. Schulze-Bonhage AH, Huppertz HJ, Comeau RM et al. Visualization of subdural strip and grid electrodes using curvilinear reformatting of 3D MR imaging data sets. AJNR Am J Neuroradiol 2002; 23: 400-403
45. Palma T, Cravo I, Conceicao C et al. Three-dimensional magnetic resonance reconstruction. Significance of neurosurgical planning. Acta Med Port 2001; 14: 27-31
46. Lee U, Bastos AC, Alonso-Vanegas MA et al. Topographic analysis of the gyral patterns of the central area. Stereotact Funct Neurosurg 1998; 70: 38-51
47. Montenegro MA, Li LM, Guerreiro MM et al. Focal cortical dysplasia: improving diagnosis and localization with magnetic resonance imaging multiplanar and curvilinear reconstruction. J Neuroimaging 2002; 12: 224-230
48. Musse O, Armspach JP, Namer IJ et al. Data-driven curvilinear reconstructions of 3D MR images: application to cryptogenic extratemporal epilepsy. Magn Reson Imaging 1998; 16: 1227-1235
49. Meiners LC, Scheffers JM, De Kort GA et al. Curved reconstructions versus three-dimensional surface rendering in the demonstration of cortical lesions in patients with extratemporal epilepsy. Invest Radiol 2001; 36: 225-233
50. Hattingen E, Hattingen J, Clusmann H et al. Planar brain surface reformations for localization of cortical brain lesions. Zentralbl Neurochir 2004; 65: 75-80
51. Hattingen E, Good C, Weidauer S et al. Brain surface reformatted images for fast and easy localization of perirolandic lesions. J Neurosurg 2005; 102: 302-310
52. Araujo D, Machado HR, Oliveira RS et al. Brain surface reformatted imaging (BSRI) in surgical planning for resections around eloquent cortex. Childs Nerv Syst 2006; 22: 1122-1126
53. Huppertz HJ, Kassubek J, Altenmuller DM et al. Automatic curvilinear reformatting of three-dimensional MRI data of the cerebral cortex. Neuroimage 2008; 39: 80-86
54. Kröll-Seger J, Grunwald T, Bernays R et al. Pre-operative planning of subdural electrode implantation for invasive EEG recordings by means of realistic 3D representation of electrode contacts on the individual brain surface. Gemeinsame Jahrestagung der Deutschen, Österreichischen und Schweizerischen Sektion der Internationalen Liga gegen Epilepsie, Rostock, 20-23.05.2009, Programm- und Abstractheft V48: 73
55. Smith SM. Fast robust automated brain extraction. Hum Brain Mapp 2002; 17: 143-155
56. Huppertz HJ, Kovalev D, Spreer J et al. Visualization of subdural EEG electrodes using volume rendering of 3D MRI. Epilepsia 2004; 45(Suppl): 179-180
57. Kovalev D, Spreer J, Honegger J et al. Rapid and fully automated visualization of subdural electrodes in the presurgical evaluation of epilepsy patients. AJNR Am J Neuroradiol 2005; 26: 1078-1083
58. Palmini A, Luders HO. Classification issues in malformations caused by abnormalities of cortical development. Neurosurg Clin N Am 2002; 13: 1-16, vii
59. Kröll J, Huppertz HJ. Nachweis von postoperativ verbliebenem dysplastischen Kortex mittels morphometrischer MRI-Analyse. Schweizer Zeitschrift für Psychiatrie & Neurologie 2008; 2: 17-20

Address for correspondence:
Prof. Dr. med. Hans-Jürgen Huppertz
Schweizerisches Epilepsie-Zentrum
Bleulerstrasse 60
CH 8008 Zürich
Tel. 0041 44 387 6316
Fax 0041 44 387 6397
Hans-Juergen.Huppertz@swissepi.ch

Clinical Application of Language and Memory fMRI in Epilepsy

Anja Haag[1] and Silvia Bonelli[2]
[1]Chalfont Epilepsy Centre, MRI Unit & Department of Clinical and Experimental Epilepsy, University College London, UK
[2]Universitätsklinik für Neurologie, Medizinische Universität Wien, Österreich

Summary

Epilepsy syndromes are frequently accompanied by cognitive deficits. Temporal lobe epilepsy as well as resective surgery on the temporal lobe may affect cognitive function, in particular verbal and visual memory, but also working memory and naming ability. Epilepsy surgery offers an effective and safe treatment option for patients with medically refractory seizures rendering 60-70% of them seizure free. The goals of epilepsy surgery are to remove the brain areas generating the seizures without causing neuropsychological deficits such as language or memory dysfunction. This requires accurate localization of the brain areas generating the seizures ("epileptogenic zone"), as well as areas responsible for motor and cognitive functions, such as language and memory ("essential brain regions") during presurgical evaluation.

Functional magnetic resonance imaging (fMRI) is a useful tool to localize primary motor and somatosensory areas and to lateralize language and memory function; it also shows promise for predicting the effects of temporal lobe resection on memory and language function.

Functional MRI can be integrated with other MR imaging modalities to improve surgical strategies tailored to individual patients with regard to functional outcome, by virtue of definition of epileptic cerebral areas that need to be resected and eloquent areas that need to be spared.

Epileptologie 2013; 30: 101 – 121

Key words: Epilepsy surgery, functional imaging, language, episodic memory, lateralization, hemispheric dominance, localization, anterior temporal lobe resection

Applications cliniques de l'IRMf du langage et de la mémoire chez les patients avec épilepsie

Les syndromes épileptiques sont fréquemment accompagnés par des déficits cognitifs. L'épilepsie du lobe temporale et, davantage, les résections chirurgicales touchant le lobe temporal peuvent altérer les fonctions cognitives, particulièrement la mémoire verbale et visuelle mais également la mémoire de travail et les capacités de dénomination. La chirurgie de l'épilepsie offre un traitement efficace et sûr pour les patients avec des crises pharmacorésistantes et rend 60-70% des patients libres de crise. Les buts de la chirurgie de l'épilepsie sont la résection des régions cérébrales qui génèrent les crises sans causer de déficits neuropsychologiques langagiers ou mnésiques notamment. Ceci nécessite une localisation précise des régions cérébrales qui génèrent les crises (« zone épileptogène ») ainsi que des régions responsables des fonctions motrices et cognitives (langage, mémoire: « régions cérébrales essentielles » durant l'évaluation préchirurgicale.

L'imagerie fonctionnelle par résonance magnétique (IRMf) est un outil utile pour localiser les régions motrices et somatosensorielles primaires et pour latéraliser les fonctions mnésiques et langagières. Cette technique est aussi prometteuse pour prédire les effects d'une résection temporale sur la mémoire et le langage.

L'IRMf peut être intégrée avec d'autres modalités d'imagerie IRM pour améliorer les stratégies chirurgicales individualisées en considérant le pronostic fonctionnel, en vertu de la définition des aires épileptiques cérébrales qui nécessitent d'être réséquées et des régions éloquantes qui doivent être épargnées.

Mots clés : Chirurgie de l'épilepsie, imagerie fonctionnelle, langage, mémoire épisodique, dominance hémisphérique, localisation, lobectomie temporale antérieure

Funktionelle MRT von Sprache und Gedächtnis in der Epilepsiediagnostik

Patienten mit Temporallappenepilepsie zeigen häufig kognitive Beeinträchtigungen, insbesondere Störungen des verbalen und visuellen Gedächtnisses, des Arbeitsgedächtnisses sowie Benennstörungen. Diese können durch einen operativen Eingriff verstärkt werden. Epilepsiechirurgie ist eine effektive und sichere Behan-

dlungsmöglichkeit für Patienten mit medikamentös therapierefraktären Anfällen. Bei 60-70% dieser Epilepsiepatienten kann durch einen neurochirurgischen Eingriff Anfallsfreiheit erreicht werden. Ziel eines solchen epilepsiechirurgischen Eingriffes ist es, die epileptogene Zone zu entfernen, ohne postoperative, insbesondere neuropsychologische Defizite, wie zum Beispiel Sprach- oder Gedächtnisstörungen, zu verursachen.

Dementsprechend ist es notwendig, im Rahmen eines sorgfältigen, präoperativen Monitorings sowohl die Areale des Gehirns, von welchen die Anfälle ausgehen („epileptogene Zone"), als auch die Areale, die für motorische, Sprach- und Gedächtnisfunktionen verantwortlich sind („essenzielle Hirnareale") sorgfältig zu lokalisieren.

Grosse Fortschritte im Bereich der bildgebenden Verfahren haben die Epilepsiechirurgie in den letzten Jahren revolutioniert. Die funktionelle Magnetresonanztomographie (fMRT) wird zusehends zur Lokalisation des primären motorischen, des somatosensorischen Kortex sowie zur Lateralisation und Lokalisation von Sprach- und Gedächtnisfunktionen eingesetzt. Rezente Studien sind vielversprechend, dass die fMRT dazu beitragen kann, das individuelle Risiko für postoperative Sprach- und Gedächtnisdefizite näher bestimmen zu können.

Zusammen mit anderen strukturellen und funktionellen bildgebenden Verfahren kann die fMRT entscheidend zu einer weiteren Verbesserung des postoperativen Outcomes nach epilepsiechirurgischen Eingriffen beitragen, indem die epileptogene Zone, die entfernt werden muss, und der eloquente Kortex, der erhalten bleiben soll, besser definiert werden können.

Schlüsselwörter: Epilepsiechirurgie, funktionelle Bildgebung, Sprache, episodisches Gedächtnis, Lateralisation, Hemisphärendominanz, Lokalisation, anteriore Temporallappenresektion

Acknowledgements:
Anja Haag has received funding of a 1year Research-Fellowship by the Deutsche Forschungsgemeinschaft, DFG

Abbreviations

AED	= antiepileptic drugs
ATLR	= anterior temporal lobe resection
BOLD	= blood oxygen level dependent
DTI	= diffusion tensor imaging
EPI	= echo planar imaging
ESM	= electro-cortical stimulation mapping
fMRI	= functional magnet resonance imaging
HC	= hippocampus
IAP	= intracarotid amobarbital procedure
IFG	= inferior frontal gyrus
MFG	= middle frontal gyrus
MTL	= medial temporal lobe
SFG	= superior frontal gyrus
SMG	= supramarginal gyrus
STG	= superior temporal gyrus
TLE	= temporal lobe epilepsy
VBM	= voxel-based morphometry

Interessenkonflikt: Die Autoren geben an, dass keine Interessenkonflikte bestehen.

Background

Seizure freedom is the major aim of epilepsy treatment. Cognitive impairment is a frequent comorbidity in focal epilepsies and has a major impact on quality of life. Cognitive deficits can either result from the underlying disease as a consequence of seizures or interictal epileptic activity, or can be caused by adverse effects of antiepileptic drugs (AED) [1].

In temporal lobe epilepsy (TLE), particularly memory impairment and naming difficulties have been reported [2, 3]. These can already be observed in some patients with a recent onset of epilepsy [4], which supports the hypothesis that cognitive problems cannot fully be explained by adverse effects of medication. Patients who are refractory to AED treatment are at higher risk of suffering from cognitive impairment.

In patients with medically refractory TLE anterior temporal lobe resection (ATLR) is an effective and safe treatment option, leading to seizure freedom in up to 60-70% of these patients [5, 6]. Prior to surgery, comprehensive pre-surgical assessment is conducted which aims at identifying the epileptic brain tissue that has to be removed for the patient to become seizure free [7]. At the same time neuropsychological deficits such as language and memory impairment have to be avoided.

In recent years, epilepsy surgery is carried out earlier in the course of the disease, and the potential benefits must be carefully weighed against the potential risks of decline. For this, eloquent brain areas have to be identified which must be spared from the resection. Functional MRI (fMRI) has proven a valid and reliable tool to investigate cognitive functions non-invasively during pre-surgical assessment. Over recent years it has increasingly replaced invasive procedures such as the WADA-test as it is cheaper, non-invasive and repeatable. Compared to baseline neuropsychological assessment it further has the potential of providing additional information regarding lateralisation and localisation of language and memory function and particularly allows evaluation of functional reorganisation processes.

ATLR carries the risk of language and memory decline, e.g. verbal memory and naming decline after surgery within the language-dominant, usually left hemisphere [2]. Language fMRI is well established in many centres and is often applied to identify the language dominant hemisphere on an individual level. However, the localisation of language areas is much more

complicated and still requires invasive electro-cortical stimulation mapping (ESM). Regarding memory function, recent studies were promising that memory fMRI has a great potential to predict postoperative memory decline after surgery even in individual patients, which is one of the ultimate goals of clinical neuroimaging.

Methodological Considerations

As discussed above invasive methods have been routinely used to identify the eloquent cortex in the past: the Wada-Test (intracarotid amobarbital procedure, IAP) was widely used to *lateralise* function, and ESM is still the gold standard to *localise* eloquent cortex. Over the last decades, non-invasive methods, predominantly fMRI have been established for this purpose [8, 9]. Obvious advantages of non-invasive methods are their low risks and less strain for the patient. They can be applied in healthy volunteers for research purposes allowing systematic comparison of different study groups.

Functional MRI, like most other non-invasive imaging tools, is an activation based method. The rationale behind this is that if a certain cognitive function is used, relevant brain areas will be activated. Blood flow will increase in these areas to compensate for the higher demand of oxygen. In fMRI, this is displayed by the BOLD (blood-oxygen-level-dependent) contrast which represents the regional changes in blood flow over time. To be able to get a reasonable temporal resolution echo planar imaging (EPI), a fast MRI sequence, is used. Functional MRI has a high spatial resolution which, in principal, allows very good localisation of areas in the brain that are involved in certain tasks. However, which areas will be activated depends on the fMRI paradigm.

It is important to assure sufficient task performance as only then activation can be accurately interpreted in relation to function. This needs to be considered in fMRI paradigm design, especially when applying fMRI to patient groups in which cognitive performance can vary considerably. It is mandatory to make sure that participants understand and follow task instructions. However, during fMRI the subject's performance cannot easily be assessed. The majority of fMRI paradigms applied to date use covert tasks (e.g. thinking of words, but not speaking out loud) or assess performance with a joy-stick or button press response. This can restrict the variety of possible responses that can be used in an fMRI paradigm. More recently developed devices such as MRI-compatible microphones can now be used to monitor speech during fMRI. For simple paradigms which only require basic analysis, e.g. as used for clinical language fMRI, scanner implemented software for online data analysis can be employed to show activation patterns during the scan.

In epilepsy, seizures and interictal epileptic activity as well as AEDs may alter fMRI results [10].

Most cognitive tasks do not only rely on one particular function. If visual stimuli are presented, activation of visual cortex can be expected. If the subject is asked for a motor response, motor activation can be expected. To differentiate between activation related to a certain function and other activation, neuroanatomical information (e.g. Broca's area, Wernicke's area for language; medial temporal lobe structures for memory) may be used to interpret results. Further, most fMRI paradigms include other tasks with the aim to control for irrelevant activations; only activation in the "real" task that exceeds activations during the control task is considered.

What brain areas will be displayed as "active" varies substantially with different statistical thresholds which can be applied to the data. A high threshold reduces the sensitivity in detecting activations as well as the extent of activation clusters while a low threshold increases the risk of false-positive activations.

In summary caution is needed in the interpretation of the results. Firstly, areas activated by a particular fMRI paradigm are not necessarily essential for performing a task. Secondly, not necessarily all areas involved in a task will be activated by one particular fMRI paradigm and finally extent and magnitude of activation seen in a task does not necessarily relate to the competence with which the task is performed. One must also bear in mind the limitation of fMRI techniques especially in the temporal lobes, such as lower MRI signal to noise ratio due to susceptibility artefacts and signal loss in areas that are close to larger blood vessels and bone tissue.

Language

During evaluation for epilepsy surgery, fMRI is the most frequently applied non-invasive method for language imaging [9]. Clinically applied paradigms focus on the classic language areas such as Broca's area (IFG) and Wernicke's area (SMG, STG). Covert lexical word generation (i.e. thinking of words starting with a given letter) is an expressive language task that reliably activates the IFG (**Figure 1**). Posterior temporal lobe (TL) activation (SMG, STG) can be achieved by more receptive tasks, e.g. semantic decision tasks (i.e. which word does not match the others: shirt, gloves, shoes, rose?) or story listening tasks. Numerous language paradigms have been applied in group studies which may partly explain some differences in the results between studies [9, 11]. Studies comparing language fMRI with the classic invasive methods (Wada-Test, ESM) showed that fMRI is a valid method for identifying the language dominant hemisphere [11 - 13]. Functional MRI seems more likely to elicit bilateral language representation compared to the Wada-Test; however, the meaning of this finding for language function after surgery is not fully understood [13]. Accurate localisation of language areas with fMRI is not yet established. First of all, test-retest series have shown that the localisation of areas that were

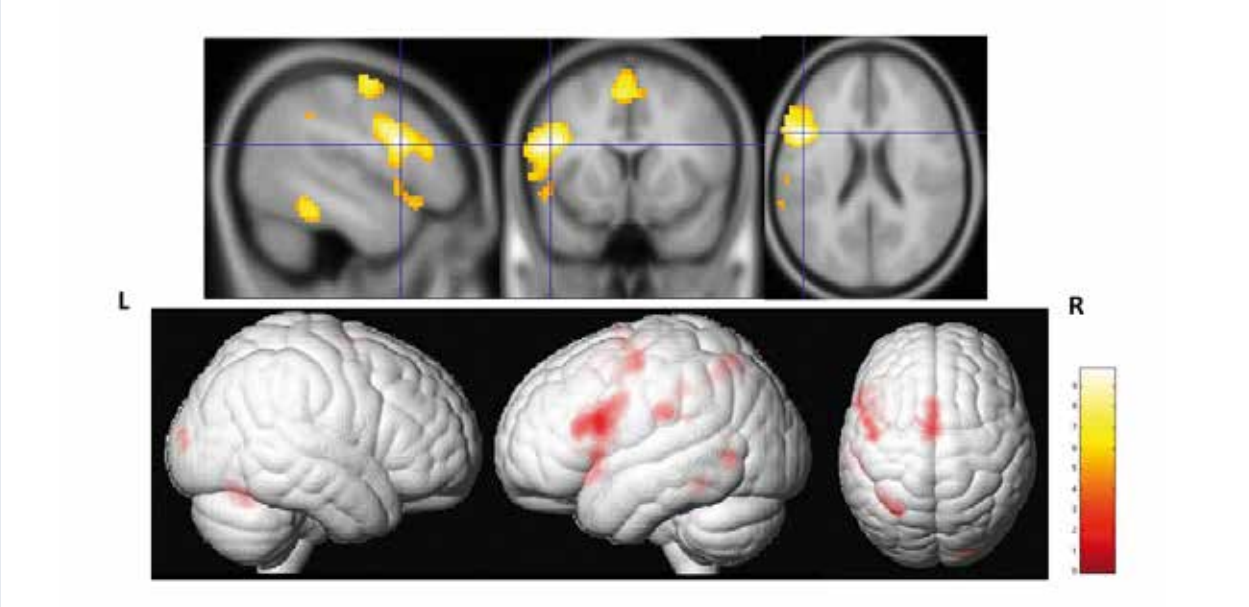

Figure 1: Language fMRI activations during covert lexical fluency in a single subject at p = .05, family wise error; strong activation can be seen in the left IFG, as well as in the left MFG and SFG.

activated during a specific language fMRI task was less reliable than lateralisation [14]. Furthermore, ESM studies showed only imperfect overlap with activation clusters of fMRI: in some cases electric stimulation of fMRI activated brain areas did not result in language disturbances [15], while in others crucial areas were not displayed during fMRI [16]. The differences may be related either to the applied language paradigms or the statistical thresholds. To date, language fMRI localisation is not suitable for resection decision [17] but may be helpful in planning electrode placement for ESM [8].

Aphasia is rare after temporal lobe surgery. More subtle language decline such as word finding difficulties have been reported in up to 50% of patients after ATLR of the language dominant hemisphere. In left TLE, a predictive value of fMRI language lateralisation for naming decline [18] as well as for verbal memory [19, 20] could be shown. However, prediction models on an individual level are not yet sufficient to be applied in clinical routine. Future studies will need to investigate whether specific naming paradigms will allow more accurate prediction in individual patients. Apart from presurgical evaluation, language fMRI has also be applied in other epilepsy syndromes. As an example, in primary reading epilepsy, a study combining EEG and fMRI showed specific regions that were involved in seizure generation during reading [21]. Brain activation patterns can be assessed repeatedly during language development in certain epilepsies which may provide prognostic information of potential language achievement in relation to seizures and help finding new rehabilitation strategies [21, 22].

Memory

The occurrence of material specific (verbal and visual) memory impairment after ATLR indicates major relevance of these areas for successful memory function. Intracranial electrophysiological recordings during verbal encoding tasks have shown greater responses in anterior hippocampal and parahippocampal regions for words remembered than those forgotten [23]. At first, these results could not be replicated with functional imaging studies, with many showing encoding related activations in posterior hippocampal and parahippocampal regions, which would be left intact following ATLRs. One possible explanation for this apparent conflict is that anterior temporal regions are subject to signal loss during fMRI sequences, which is most prominent in the inferior frontal and inferior lateral temporal regions [24]. The anatomical position of the hippocampus which rises from anterior to posterior may explain greater susceptibility-induced signal loss in the anterior (inferior) relative to the posterior (superior) hippocampus which may have been one reason for the relative lack of anterior hippocampal activation in early fMRI studies of memory. Another reason for the lack of activation in the anterior medial temporal lobe (MTL) may be that most previous memory fMRI studies employed blocked experimental designs which have the advantage that they are generally most efficient in detecting differences between two conditions. However, the interpretation of their contrasts remains problematic assuming that the effects shown by these contrasts reflect differences in memory encoding, rather than any other differences between the two conditions. This approach does not account for subsequent memory effects (i.e. which stimuli were encoded successfully). More recent studies applied event-related de-

signs which have the big advantage that brain regions showing greater activation during encoding of different (material specific) items that were subsequently remembered compared to items that were subsequently forgotten can be identified, representing the neural correlates of memory encoding [25].

A previous study compared results from a blocked and event-related analysis of memory fMRI of words, pictures and faces: Only the event-related analysis of successfully encoded stimuli showed significant activations in the anterior MTL whereas simply viewing the different stimuli (using a blocked analysis without taking into account whether items were subsequently remembered or not) revealed predominant activation in the posterior hippocampus [26]. Therefore this study provided evidence for a functional dissociation between anterior and posterior hippocampal regions.

In summary, although event-related designs are less powerful than block designs at detecting differences in two different brain stages and also more vulnerable to alterations in the hemodynamic response function, they have the big advantage of permitting specifically the detection of subsequent memory effects due to successful encoding.

Lateralisation and Localisation of Memory Function

Patients with unilateral TLE often present with memory impairment which is specific to certain materials (e. g. verbal and visual). After temporal lobe surgery of the language dominant hemisphere more often verbal memory decline can be observed [27] while TL surgery in the non-dominant hemisphere is more likely to result in visual-spatial memory decline [28]. Many fMRI studies demonstrated material-specific lateralisation of memory function in prefrontal but also medial-temporal regions [26, 29, 30]. For clinical purposes, usually paradigms are applied that show bilateral MTL activation in healthy controls [31 - 33]. Previous fMRI studies in patients reported reduced activation in the TL ipsilateral to the seizure onset [29, 30, 34, 35]. These results were comparable with the Wada-Test [30]. As mentioned above, most of these studies employed block designs and showed more posterior HC activations. More recent studies using event-related analyses showed material-specific lateralisation of memory function in more anterior hippocampal regions during successful memory encoding [26] and therefore in an area which is most likely to be resected during standard ATLR. The reduced activation within the affected TL but increased contralateral MTL activation during memory fMRI has provided further evidence of reorganisation of memory function in TLE [31, 33, 35]. Still, it is a matter of debate if reorganisation towards the healthy hemisphere is effective, and whether it may be protective for memory decline after surgery. By correlation of fMRI activation and performance on standard neuropsychological memory tests it has been shown that higher MTL activation ipsilateral to the pathology was associated with better memory performance while contralateral, compensatory activation correlated with poorer performance [31, 33]. In one study that investigated patients with left and right TLE, higher MTL activation was observed in the healthy TL. However, better verbal memory was still related to left MTL activation [36]. This explains why good verbal memory is a risk factor for postoperative decline [37, 38].

Prediction of Memory Decline

Two different models of hippocampal function have been proposed to explain memory deficits following unilateral ATLR, the hippocampal reserve model and the functional adequacy theory [39]. According to the hippocampal reserve model, postoperative memory decline depends on the capacity or reserve of the contralateral hippocampus to support memory following surgery, while the functional adequacy model suggests that it is the capacity of the hippocampus that is to be resected that determines whether changes in memory function will be observed. Over the last years many studies focused on the identification of prognostic indicators for risk of memory loss after ATLR. The severity of hippocampal sclerosis (HS) on MRI turned out to be an important predictor, being inversely correlated with a decline in verbal memory following left ATLR, with less severe HS increasing the risk of memory decline [40]. Another recognised prognostic factor for memory decline after ATLR was preoperative performance on neuropsychological tests, with higher preoperative scores indicating a greater risk for postoperative decline [37, 38, 41 - 43]. Language lateralisation assessed by the IAP or more recently language fMRI has been found helpful to predict memory outcome [43 - 47]. These risk factors reflect the functional integrity of the resected temporal lobe and suggest that patients with residual memory function in the pathological hippocampus are at greater risk of memory impairment after ATLR. Other epilepsy related factors such as age of epilepsy onset and duration of epilepsy have also been identified as useful predictors of postoperative outcome [48].

Recently, memory fMRI has also been shown to be a potential predictor of postoperative memory decline after ATLR. Several studies have investigated the predictive value of fMRI for verbal memory decline [45, 49 - 51]. Only a few fMRI studies have investigated visual memory after ATLR [34, 47, 51]. In patients with left HS, greater verbal memory encoding activity in the left hippocampus prior to surgery predicted the extent of verbal memory decline following left ATLR [35, 49 - 51]. These findings have since been replicated and extended to patients undergoing right ATLR [31, 51]. Other groups employed asymmetry-indices to account

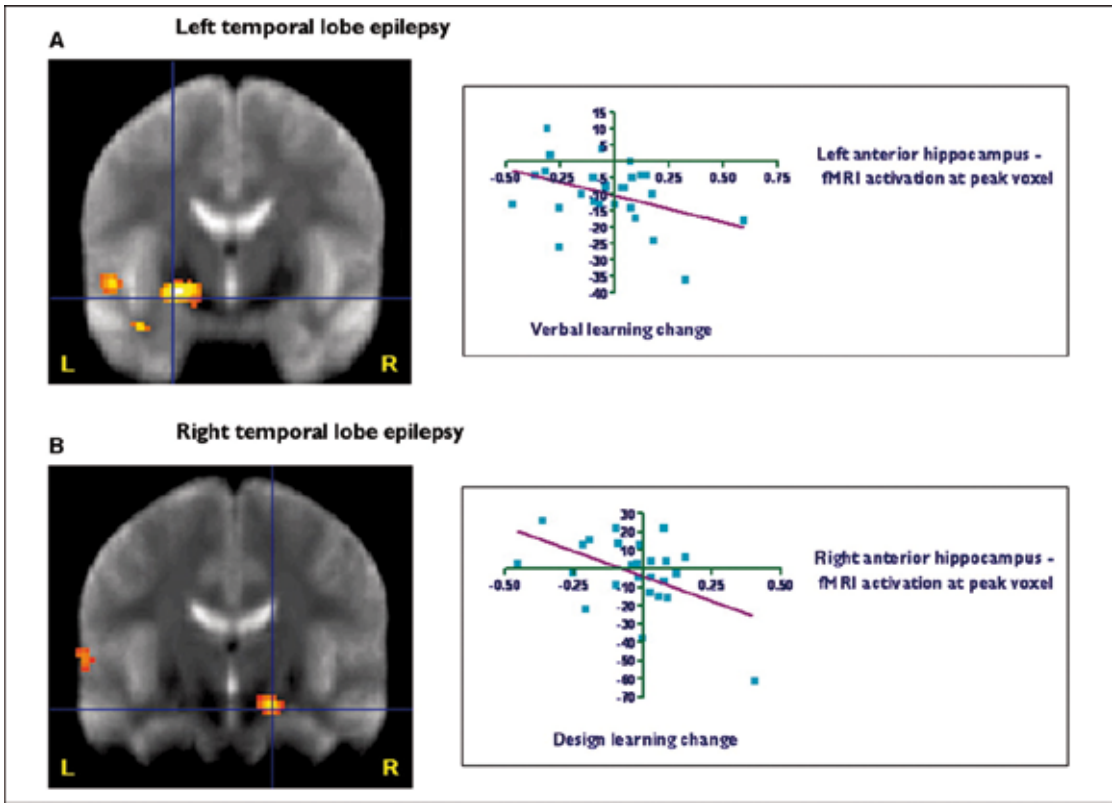

Figure 2: (adapted from Bonelli et al., Brain 2010): Functional MRI and prediction of postoperative verbal and visual memory decline

A: Patients with left temporal lobe epilepsy. Greater left anterior hippocampal activation for successful verbal encoding correlates with greater verbal memory decline after left anterior temporal lobe resection.

B: Patients with right temporal lobe resection. Greater right anterior hippocampal activation for successful encoding of faces correlates with greater visual memory decline after right anterior temporal lobe resection. The correlations for the peak voxel are illustrated on the right.

for contralateral hippocampal activation and demonstrated that relatively higher activation in the ipsilateral HC was associated with greater memory decline [34, 47]. Using a material-specific memory encoding paradigm in a large cohort of patients with unilateral TLE, Bonelli et al. demonstrated that relatively greater ipsilateral anterior MTL activation was predictive of verbal and visual memory decline after left or right ATLR while relatively greater posterior MTL activation was associated with better verbal and visual memory outcome [31] (**Figure 2**). In this study memory asymmetry indices of anterior MTL activation had the strongest predictive value for verbal and visual memory decline compared to other epilepsy related variables. A prediction model comprising the aforementioned memory asymmetry index in combination with degree of language dominance and preoperative verbal memory performance correctly predicted verbal memory decline in all patients of the study. Prediction of visual memory decline was less accurate [31].

Future Perspectives

As fMRI is a non-invasive tool the effects of epilepsy surgery on the brain and factors that are associated with effective functional reorganisation after surgery can be studied with repeated fMRI [18, 21, 52]. Further, newer structural MRI techniques and analyses have been used to infer on functional organisation of the brain. A voxel-based morphometry (VBM) study demonstrated a strong association of lateralisation of white matter in parts of the frontal and temporal lobes with individual language dominance [20]. A DTI study showed a predictive value of the laterality of fronto-temporal tract integrity for postoperative naming decline [53]. In case functional MRI cannot be applied due to a patient's low capacity, these techniques may provide useful information. Further, the combination of the different structural MRI methods with fMRI may substantially improve prediction of the effects of surgery on cognitive function.

Functional connectivity can elicit neuronal networks that contribute to various cognitive tasks. It has

been shown that cognitive impairment is often accompanied by reduced functional connectivity. Whether these methods may add to the prediction of postoperative cognitive outcome remains a topic of current research [54, 55].

Conclusions

Functional MRI is increasingly used to image cognitive function such as language and memory function. In the pre-surgical evaluation it can reliably assess language dominance and it helps to predict risks of cognitive decline after surgery. Up to date, invasive methods have not been fully replaced but non-invasive techniques may help planning invasive procedures. Non-invasive methods allow us to investigate healthy volunteers and to systematically compare different study groups and changes in activation over time to assess mechanisms of cognitive development and functional reorganisation. This may help to improve the individual prognosis of even subtle cognitive deficits and may stimulate the development of new therapeutic strategies for cognitive rehabilitation.

References

1. *Helmstaedter C. Effects of chronic epilepsy on declarative memory systems. Prog Brain Res 2002; 135: 439-453*
2. *Helmstaedter C. Neuropsychological aspects of epilepsy surgery. Epilepsy Behav 2004; 5(Suppl 1): S45-55*
3. *Hermann BP, Wyler AR, Somes G. Language function following anterior temporal lobectomy. J Neurosurg 1991; 74: 560-566*
4. *Witt JA, Helmstaedter C. Should cognition be screened in new-onset epilepsies? A study in 247 untreated patients. J Neurol 2012; 259: 1727-1731*
5. *de Tisi J, Bell GS, Peacock JL et al. The long-term outcome of adult epilepsy surgery, patterns of seizure remission, and relapse: a cohort study. Lancet 2011; 378: 1388-1395*
6. *Wiebe S, Blume WT, Girvin JP, Eliasziw M. A randomized, controlled trial of surgery for temporal-lobe epilepsy. N Engl J Med 2001; 345: 311-318*
7. *Rosenow F, Luders H. Presurgical evaluation of epilepsy. Brain 2001; 124: 1683-1700*
8. *Duncan J. The current status of neuroimaging for epilepsy. Curr Opin Neurol 2009; 22: 179-184*
9. *Haag A, Knake S, Hamer HM et al. The Wada test in Austrian, Dutch, German, and Swiss epilepsy centers from 2000 to 2005: a review of 1421 procedures. Epilepsy Behav 2008; 13: 83-89*
10. *Jansen JF, Aldenkamp AP, Marian Majoie HJ et al. Functional MRI reveals declined prefrontal cortex activation in patients with epilepsy on topiramate therapy. Epilepsy Behav 2006; 9: 181-185*
11. *Woermann FG, Labudda K. Clinical application of functional MRI for chronic epilepsy. Radiologe 2010; 50: 123-130*
12. *Dym RJ, Burns J, Freeman K, Lipton ML. Is functional MR imaging assessment of hemispheric language dominance as good as the Wada test?: a meta-analysis. Radiology 2011; 261: 446-455*
13. *Janecek JK, Swanson SJ, Sabsevitz DS et al. Language lateralization by fMRI and Wada testing in 229 patients with epilepsy: Rates and predictors of discordance. Epilepsia 2013; 54: 314-322*
14. *Fernandez G, Specht K, Weis S et al. Intrasubject reproducibility of presurgical language lateralization and mapping using fMRI. Neurology 2003; 60: 969-975*
15. *Kunii N, Kamada K, Ota T, et al. A detailed analysis of functional magnetic resonance imaging in the frontal language area: a comparative study with extraoperative electrocortical stimulation. Neurosurgery 2011; 69: 590-596, discussion 596-597*
16. *Roux FE, Boulanouar K, Lotterie JA et al. Language functional magnetic resonance imaging in preoperative assessment of language areas: correlation with direct cortical stimulation. Neurosurgery 2003; 52: 1335-1345, discussion 1345-1337*
17. *Giussani C, Roux FE, Ojemann J et al. Is preoperative functional magnetic resonance imaging reliable for language areas mapping in brain tumor surgery? Review of language functional magnetic resonance imaging and direct cortical stimulation correlation studies. Neurosurgery 2010; 66: 113-120*
18. *Bonelli SB, Thompson PJ, Yogarajah M et al. Imaging language networks before and after anterior temporal lobe resection – results of a longitudinal fMRI study. Epilepsia 2012; 53: 639-650*
19. *Binder JR, Swanson SJ, Sabsevitz DS et al. A comparison of two fMRI methods for predicting verbal memory decline after left temporal lobectomy: language lateralization versus hippocampal activation asymmetry. Epilepsia 2010; 51: 618-626*
20. *Labudda K, Mertens M, Janszky J et al. Atypical language lateralisation associated with right fronto-temporal grey matter increases – a combined fMRI and VBM study in left-sided mesial temporal lobe epilepsy patients. Neuroimage 2012; 59: 728-737*
21. *Salek-Haddadi A, Mayer T, Hamandi K et al. Imaging seizure activity: a combined EEG/EMG-fMRI study in reading epilepsy. Epilepsia 2009; 50: 256-264*
22. *Pal DK. Epilepsy and neurodevelopmental disorders of language. Curr Opin Neurol 2011; 24: 126-131*
23. *Fernandez G, Effern A, Grunwald T et al. Real-time tracking of memory formation in the human rhinal cortex and hippocampus. Science 1999; 285: 1582-1585*
24. *Ojemann JG, Akbudak E, Snyder AZ et al. Anatomic localization and quantitative analysis of gradient refocused echo-planar fMRI susceptibility artifacts. Neuroimage 1997; 6: 156-167*
25. *Wagner AD, Koutstaal W, Schacter DL. When encoding yields remembering: insights from event-related neuroimaging. Philos Trans R Soc Lond B Biol Sci 1999; 354: 1307-1324*
26. *Powell HW, Koepp MJ, Symms MR et al. Material-specific lateralization of memory encoding in the medial temporal lobe: blocked versus event-related design. Neuroimage 2005; 27: 231-239*
27. *Ivnik RJ, Sharbrough FW, Laws ER, Jr. Effects of anterior temporal lobectomy on cognitive function. J Clin Psychol 1987; 43: 128-137*
28. *Spiers HJ, Burgess N, Maguire EA et al. Unilateral temporal lobectomy patients show lateralized topographical and episodic memory deficits in a virtual town. Brain 2001; 124: 2476-2489*
29. *Detre JA, Maccotta L, King D et al. Functional MRI lateralization of memory in temporal lobe epilepsy. Neurology 1998; 50: 926-932*
30. *Golby AJ, Poldrack RA, Brewer JB et al. Material-specific lateralization in the medial temporal lobe and prefrontal cortex during memory encoding. Brain 2001; 124: 1841-1854*
31. *Bonelli SB, Powell RH, Yogarajah M et al. Imaging memory in temporal lobe epilepsy: predicting the effects of temporal lobe resection. Brain 2010; 133: 1186-1199*
32. *Jokeit H, Okujava M, Woermann FG. Memory fMRI lateralizes temporal*

lobe epilepsy. Neurology 2001; 57: 1786-1793
33. Powell HW, Richardson MP, Symms MR et al. Reorganization of verbal and nonverbal memory in temporal lobe epilepsy due to unilateral hippocampal sclerosis. Epilepsia 2007; 48: 1512-1525
34. Janszky J, Jokeit H, Kontopoulou K et al. Functional MRI predicts memory performance after right mesiotemporal epilepsy surgery. Epilepsia 2005; 46: 244-250
35. Richardson MP, Strange BA, Duncan JS, Dolan RJ. Preserved verbal memory function in left medial temporal pathology involves reorganisation of function to right medial temporal lobe. Neuroimage 2003; 20(Suppl 1): S112-119
36. Vannest J, Szaflarski JP, Privitera MD et al. Medial temporal fMRI activa-tion reflects memory lateralization and memory performance in patients with epilepsy. Epilepsy Behav 2008; 12: 410-418
37. Helmstaedter C, Elger CE. Cognitive consequences of two-thirds anterior temporal lobectomy on verbal memory in 144 patients: a three-month follow-up study. Epilepsia 1996; 37: 171-180
38. Jokeit H, Ebner A, Holthausen H et al. Individual prediction of change in delayed recall of prose passages after left-sided anterior temporal lobectomy. Neurology 1997; 49: 481-487
39. Chelune GJ. Hippocampal adequacy versus functional reserve: predicting memory functions following temporal lobectomy. Arch Clin Neuropsychol 1995; 10: 413-432
40. Trenerry MR, Jack CR, Jr, Ivnik RJ et al. MRI hippocampal volumes and memory function before and after temporal lobectomy. Neurology 1993; 43: 1800-1805
41. Baxendale S, Thompson P, Harkness W, Duncan J. Predicting memory decline following epilepsy surgery: a multivariate approach. Epilepsia 2006; 47: 1887-1894
42. Chelune GJ, Naugle RI, Luders H, Awad IA. Prediction of cognitive change as a function of preoperative ability status among temporal lobectomy patients seen at 6-month follow-up. Neurology 1991; 41: 399-404
43. Lineweaver TT, Morris HH, Naugle RI et al. Evaluating the contributions of state-of-the-art assessment techniques to predicting memory outcome after unilateral anterior temporal lobectomy. Epilepsia 2006; 47: 1895-1903
44. Baxendale S. The role of functional MRI in the presurgical investigation of temporal lobe epilepsy patients: a clinical perspective and review. J Clin Exp Neuropsychol 2002; 24: 664-676
45. Binder JR, Sabsevitz DS, Swanson SJ et al. Use of preoperative functional MRI to predict verbal memory decline after temporal lobe epilepsy surgery. Epilepsia 2008; 49: 1377-1394
46. Loring DW, Lee GP, Meador KJ et al. The intracarotid amobarbital procedure as a predictor of memory failure following unilateral temporal lobectomy. Neurology 1990; 40: 605-610
47. Rabin ML, Narayan VM, Kimberg DY et al. Functional MRI predicts post-surgical memory following temporal lobectomy. Brain 2004; 127: 2286-2298
48. Baxendale S, Thompson PJ, Duncan JS. Improvements in memory function following anterior temporal lobe resection for epilepsy. Neurology 2008; 71: 1319-1325
49. Richardson MP, Strange BA, Duncan JS, Dolan RJ. Memory fMRI in left hippocampal sclerosis: optimizing the approach to predicting postsurgical memory. Neurology 2006; 66: 699-705
50. Richardson MP, Strange BA, Thompson PJ et al. Pre-operative verbal memory fMRI predicts post-operative memory decline after left temporal lobe resection. Brain 2004; 127: 2419-2426
51. Powell HW, Richardson MP, Symms MR et al. Preoperative fMRI predicts memory decline following anterior temporal lobe resection. J Neurol Neurosurg Psychiatry 2008; 79: 686-693
52. Bonelli SB, Thompson PJ, Yogarajah M et al. Memory reorganisation following anterior temporal lobe resection – a longitudinal functional MRI study. Brain 2013; in press
53. Powell HW, Parker GJ, Alexander DC et al. Imaging language pathways predicts postoperative naming deficits. J Neurol Neurosurg Psychiatry 2008; 79: 327-330
54. Axmacher N, Mormann F, Fernandez G et al. Sustained neural activity patterns during working memory in the human medial temporal lobe. J Neurosci 2007; 27: 7807-7816
55. Voets NL, Adcock JE, Stacey R et al. Functional and structural changes in the memory network associated with left temporal lobe epilepsy. Hum Brain Mapp 2009; 30: 4070-4081

Address for correspondence:
Silvia B. Bonelli, MD, PD
Department of Neurology
Medical University of Vienna
Währinger Gürtel 18-20
A 1090 Vienna, Austria
Tel. 0043 1 40400 3120
Fax 0043 1 40400 6215
silvia.bonelli@meduniwien.ac.at

Valentina Garibotto[1] and Fabienne Picard[2]

[1] **Service de Médecine Nucléaire et Imagerie Moléculaire, Département d'Imagerie et des Sciences de l'Information Médicale, Hôpitaux Universitaires de Genève**

[2] **Unité d'EEG et d'exploration de l'épilepsie, Service de Neurologie, Département de Neurosciences Cliniques, Hôpitaux Universitaires de Genève**

Summary

Nuclear medicine imaging techniques play a relevant role in the investigation of pharmacoresistant epileptic patients, providing in vivo measures of perfusion changes, metabolic changes and neurotransmission abnormalities. This information helps identifying the ictal zone non-invasively in order to accurately plan more invasive procedures and ultimately surgery. In particular, ictal SPECT is the only technique showing the perfusion changes occurring during the epileptic event, while PET imaging in interictal state allows the evaluation of molecular aspects, such as glucose metabolism and various neurotransmission systems, thanks to the binding of different radioligands on specific targets and receptors. Technological developments, in particular the availability of new hybrid tomographs allowing PET and MRI imaging in a single session, will broaden our knowledge of the changes occurring in epilepsy through multiparametric investigations.

This review will update on the state-of-the-art nuclear medicine imaging modalities in the presurgical evaluation of epilepsy and will discuss the potential role played by the newly available hybrid PET/MRI imaging in this field.

Epileptologie 2013; 30: 109 – 121

Key words: Epilepsy, PET, SPECT, PET/MRI, radiotracers, neurotransmission

Imagerie par médicine nucléaire et épilepsie

Les techniques d'imagerie par méthodes de médecine nucléaire jouent un rôle important dans l'investigation des patients avec une épilepsie pharmaco-résistante, grâce à l'évaluation in vivo des modifications de perfusion cérébrale, de métabolisme cérébrale et des anomalies de neurotransmission. Ces informations permettent de guider l'identification non invasive de la zone de début ictal, pour planifier des investigations plus invasives et l'intervention chirurgicale. En particulier, l'imagerie SPECT ictale est la seule méthode d'imagerie qui permet de visualiser les modifications de perfusion qui se produisent au moment de la crise épileptique, alors que l'imagerie PET en phase interictale permet d'évaluer des aspects moléculaires tels que le métabolisme cérébral et différentes voies de neurotransmission. Les progrès technologiques récents, en particulier le développement de tomographes hybrides permettant de réaliser le PET et l'MRI lors d'une seule session d'imagerie, permettra d'approfondir notre connaissance des modifications et mécanismes moléculaires à la base des épilepsies grâce à des investigations multiparamétriques.

Cette revue résume les modalités de médecine nucléaire couramment utilisées dans l'évaluation préchirurgicale des épilepsies et débat du rôle potentiel de la nouvelle technologie hybride PET/MRI dans ce domaine.

Mots clés : Epilepsie, PET, SPECT, PET/MRI, radiotraceurs, neurotransmission

Nuklearmedizinische Bildgebung in der Epilepsie

Nuklearmedizinische Methoden spielen eine wichtige Rolle bei der Untersuchung von Patienten mit pharmakoresistenten Epilepsien. Die Methoden messen Perfusionsveränderungen, metabolische Veränderungen und Anomalien der Neurotransmitter. Die so gewonnenen Informationen erlauben, die iktale Zone nichtinvasiv zu identifizieren, um invasive Prozeduren und chirurgische Therapien zu planen. Das iktale SPECT ist die einzige Technik, die Perfusionsveränderungen während des epileptischen Anfalls messen kann, während PET in der interiktalen Phase die Auswertung der molekularen Aspekte, wie beispielsweise Glukose-Metabolismus und verschiedene Neurotransmitter-Systeme, mithilfe spezifischer Radioliganden ermöglicht. Weitere technologische Entwicklungen, insbesondere die Verfügbarkeit der neuen Hybrid-Bildgebung PET/MRI, die PET- und MRI-Bildgebung in einer einzigen Sitzung liefert, werden unser Wissen über die funktio-

nellen Veränderungen in der Epilepsie vertiefen, insbesondere durch multiparametrische Untersuchungen.

Der vorliegende Überblick fasst State-of-the-art der nuklearmedizinischen Bildgebung in der prächirurgischen Evaluierung der Epilepsie zusammen und diskutiert die mögliche Rolle der neuen PET-MRI-Hybrid-Systeme.

Schlüsselwörter: Epilepsie, PET, SPECT, PET/MRI, Radiotracer, Neurotransmission

Introduction

Two nuclear medicine imaging techniques are currently applied in clinical practice for the investigation of pharmacoresistant epileptic patients: Single Photon Emission Computed Tomography (SPECT) studies of brain perfusion in ictal and interictal state and Positron Emission Tomography (PET) studies of glucose metabolism in interictal state. In addition, molecular imaging by PET may allow measuring various neurotransmission systems, for example the GABAergic, serotonergic, cholinergic and opiate receptor systems, among others: these investigations are still mainly performed in dedicated research centers. Finally, technological developments, in particular the design of hybrid tomographs acquiring both PET and Magnetic Resonance Imaging (MRI) in a single session, called PET/MRI hybrid systems, are currently available and will presumably play a relevant role in the investigation of epileptic patients.

1. SPECT Perfusion Studies in Ictal and Interictal State

The clinical observation that during a seizure there is an increase in cortical blood flow was initially directly observed during brain surgery by Sir Victor Horsley, more than a century ago [1].

SPECT imaging uses perfusion tracers, such as [^{99m}Tc]-HMPAO and [^{99m}Tc]-ECD, which cross the blood brain barrier freely and without significant redistribution. Once injected, the tracer distributes rapidly, over a few minutes, and then this distribution is stable over a long time (up to four or five hours). Thus, the images subsequently acquired reflect the perfusion state at the time of injection, providing a "picture" of ictal perfusion even a few hours after the seizure. The characteristics of these ^{99m}Tc-labelled tracers (low redistribution and 6 hours half-life) give the flexibility to stabilize and transfer the patient to the SPECT unit for imaging conveniently after the injection.

To be able to realize ictal imaging, the patient must be under continuous EEG monitoring and the tracer must be readily available at bedside. The unit must be designed in a way that a trained nurse or technologist is immediately available for performing a bolus injection at the first signs (electrophysiological or clinical) of seizure onset. The availability of automated injection systems represents an additional advantage.

The ictal SPECT imaging, depending on the time delay between seizure onset and tracer administration, reflects the hyperactivity at the ictal onset zone and at the propagation areas [2].

Timing of the injection is thus a crucial issue, critically determining the clinical information that can be obtained with the ictal SPECT imaging. Indeed, the perfusion pattern rapidly evolves after the ictal onset. In temporal lobe epilepsy, the initial ictal hyperperfusion of the seizure onset zone and of the propagation areas is rapidly followed by a hypoperfusion of the same areas, presumably due to autoregulatory mechanisms limiting excitotoxic damage [3]. In extratemporal neocortical epilepsy, different patterns have been observed, including or surrounding the ictal onset zone, depending on the delay of the injection and on the crisis duration [4]. The sensitivity of the ictal SPECT analysis is significantly lower when the injection is performed more than 20 seconds after the onset [5, 6].

Interictal imaging is routinely performed in order to provide a baseline comparison for ictal changes, and indeed increases sensitivity and specificity of SPECT findings. Importantly, the imaging protocols should be identical in both conditions, as well as image display for visual interpretation, in order to ensure comparability [2].

In addition to visual image interpretation, computer-assisted analysis has an important and validated role for detecting changes in brain perfusion, with a proven gain in sensitivity [5, 7, 8]. Ictal and interictal imaging can be compared by normalizing counts in each image to the activity in a given region or to the global activity. Subsequently, the two scans are spatially registered, preferably using also an MRI scan, providing as result a subtraction parametric image of significant deviation between ictal and interictal SPECT. This function is implemented in various software packages: among these, the Subtraction Ictal SPECT CO-registered to MRI (SISCOM) [9] and the HERMES BRASS software suite (www.hermesmedical.com). An example of ictal and interictal images and the result of digital image subtraction is shown in **Figure 1**.

In our institution, ictal SPECT identified correctly the epileptic zone in 75% temporal lobe epilepsy and in 58% of extra-temporal cases [10]. Ictal SPECT is overall most useful in patients with focal epilepsy and normal MRI, or in cases where MRI shows multiple abnormalities: in the latter, ictal SPECT might be able to identify the epileptogenic lesion.

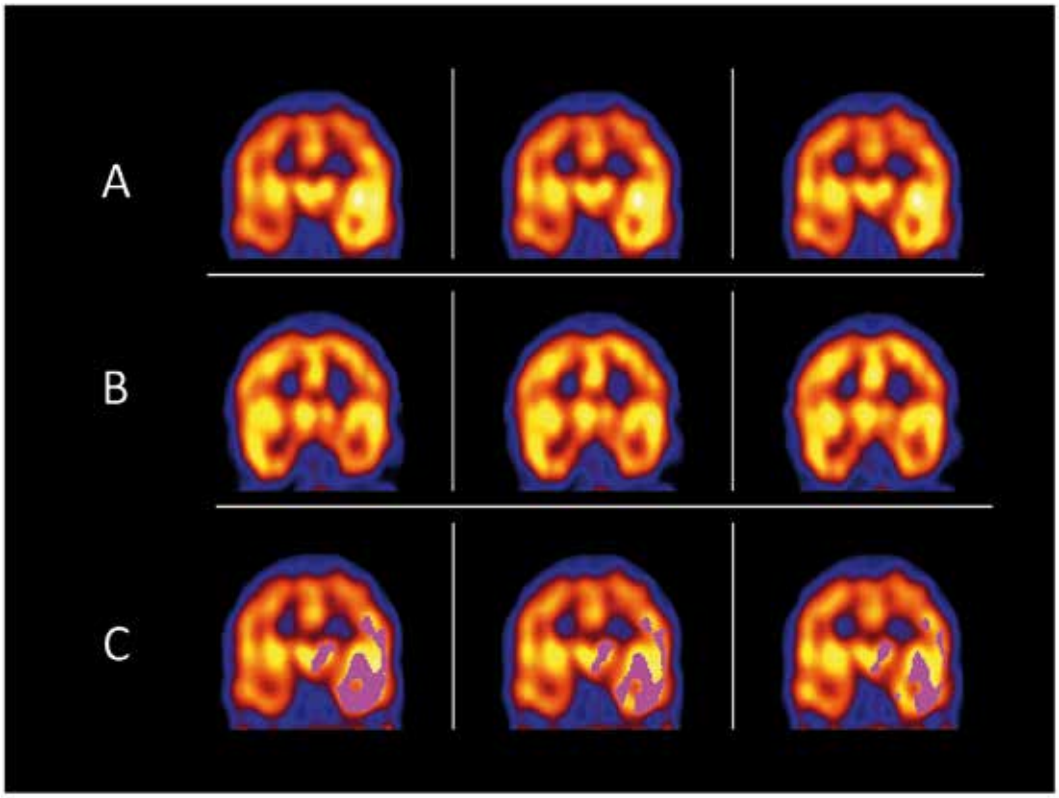

Figure 1: Ictal (A) and interictal (B) perfusion in a patient with left amygdalo-hippocampal dysplasia. In line C the areas significantly hyperperfused in ictal state, obtained by digital subtraction using the HERMES BRASS software suite, are shown (pink overlay on ictal image).

2. FDG PET Imaging in Epilepsy

PET has been the first functional neuroimaging technique applied to presurgical evaluation of pharmacoresistant focal epilepsies, in the late seventies, before MRI was available. It used the [^{18}F]-Fluorodeoxyglucose (FDG) to obtain images of interictal brain glucose metabolism. It was particularly useful in patients with a normal brain CT scan, showing a focal interictal glucose hypometabolism. FDG PET remains today a routinely used examination in the presurgical assessment of drug refractory focal epilepsies [11]. Focal interictal hypometabolism on FDG PET is usually associated with seizure foci, but hypometabolism is typically larger than the epileptogenic cortex, reflecting the altered neuronal function in the ictal focus and possibly extending to the areas of first ictal spread [12]. An example of a large hypometabolic area extending to the whole temporal pole in a patient with amygdalo-hippocampal dysplasia is provided in **Figure 2**. The mechanism explaining the hypometabolism in ictal areas is still mostly unknown: various hypotheses have evoked a protective inhibitory effect induced by repeated seizures on the brain or the underlying dysfunctional cortex (dysplasic areas, tubers, etc) [13]. Hypometabolism is usually less frequent in children with new onset seizures [14]. It is well known that FDG PET distribution reflects mainly synaptic density and activity, therefore hypometabolism presumably reflects mainly synaptic changes rather than cell loss [15].

Given the spatial resolution of PET imaging, ranging between 4 and 8 millimeters depending on the tomograph characteristics and settings, and the fact that FDG PET changes are larger than the actual ictal onset zone, the definition of surgical borders cannot be solely based on PET imaging.

Rather, PET results can help lateralizing and localizing the focus in cases of non-lesional epilepsy, in cases with multiple lesions visible on MRI and can guide intracranial electrode placement [16]. FDG PET has overall an established role in the presurgical evaluation of various types of epilepsy, for diagnostic and prognostic evaluation [17 - 19].

In current clinical practice, FDG PET is usually acquired on PET/CT scanners, although recent developments suggest that the newly available PET/MRI hybrid modality might play a relevant role (see Section 4).

FDG PET images are primarily analyzed visually, with the support of semiquantitative analyses, such as asymmetry indices. Asymmetry is usually rated as significant when a difference above 15% exists between the affected and contralateral sides, given that small

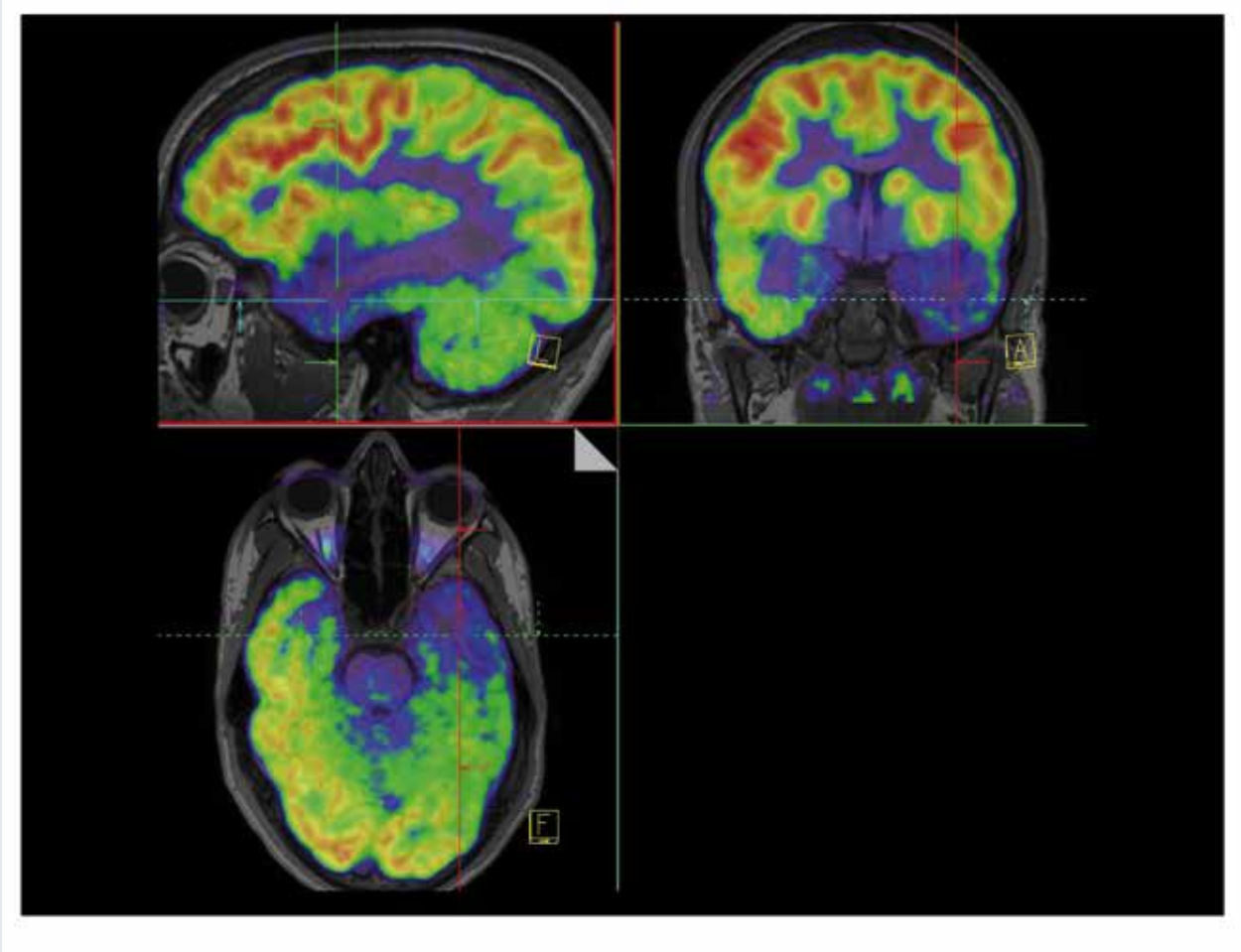

Figure 2: Large left temporopolar hypometabolism in a patient with amygdalo-hippocampal dysplasia (same patient as in Figure 1).

physiological asymmetries can exist [20]. Another tool that is particularly relevant for PET image interpretation is the systematic adoption of software fusion of PET and MRI datasets. There is evidence suggesting that the systematic association of PET and MRI imaging can be recommended for a complete evaluation of epilepsy: previous reports consistently demonstrated the added value of software fusion of PET and MRI data for the pre-surgical evaluation of cortical dysplasia [21, 22]. The image fusion not only allows a more precise localization of hypometabolic areas but also allows identifying small areas of hypometabolic cortex that could be overseen when reading the PET images alone. An additional advantage of a systematic fusion with MRI would be the adoption of strategies for the correction of the partial volume effect on PET images, based on MRI segmentation, that can offer a superior sensitivity for identifying small abnormalities [23].

Overall, in our institution experience FDG PET correctly identified the ictal focus in 69% of patients with temporal lobe epilepsy and in 75% in extratemporal epilepsies [10].

3. Research PET Tracers

PET imaging also allows measuring neurotransmission abnormalities underlying neuronal hyperexcitability. This is of particular importance in the context of presurgical assessment of pharmacoresistant focal epilepsies, or in order to improve our understanding of the pathophysiological mechanisms of epilepsy. This requires radioactively labelled tracers which are either ligands of specific receptors or neurotransmitter precursors or transporters. Thus, one of the most promising applications of PET in the epilepsy study consists in imaging the distribution of these molecular targets in the interictal state.

Various PET tracers are available for neurotransmitter and neuromodulator systems, including the GABA, serotonin, dopamine, glutamate, acetylcholine, adenosine and opioid systems. These tracers are currently used in research centers and are not yet part of the clinical routine investigations.

3.1 GABA system

The selective antagonist of $GABA_A$ receptors, [^{11}C]-flumazenil, has been the first PET receptor ligand which was used in epilepsy. A localized reduction of [^{11}C]-flumazenil binding, closely correlating with the side and site of seizure onset, is usually observed in patients with refractory focal seizures. This reduced binding is thought to largely reflect an underlying neuronal loss, as demonstrated in temporal lobe epilepsy associated with mesial temporal sclerosis (review in [24, 25]). In a study of 20 patients with intractable partial epilepsy of neocortical origin and non-localizing MRI, focal decrease of cortical FMZ binding was detected in the lobe of seizure onset in 85% of the patients [26]. Decreased FMZ binding was also observed in remote cortical areas outside the lobe of seizure onset in 55% of the patients. The authors concluded that these regions are commonly involved in rapid seizure propagation and that although these regions may not always need to be resected to achieve seizure freedom, a careful evaluation of cortex with decreased $GABA_A$ receptor binding prior to resection using intracranial EEG may facilitate optimal surgical outcome in patients with intractable neocortical epilepsy [26].

3.2 Serotonin system

The serotonin system originates from the raphe nuclei, with diffuse projections to the whole central nervous system. According to studies in experimental models of epilepsy, serotonin (5-HT) has an inhibitory role on epileptiform discharges [27, 28]. Specifically, antiepileptic and anticonvulsant properties of 5-HT_{1A} receptor activation has been shown in rodents [29]. This anti-epileptic effect can be blocked by the highly selective 5-HT_{1A} antagonist WAY-100635 [30]. An additional observation supporting the potential role played by serotonergic transmission is that the epileptogenic tissue of patients with cortical dysplasia has enhanced serotonergic innervation [31].

3.2.1 α[^{11}C]*methyl-L-tryptophan (AMT)*

Serotonin is synthesized from the neutral amino acid L-tryptophan. α[^{11}C]methyl-L-tryptophan (AMT) is a tracer for measuring the rate of serotonin synthesis. One of the main advantages of using PET with AMT for imaging in epilepsy is that it shows increased (rather than decreased) uptake in epileptic foci.

AMT PET has a unique ability to successfully identify the epileptogenic tuber(s) in patients with tuberous sclerosis and intractable epilepsy [32 - 35]. It shows locally increased uptake of AMT in and around the epileptogenic tuber, while it shows normal or decreased uptake in non-epileptogenic tubers [34]. The sensitivity of AMT PET in finding the epileptogenic focus is about 70%, but its specificity is almost 100%, indicating that if AMT PET identifies an area of increased uptake, it likely represents the epileptic focus which needs to be resected for better surgical outcome [36]. In a study of 17 children who underwent resective epilepsy surgery following AMT PET, the tuber with the highest uptake was located in an ictal EEG onset region in each patient [36]. Tubers with at least 10% increase of AMT uptake proved to be epileptogenic based on intracranial EEG and outcome criteria. The different studies demonstrated that resection of tubers with increased AMT uptake is essential to achieve seizure-free surgical outcome in these patients.

Increased AMT uptake is also well recognized in cortical developmental malformations. The uptake is higher in patients with histologically proven cortical dysplasia compared to those with nonspecific pathological changes (i.e. gliosis) and may predict type IIB dysplasia (with balloon cells) and good surgical outcome [37]. This correlates with previous human epileptic tissue studies showing serotonergic hyperinnervation in dysplastic tissues [31]. Histopathologic similarities between cortical dysplasia type IIB and epileptogenic cortical tubers may imply a common role of the inflammatory kynurenine pathway of tryptophan metabolism in these lesions [37].

In patients with intractable epilepsy and cortical dysplasia, the increased uptake of AMT was shown to be highly co-localized to the area of neocortical seizure onset defined on electrocorticography. Remote cortex involved in seizure propagation does not appear to show increased uptake on AMT PET images. In contrast, the regions of reduced metabolism on FDG PET are widespread and might be less specific. Increased AMT uptake was also found in a very high proportion of epileptogenic brain tumors, including low-grade gliomas and dysembryoplastic neuroepithelial tumors, but it is not always related to epileptogenicity as it has been observed in some gliomas not associated with seizures [38].

AMT PET has a lower sensitivity for the lateralization and localization of epileptic foci in patients with cryptogenic focal epilepsy. However increased focal uptake of AMT may be observed in a proportion of patients with no detectable lesion on MRI and can be a valuable addition to current methods of investigation [39]. One study showed that AMT PET might be useful for lateralizing the epileptic focus in patients with temporal lobe epilepsy (TLE) and normal hippocampal volumes: an increased AMT uptake was reported in the hippocampus ipsilateral to the seizure focus in a group of seven TLE patients with normal hippocampal volumes [40]. However other larger studies are needed to further substantiate the clinical use of AMT PET in evaluation of patients with suspected TLE and no hippocampal sclerosis. Lastly, AMT PET was shown to be a useful imaging approach for identification of non-resected epileptic

cortex in patients with a previously failed neocortical epilepsy surgery [41]. It is proposed to wait at least 2 months after surgery before scanning the patients.

In conclusion AMT is a useful tracer in the presurgical evaluation of patients with epilepsy and displays a particularly high specificity for the dysplastic lesions of tuberous sclerosis or cortical dysplasia.

3.2.2. Ligands of 5-HT$_{1A}$ receptors

The 5-HT$_{1A}$ receptors constitute the best characterized subtype of currently known 5-HT receptors.

3.2.2.1. [^{11}C]-WAY-100635 and [^{18}F]-FCWAY

[^{11}C]-WAY is an antagonist ligand of 5-HT$_{1A}$ receptors. It is very specific with a much higher affinity than endogenous serotonin for 5-HT$_{1A}$ receptors (Kd in the range of 20 pmol), so [^{11}C]-WAY does not interact with serotonin.

PET using [^{11}C]-WAY-100635 was performed in patients with severe mesial TLE (MTLE) to test the hypothesis that in MTLE there is involvement of serotonin systems outside of mesial structures [42]. Fourteen patients and 14 controls were studied. The 5-HT$_{1A}$ receptor binding potential was calculated for hippocampus, amygdala, orbitofrontal, insular, lateral temporal, anterior cingulate cortex, raphe nuclei, and in two regions presumably uninvolved in the epileptogenic process (parietal, and dorsolateral frontal neocortex). The 5-HT$_{1A}$ binding was significantly reduced in the epileptogenic hippocampus and amygdala ($p = 0.0001$) in all patients, including the six with normal FDG PET and MRI. It was also reduced in the anterior cingulate, insular, and lateral temporal cortex ipsilaterally to the focus, in contralateral hippocampus, and in the raphe nuclei. The authors concluded that there is reduced 5-HT$_{1A}$ receptor binding potential in the EEG focus and its limbic connections and that the affective symptoms in MTLE may result from reductions in 5-HT$_{1A}$ binding in the insular and cingulate cortex. [^{11}C]-WAY-100635 PET was considered to provide additional information to EEG, FDG PET, and MRI when evaluating pharmacoresistant patients.

[^{18}F]-FCWAY presents an affinity for 5-HT$_{1A}$ receptors comparable to that of the original WAY-100635 labeled with ^{11}C. A PET study with [^{18}F]-FCWAY showed decreased temporal 5-HT$_{1A}$ binding ipsilateral to seizure foci in patients with TLE [43]. A complementary study demonstrated that decreased 5-HT$_{1A}$ binding in insula and mesial temporal structures ipsilateral to temporal lobe epileptic foci is not an artifact related to partial volume effect because of the mesial temporal sclerosis and structural atrophy [44]. These studies suggest that the receptor loss may be part of the initial phase of neuronal dysfunction in TLE, followed by hypometabolism and eventual structural atrophy. The decrease in 5-HT$_{1A}$ binding exceeded both FDG hypometabolism and hippocampal atrophy, and could be detected in mesial temporal regions in patients with normal MRI. Thus [^{18}F]-FCWAY PET might be particularly useful for early detection of functional abnormalities in TLE patients. Other recent studies confirmed the additional value of the [^{18}F]-FCWAY PET examination to FDG PET for epileptic focus detection and temporal lobectomy planning, particularly in MRI-negative TLE [45, 46]. One of these studies suggested that reduced left hippocampal receptor 5-HT$_{1A}$ receptor binding may play a role in memory impairment in patients suffering from TLE [47].

PET using [^{11}C]-WAY-100635 was also performed in 12 patients with juvenile myoclonic epilepsy (Savic, personal communication, "The new and very new PET tracers in epilepsy", Satellite symposium to the 26th IEC, Orsay, Paris, 2005). There was a 25% reduction of 5-HT$_{1A}$ binding in the dorsolateral prefrontal cortex. It is worth to note that the same patients were investigated with MR spectroscopy showing reduction in N-acetylaspartate in the dorsolateral prefrontal cortex, concordant at MRI spectroscopy with a reduction in N-acetylaspartate in the same area, and also had impaired working memory. In addition, an unexpected finding was a bilateral reduction of [^{11}C]-WAY-100635 binding in the hippocampus, despite normal hippocampal volumes. The authors suggested that 5-HT$_{1A}$ receptor binding could be a useful approach in future to detect potential hippocampal changes which are not visible on MRI in neocortical epilepsies, generalized epilepsies or in psychiatric disorders.

3.2.2.2. [^{18}F]-MPPF

MPPF is another selective antagonist of 5-HT$_{1A}$ receptors. It has an affinity close to that of endogenous serotonin for 5-HT$_{1A}$ receptors and is thus sensitive to endogenous serotonin variations. Thus a decrease of [^{18}F]-MPPF binding can be interpreted as reflecting either a decrease in receptor density or an increase in endogenous serotonin, resulting in a competition for receptor binding by the radioligand.

PET studies with [^{18}F]-MPPF carried out in a group of TLE patients with hippocampal ictal onset showed significant decreases ipsilateral to the epileptogenic zone in the hippocampus, temporal pole, insula and temporal neocortex [48, 49]. A large study of 42 TLE patients showed that a decreased binding in hippocampus, amygdala and temporal pole (example in **Figure 3**) indicated good candidates for anterior temporal lobectomy, as all these patients became seizure-free after surgery, even when the clinical presentation was not that of a typical mesiotemporal lobe epilepsy or when there was no hippocampal atrophy [50]. The interpretation that the decrease in 5-HT$_{1A}$ receptor binding in epileptic

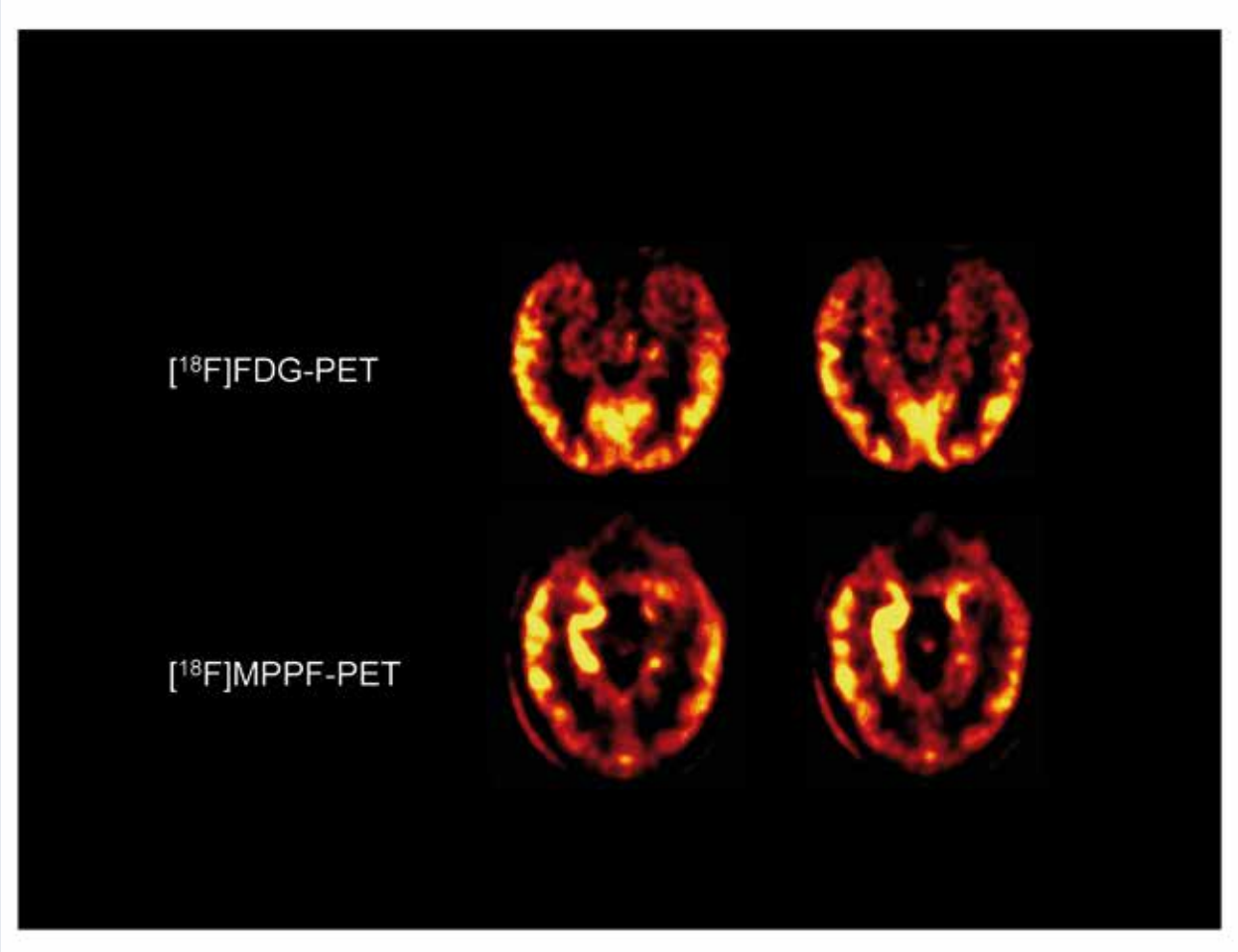

Figure 3: [^{18}F]-FDG PET and [^{18}F]-MPPF PET in a patient with a temporo-limbic epilepsy and normal MRI: the images show a slight decrease in FDG uptake and a clear and severe MPPF binding reduction located within the left temporal region. (Courtesy of Prof. P. Ryvlin)

patients could reflect the loss of neurons in the hippocampus was challenged by the report in epileptic foci of an increase in P-glycoprotein, an ATP-driven transmembrane efflux pump, known to strongly regulate the penetration of [^{18}F]-MPPF in the brain [51]. The binding of [^{18}F]-MPPF might be modified by extracellular serotonin levels, internalization of 5-HT_{1A} receptors and the expression of P-glycoprotein.

3.3 Dopamine system

Studies in animal models and epileptic patients have suggested that circuits of the basal ganglia may control epileptic seizures and that striatal dopaminergic transmission plays a key role in seizure interruption [52]. Moreover there is evidence from clinical experience that antagonizing D2 receptors lower seizure threshold.

3.3.1. [^{18}F]-fluoro-L-DOPA

[^{18}F]-fluoro-L-DOPA is a radiotracer that permits measurements of presynaptic dopaminergic function. A [^{18}F]-fluoro-L-DOPA PET study was performed in patients with a ring chromosome 20 suffering from epilepsy. Their epilepsy is characterized by long-lasting seizures suggesting a dysfunction in the seizure control system. [^{18}F]-fluoro-L-DOPA PET showed a significantly decreased uptake in both putamen and caudate nucleus, suggesting that a dysfunction of the striatal dopamine neurotransmission may impair the mechanisms that interrupt seizures [53].

Patients with generalized seizures and patients with focal seizures related to hippocampal sclerosis were also studied [54]. There was a decreased [^{18}F]-fluoro-L-DOPA uptake, particularly in the substantia nigra bilaterally, in all patients. The uptake was also decreased in the putamen, bilaterally, in patients with generalized seizures and unilaterally, ipsilateral to the hippocampal sclerosis, in patients with focal seizures.

3.3.2. [^{18}F]-Fallypride

[^{18}F]-Fallypride is a highly selective, high-affinity, dopamine D_2/D_3-receptor ligand suitable for measuring D_2/D_3 receptor availability in the extrastriatal regions of the brain. A group of seven patients with TLE and hippocampal sclerosis, was compared with a group of controls [55]. Compared with controls, [^{18}F]-Fallypride binding potential was significantly decreased in the epileptogenic temporal lobe in all patients. On the analysis of regions of interest, this reduction was evident in areas surrounding the seizure onset zone, at the temporal pole (-34%) and the anterior part of the lateral temporal lobe (-33%). Although the hippocampal FDG uptake (-8%) and hippocampal MR volume (-35%) were significantly reduced, no significant decrease of [18F]-Fallypride binding potential was found in the hippocampal area. The area of decreased binding (pole and lateral parts of the epileptogenic temporal lobe) might correspond to "the irritative zone", suggesting that D_2/D_3 receptors might play a specific role in the pathophysiology of MTLE.

3.3.3. [^{11}C]-SCH23390

[^{11}C]-SCH23390 is a dopamine D_1-receptor ligand. A reduced binding in the right putamen (increased extracellular dopamine levels or receptor downregulation) was shown in patients with autosomal dominant nocturnal frontal lobe epilepsy (ADNFLE) and an identified nicotinic receptor mutation (in the α4 subunit) [56]. The authors suggested that alterations in mesostriatal dopaminergic circuits may contribute to nocturnal paroxysmal motor activity.

3.3.4. [^{11}C]-PE2I

[^{11}C]-PE2I is a radioligand that provides high-contrast delineation of brain regions that are rich in dopamine transporters. Studies have been performed in patients with idiopathic generalized epilepsy. An impaired dopamine uptake was observed in the midbrain in patients with juvenile myoclonic epilepsy [57, 58], and in the putamen in patients with generalized tonic-clonic seizures only [57].

3.4 Glutamate / NMDA system

Glutamate is the principal excitatory neurotransmitter in the human brain. Its receptors are divided into ionotropic and metabotropic receptors. N-methyl-D-aspartate (NMDA) receptors form a subclass of ionotropic glutamate receptors. Enhanced excitatory transmission has long been known to play a central role in the generation of seizures and the development of epilepsy. The NMDA receptors have been studied in human epileptogenic brain with conflicting results. Increased as well as decreased receptor binding has been reported in epileptogenic tissue.

3.4.1. [^{11}C]-CNS 5161

CNS 5161 is an NMDA antagonist that binds with high affinity to NMDA ion channel sites. [^{11}C]-CNS 5161 was developed as a potential PET tracer. Four healthy control subjects and a single pilot case with MTLE were scanned with this tracer (Hammers, "The new and very new PET tracers in epilepsy", Satellite symposium to the 26th IEC, Orsay, Paris, 2005). While hippocampal volume on the affected side was reduced by 27% compared to the contralateral side, [^{11}C]-CNS 5161 volume of distribution was reduced by only 13%. This may indicate an actual increase in open NMDA channels per volume unit of tissue on the epileptogenic side. Larger studies, with partial volume correction, are needed. There are no new reported data since this pilot study in epilepsy, but a study using PET with [^{11}C]-CNS 5161 in patients with Parkinson's disease was published in *Brain* in 2011 [59].

3.4.2. [^{11}C]-ketamine

Ketamine is an anaesthetic which binds specifically and reversibly to the NMDA receptor in a non-competitive manner, with a receptor affinity (Kd) in the µmol range. PET studies in monkeys and humans have shown that the distribution of [^{11}C]-ketamine corresponds to regions with high density of glutamate receptors.

Eight patients with MTLE were evaluated by PET using [^{11}C]-ketamine [60]. A side-to-side comparison revealed a 9-34% reduction of tracer radioactivity in the temporal lobes of ictal onset compared with the contralateral side. The magnitude and distribution of the reduction were similar to the metabolic pattern seen on FDG PET. This reduction may reflect reduced NMDA receptor density, reduced perfusion, focal atrophy, or other factors. Further studies with correction for partial volume effects and perfusion differences are needed.

3.5 Nicotinic cholinergic system

About fifteen years ago, mutations were identified in autosomal dominant nocturnal frontal lobe epilepsy (ADNFLE), in genes coding for two different subunits of the neuronal nicotinic acetylcholine receptor (nAChR), respectively the α4 and the β2 subunits. To date such mutations have been found in about twenty families. These subunits are known to assemble and form the main brain nicotinic receptor subtype in humans (α4β2 nAChR). The nAChRs are excitatory receptor channels

permeable with cations (Na^+, K^+, $Ca2^+$), and are widely distributed throughout the brain with a particularly high density in the thalamus for the $\alpha4\beta2$ nAChR. Most of these receptors are presynaptic and have a neuromodulatory role consisting of an enhancement of the release of GABA, glutamate, dopamine, norepinephrine, serotonin or acetylcholine.

The [^{18}F]-2-Fluoro-A-85380 (3-[2(S)-2-azetidinylmethoxy]pyridine) (F-A-85380) is a ligand with a high affinity and specificity for the central $\alpha4\beta2$ nAChRs, with brain tracer concentrations reflecting the receptor concentration [61].

A PET using [^{18}F]-F-A-85380 was performed in a group of 8 patients with ADNFLE carrying a mutation in a nAChR subunit, in comparison with a group of healthy volunteers [62]. Patients and volunteers were all non-smokers. Parametric images of volumes of distribution were generated using the ratio between brain tissue concentration and the unchanged plasma concentration. The images showed a clear difference in the pattern of the nAChR density in the brains of the patients compared to the healthy volunteers, with a significant increase (between 12 and 21%, $p < 0.05$) in the ADNFLE patients in the mesencephalon, the pons and the cerebellum. Statistical parametric mapping (SPM) confirmed clear regional differences between patients and controls: patients had a statistically significant increase in nAChR density in the epithalamus, ventral mesencephalon and cerebellum, but decreased nAChR density in the right dorsolateral prefrontal region. In 5 patients who underwent an additional FDG PET experiment, hypometabolism was observed in the neighbouring area of the right orbitofrontal cortex. The demonstration of a regional nAChR density decrease restricted in the prefrontal cortex, despite the known distribution of these receptors throughout the cerebral cortex, is consistent with focal epilepsy involving the frontal lobe. In addition, these results suggest that the nAChR density increase in the mesencephalon is involved in the pathophysiology of ADNFLE through the role of brainstem ascending cholinergic systems in arousal. A PET examination of other forms of epilepsy is currently under way, to confirm the specificity of the above-mentioned results for ADNFLE.

3.6 Adenosine system (A_1 adenosine receptor)

Adenosine is different from regular transmitters: it is not released in a vesicular way, not released in synapses, but is produced in the cell like the "sweat" of the cell. Whenever the cell has to work, adenosine production increases intra- and extra-cellularly, activating the modulatory adenosine receptors. There are four different types of receptors, with different affinities for adenosine. The receptors with the highest affinity are the A_1 and A_{2A} subtypes.

In cases of high energy demand, such as in the early phases of an epileptic seizure, there is a massive increase of adenosine that is transported from the inside to the outside of the cell and thus can activate A_1 receptors. It has been shown in animal models in the last two decades that the activation of A_1 receptors increases activation of inhibitory G proteins and then helps stopping seizure activity. Adenosine is considered to be responsible for seizure arrest and for post-ictal refractoriness and thus appears to be an endogenous antiepileptic regulator. The deficiencies within this system might result in a higher susceptibility for seizures or epileptogenesis. Most studies report reductions of A_1 receptor density in experimental epilepsy models and in human post-mortem brain material of patients with epilepsy.

The radiotracer available for the A_1 adenosine receptor is CPFPX, which stems from the same group as caffeine (caffeine being a non-selective blocker of adenosine receptors). CPFPX is fluorinated ([18F]-CPFPX). It has relatively high affinity of 1.3 nM with rather high selectivity: A_1/A_{2A} >700. In human brain, there is a high uptake within the striatum, the caudate nucleus, the putamen, part of the medial anterior thalamus and neocortical regions. A study performed in a F98 rat model for brain tumors showed that there was an increased density of adenosine A_1 receptors surrounding the tumor as well as surrounding the necrosis which was visible in the tumor [63]. The upregulation of A_1 receptors is primarily on astrocytes. A PET study using [^{18}F]-CPFPX in a patient with a glioma also revealed increases in A_1 adenosine receptor density in the immediate vicinity of the tumor. However, in contrast to the rat findings, there was a decrease of A_1 receptor binding surrounding this zone of increased receptors [63]. This zone of "reduction of inhibitory capacity" could contribute to tumor-associated epilepsy. So the density of A1 receptors is within the normal range in the tumour, increased in the immediate peri-tumoral zone and decreased in the extra-tumoral area, which may result in an increased excitability of the brain. Two patients with TLE have also been studied (Bauer, "The new and very new PET tracers in epilepsy", Satellite symposium to the 26th IEC, Orsay, Paris, 2005). In the first case, including unilateral hippocampal sclerosis, there was a reduction of the hippocampal [^{18}F]-CPFPX signal on the sclerotic side. In a second case of TLE plus with dystrophic changes seen in the neocortex, lateralized decreased signal was observed compared to the contralateral side and compared to control levels. These data were not partial volume corrected. It has to be noted that in autoradiographic studies of surgically resected hippocampi, densities were far lower than in control samples.

3.7 Opioid system

The opioid receptors can be classified into at least three types: μ-, δ- and κ-receptors. Opioid peptide release is calcium-dependent and requires high frequency neuronal firing; opioid peptides act as mediators of use-dependent synaptic activity and as co-transmitters to modulate the actions of the primary transmitter [64]. Opioid receptor availability reflects endogenous opioid concentrations. Animal and limited human data suggest an important anticonvulsant role for opioid peptides and their receptors. Exogenously applied opioids have predominantly inhibitory actions on neuronal activity and transmitter release throughout the brain. There is a large body of animal data showing that endogenous opioid release may occur following induced and spontaneous seizures and that increased opioid neurotransmission has an anticonvulsant role. However, the human relevance of these studies can only, at best, be inferential.

The tracer diprenorphine (DPN) is a non-selective partial agonist, with similar affinity for μ-, δ- and κ-receptors. It is displaced by endogenous opioids [65]. It shows high binding to basal ganglia, amygdala, and layers V and VI of the cerebral cortex. One study aimed to provide direct human in vivo evidence for changes in opioid receptor availability following spontaneous seizures [66]. Nine patients with refractory TLE were scanned by PET using [^{11}C]-DPN within hours of spontaneous temporal lobe seizures (median interval: 8.5 h post-ictally). A second scan was acquired days to weeks later, after as long a seizure-free period was achievable in a given patient, and served as an intra-subject control (corresponding to interictal binding). A regionally specific increase of opioid receptor availability was evident following seizures in the temporal pole and fusiform gyrus ipsilateral to the seizure focus. Thus this study confirmed changes in opioid receptor availability in the hours following seizures, suggesting an important role of the opioid system in seizure control. Previous studies performed during reading-induced seizures and absences demonstrated on the contrary decreased [^{11}C]-DPN binding [67, 68]. Taking together the results of these previous studies and the most recent one, the authors suggest that "synaptic opioid levels increase at the time of seizures, leading to a reduction in [^{11}C]-DPN binding, and that this is followed by a gradual recovery of available surface receptors with an overshoot over basal levels which is detected by PET about 8 h after seizures, with a gradual return to normal levels during the interictal phase" [66].

3.8 Markers of inflammation

Translocator protein (TSPO), a marker of neuroinflammation expressed by activated microglial cells, is increased in vitro in surgical samples from patients with TLE. It can be measured in vivo by PET using the novel radioligand [^{11}C]-PBR28. A study of 16 patients with unilateral TLE showed increased uptake of radioactivity ipsilateral to the seizure focus, suggesting increased expression of TSPO [69].

4. Technological developments: PET/MRI

Hybrid tomographs, able to perform in a single imaging session PET and MRI acquisition, called PET/MRI systems, are a new modality with great potential clinical and research applications [70].

PET and MRI are the methods of choice for brain studies, PET providing molecular information (glucose metabolism, receptor imaging) and MRI evaluating a large panel of morphological and functional parameters: for this reason PET/MRI might become the modality of choice in the field of neuroimaging [71]. Indeed, the first prototype tested in humans was a brain-dedicated system [72].

This technological development has needed considerable efforts, to overcome the major challenges of bringing these two image modalities together. The main problem is due to the fact that current PET systems have a detection chain which is based on photomultiplier tubes, which are intrinsically sensitive to magnetic fields. For this reason, the PET/MRI systems replace photomultiplier technology by magnetic field-insensitive avalanche photodiodes or silicon photomultipliers [73, 74]. Alternatively, sequential imaging and proper shielding has been used, in order to minimize magnetic effects on the PET electronics [75, 76]. In addition, the CT component of PET/CT systems is used for correcting the attenuation of photons induced by tissues for PET images. The current PET/MRI systems estimate attenuation using MRI and various segmentation approaches [77, 78].

For hybrid neuroimaging, both brain-dedicated systems as well as whole-body systems have been tested. The first PET/MRI acquisition ever done in humans has been performed on a prototype for simultaneous PET/MRI featuring a PET insert for a standard 3 T MRI scanner (BrainPET; Siemens) [72]. A second dedicated brain system used a shuttle bed-based design, based on separate acquisitions on an ultra-high-field MRI (7 T) and on a PET high-resolution research tomograph (HRRT), on a common bed shifting between the two systems and guaranteeing a common reference system for image coregistration [79]. Both prototypes have been tested in dedicated research environments and no wide clinical application is expected.

Whole-body PET/MRI scanners have recently been introduced on the market for clinical use, about a decade after the commercial introduction of PET/CT. Whole-body systems have a significant advantage over brain dedicated systems, being able to perform both brain and whole-body imaging.

Different designs are adopted by the three commercial solutions available: a non integrated system using a shuttle bed connection by GE Healthcare [80], a sequential system, proposed by Philips Healthcare [81], and a simultaneous system, produced by Siemens Healthcare [82].

MRI, due to its superior soft-tissue contrast, has clear diagnostic advantages over non-contrast-enhanced CT, which is usually coupled to PET in routine brain PET/CT investigations. In addition, avoiding the CT component of PET/CT investigations reduces the total radiation exposure, with relevant advantages in pediatric and young population, representing a relevant proportion of the cases evaluated for refractory epilepsy. As compared with post-hoc fusion, already mentioned (Section 2), hybrid imaging avoids possible misalignements due to different patient positioning and guarantees that both modalities are acquired in the same physiological conditions. Overall, the hybrid design allows obtaining all information in one session, with one sedation/anaesthesia, if required, thus with significant practical advantages for both patients and specialists.

To date, only a few hybrid PET/MRI studies on patients with refractory epilepsy have been reported [81, 83]. One report on six cases studied by sequential PET/MRI hybrid imaging showed that fusion of morphological and functional information allowed the identification of subtle metabolic alterations which could easily have been missed when interpreting the 18F-FDG images alone [81]. The second study demonstrated the feasibility of simultaneous ^{11}C-flumazenil PET and MPRAGE MRI acquisition in one patient with right temporal lobe epilepsy [83].

With the wider diffusion of this new modality, larger investigations are expected, in order to evaluate the advantage of combining the various parameters of MRI (spectroscopy, functional MRI, diffusion studies) with the various molecular targets evaluated by PET. Hybrid PET/MRI, when available, might become the modality of choice for imaging patients in the presurgical evaluation of epilepsy providing multiparametric imaging.

Conclusion

Nuclear medicine imaging techniques have a well established role in the clinical investigation of patients evaluated for presurgical localization of seizure foci. The technological developments, together with the development and wider diffusion of specific molecular tracers, will presumably increase the diagnostic performance of these technologies for a more accurate non-invasive assessment of epileptic patients.

References

1. *Horsley V. An address on the origin and seat of epileptic disturbance: Delivered before the Cardiff Medical Society. Br Med J 1892; 1: 693-696*
2. *So EL, O'Brien TJ. Peri-ictal single-photon emission computed tomography: principles and applications in epilepsy evaluation. Handb Clin Neurol 2012; 107: 425-436*
3. *Rowe CC, Berkovic SF, Austin MC et al. Patterns of postictal cerebral blood flow in temporal lobe epilepsy: qualitative and quantitative analysis. Neurology 1991; 41: 1096-1103*
4. *Dupont P, Van Paesschen W, Palmini A et al. Ictal perfusion patterns associated with single MRI-visible focal dysplastic lesions: implications for the noninvasive delineation of the epileptogenic zone. Epilepsia 2006; 47: 1550-1557*
5. *Lee SK, Lee SY, Yun CH et al. Ictal SPECT in neocortical epilepsies: clinical usefulness and factors affecting the pattern of hyperperfusion. Neuroradiology 2006; 48: 678-684*
6. *Patil S, Biassoni L, Borgwardt L. Nuclear medicine in pediatric neurology and neurosurgery: epilepsy and brain tumors. Semin Nucl Med 2007; 37: 357-381*
7. *O'Brien TJ, So EL, Mullan BP et al. Subtraction ictal SPECT co-registered to MRI improves clinical usefulness of SPECT in localizing the surgical seizure focus. Neurology 1998; 50: 445-454*
8. *Vera P, Kaminska A, Cieuta C et al. Use of subtraction ictal SPECT co-registered to MRI for optimizing the localization of seizure foci in children. J Nucl Med 1999; 40: 786-792*
9. *O'Brien TJ, O'Connor MK, Mullan BP et al. Subtraction ictal SPET co-registered to MRI in partial epilepsy: description and technical validation of the method with phantom and patient studies. Nucl Med Commun 1998; 19: 31-45*
10. *Kurian M, Spinelli L, Delavelle J et al. Multimodality imaging for focus localization in pediatric pharmacoresistant epilepsy. Epileptic Disord 2007; 9: 20-31*
11. *Varrone A, Asenbaum S, Vander Borght T et al. EANM procedure guidelines for PET brain imaging using [18F]FDG, version 2. Eur J Nucl Med Mol Imaging 2009; 36: 2103-2110*
12. *Nelissen N, Van Paesschen W, Baete K et al. Correlations of interictal FDG-PET metabolism and ictal SPECT perfusion changes in human temporal lobe epilepsy with hippocampal sclerosis. Neuroimage 2006; 32: 684-695*
13. *Kumar A, Semah F, Chugani HT, Theodore WH. Epilepsy diagnosis: positron emission tomography. Handb Clin Neurol 2012; 107: 409-424*
14. *Theodore WH, Bhatia S, Hatta J et al. Hippocampal atrophy, epilepsy duration, and febrile seizures in patients with partial seizures. Neurology 1999; 52: 132-136*
15. *Magistretti PJ. Cellular bases of functional brain imaging: insights from neuron-glia metabolic coupling. Brain Res 2000; 886: 108-112*
16. *Carne RP, O'Brien TJ, Kilpatrick CJ et al. MRI-negative PET-positive temporal lobe epilepsy: a distinct surgically remediable syndrome. Brain 2004; 127: 2276-2285*
17. *Wong CH, Bleasel A, Wen L et al. The topography and significance of extratemporal hypometabolism in refractory mesial temporal lobe epilepsy examined by FDG-PET. Epilepsia 2010; 51: 1365-1373*
18. *Lerner JT, Salamon N, Hauptman JS et al. Assessment and surgical outcomes for mild type I and severe type II cortical dysplasia: a critical review and the UCLA experience. Epilepsia 2009; 50: 1310-1335*
19. *Moosa AN, Gupta A, Jehi L et al. Longitudinal seizure outcome and prognostic predictors after hemispherectomy in 170 children. Neurology*

2013; 80: 253-260
20. Theodore WH, Sato S, Kufta CV et al. FDG-positron emission tomography and invasive EEG: seizure focus detection and surgical outcome. Epilepsia 1997; 38: 81-86
21. Salamon N, Kung J, Shaw SJ et al. FDG-PET/MRI coregistration improves detection of cortical dysplasia in patients with epilepsy. Neurology 2008; 71: 1594-1601
22. Madan N, Grant PE. New directions in clinical imaging of cortical dysplasias. Epilepsia 2009; 50(Suppl 9): 9-18
23. Goffin K, Van Paesschen W, Dupont P et al. Anatomy-based reconstruction of FDG-PET images with implicit partial volume correction improves detection of hypometabolic regions in patients with epilepsy due to focal cortical dysplasia diagnosed on MRI. Eur J Nucl Med Mol Imaging 2010; 37: 1148-1155
24. Mauguiere F, Ryvlin P. The role of PET in presurgical assessment of partial epilepsies. Epileptic Disord 2004; 6: 193-215
25. Hammers A. What has positron emission tomography told us about the epileptogenic zone? Rev Neurol (Paris) 2009; 165: 739-741
26. Juhasz C, Asano E, Shah A et al. Focal decreases of cortical $GABA_A$ receptor binding remote from the primary seizure focus: what do they indicate? Epilepsia 2009; 50: 240-250
27. Neuman RS, Thompson PM. Serotonin mediates suppression of focal epileptiform activity induced by noxious stimulation. Epilepsia 1989; 30: 307-313
28. Watanabe K, Minabe Y, Ashby CR, Jr, Katsumori H. Effect of acute administration of various 5-HT receptor agonists on focal hippocampal seizures in freely moving rats. Eur J Pharmacol 1998; 350: 181-188
29. Wada Y, Shiraishi J, Nakamura M, Koshino Y. Role of serotonin receptor subtypes in the development of amygdaloid kindling in rats. Brain Res 1997; 747: 338-342
30. Clinckers R, Smolders I, Meurs A et al. Anticonvulsant action of hippocampal dopamine and serotonin is independently mediated by D and 5-HT receptors. J Neurochem 2004; 89: 834-843
31. Trottier S, Evrard B, Vignal JP et al. The serotonergic innervation of the cerebral cortex in man and its changes in focal cortical dysplasia. Epilepsy Res 1996; 25: 79-106
32. Chugani DC, Chugani HT, Muzik O et al. Imaging epileptogenic tubers in children with tuberous sclerosis complex using alpha-[11C]methyl-L-tryptophan positron emission tomography. Ann Neurol 1998; 44: 858-866
33. Asano E, Chugani DC, Muzik O et al. Multimodality imaging for improved detection of epileptogenic foci in tuberous sclerosis complex. Neurology 2000; 54: 1976-1984
34. Fedi M, Reutens DC, Andermann F et al. alpha-[11C]-Methyl-L-tryptophan PET identifies the epileptogenic tuber and correlates with interictal spike frequency. Epilepsy Res 2003; 52: 203-213
35. Kagawa K, Chugani DC, Asano E et al. Epilepsy surgery outcome in children with tuberous sclerosis complex evaluated with alpha-[11C] methyl-L-tryptophan positron emission tomography (PET). J Child Neurol 2005; 20: 429-438
36. Kumar A, Asano E, Chugani HT. alpha-[(1)(1)C]-methyl-L-tryptophan PET for tracer localization of epileptogenic brain regions: clinical studies. Biomark Med 2011; 5: 577-584
37. Chugani HT, Kumar A, Kupsky W et al. Clinical and histopathologic correlates of 11C-alpha-methyl-L-tryptophan (AMT) PET abnormalities in children with intractable epilepsy. Epilepsia 2011; 52: 1692-1698
38. Juhasz C, Chugani DC, Muzik O et al. In vivo uptake and metabolism of alpha-[11C]methyl-L-tryptophan in human brain tumors. J Cereb Blood Flow Metab 2006; 26: 345-357
39. Fedi M, Reutens D, Okazawa H et al. Localizing value of alpha-methyl-L-tryptophan PET in intractable epilepsy of neocortical origin. Neurology 2001; 57: 1629-1636
40. Natsume J, Kumakura Y, Bernasconi N et al. Alpha-[11C] methyl-L-tryptophan and glucose metabolism in patients with temporal lobe epilepsy. Neurology 2003; 60: 756-761
41. Juhasz C, Chugani DC, Padhye UN et al. Evaluation with alpha-[11C]methyl-L-tryptophan positron emission tomography for reoperation after failed epilepsy surgery. Epilepsia 2004; 45: 124-130
42. Savic I, Lindstrom P, Gulyas B et al. Limbic reductions of 5-HT1A receptor binding in human temporal lobe epilepsy. Neurology 2004; 62: 1343-1351
43. Toczek MT, Carson RE, Lang L et al. PET imaging of 5-HT1A receptor binding in patients with temporal lobe epilepsy. Neurology 2003; 60: 749-756
44. Giovacchini G, Toczek MT, Bonwetsch R et al. 5-HT 1A receptors are reduced in temporal lobe epilepsy after partial-volume correction. J Nucl Med 2005; 46: 1128-1135
45. Liew CJ, Lim YM, Bonwetsch R et al. 18F-FCWAY and 18F-FDG PET in MRI-negative temporal lobe epilepsy. Epilepsia 2009; 50: 234-239
46. Theodore WH, Martinez AR, Khan OI et al. PET of serotonin 1A receptors and cerebral glucose metabolism for temporal lobectomy. J Nucl Med 2012; 53: 1375-1382
47. Theodore WH, Wiggs EA, Martinez AR et al. Serotonin 1A receptors, depression, and memory in temporal lobe epilepsy. Epilepsia 2012; 53: 129-133
48. Merlet I, Ryvlin P, Costes N et al. Statistical parametric mapping of 5-HT1A receptor binding in temporal lobe epilepsy with hippocampal ictal onset on intracranial EEG. Neuroimage 2004; 22: 886-896
49. Merlet I, Ostrowsky K, Costes N et al. 5-HT1A receptor binding and intracerebral activity in temporal lobe epilepsy: an [18F]MPPF-PET study. Brain 2004; 127: 900-913
50. Didelot A, Ryvlin P, Lothe A et al. PET imaging of brain 5-HT1A receptors in the preoperative evaluation of temporal lobe epilepsy. Brain 2008; 131: 2751-2764
51. Elsinga PH, Hendrikse NH, Bart J et al. Positron emission tomography studies on binding of central nervous system drugs and P-glycoprotein function in the rodent brain. Mol Imaging Biol 2005; 7: 37-44
52. Depaulis A, Vergnes M, Marescaux C. Endogenous control of epilepsy: the nigral inhibitory system. Prog Neurobiol 1994; 42: 33-52
53. Biraben A, Semah F, Ribeiro MJ et al. PET evidence for a role of the basal ganglia in patients with ring chromosome 20 epilepsy. Neurology 2004; 63: 73-77
54. Bouilleret V, Semah F, Biraben A et al. Involvement of the basal ganglia in refractory epilepsy: an 18F-fluoro-L-DOPA PET study using 2 methods of analysis. J Nucl Med 2005; 46: 540-547
55. Werhahn KJ, Landvogt C, Klimpe S et al. Decreased dopamine D2/D3-receptor binding in temporal lobe epilepsy: an [18F]fallypride PET study. Epilepsia 2006; 47: 1392-1396
56. Fedi M, Berkovic SF, Scheffer IE et al. Reduced striatal D1 receptor binding in autosomal dominant nocturnal frontal lobe epilepsy. Neurology 2008; 71: 795-798
57. Ciumas C, Wahlin TB, Espino C, Savic I. The dopamine system in idiopathic generalized epilepsies: identification of syndrome-related changes. Neuroimage 2010; 51: 606-615
58. Odano I, Varrone A, Savic I et al. Quantitative PET analyses of regional [11C]PE2I binding to the dopamine transporter-application to juvenile

myoclonic epilepsy. Neuroimage 2012; 59: 3582-3593

59. *Ahmed I, Bose SK, Pavese N et al. Glutamate NMDA receptor dysregulation in Parkinson's disease with dyskinesias. Brain 2011; 134: 979-986*
60. *Kumlien E, Hartvig P, Valind S et al. NMDA-receptor activity visualized with (S)-[N-methyl-11C]ketamine and positron emission tomography in patients with medial temporal lobe epilepsy. Epilepsia 1999; 40: 30-37*
61. *Gallezot JD, Bottlaender M, Gregoire MC et al. In vivo imaging of human cerebral nicotinic acetylcholine receptors with 2-18F-fluoro-A-85380 and PET. J Nucl Med 2005; 46: 240-247*
62. *Picard F, Bruel D, Servent D et al. Alteration of the in vivo nicotinic receptor density in ADNFLE patients: a PET study. Brain 2006; 129: 2047-2060*
63. *Bauer A, Langen KJ, Bidmon H et al. 18F-CPFPX PET identifies changes in cerebral A1 adenosine receptor density caused by glioma invasion. J Nucl Med 2005; 46: 450-454*
64. *Simmons ML, Chavkin C. Endogenous opioid regulation of hippocampal function. Int Rev Neurobiol 1996; 39: 145-196*
65. *Neumaier JF, Chavkin C. Release of endogenous opioid peptides displaces [3H]diprenorphine binding in rat hippocampal slices. Brain Res 1989; 493: 292-302*
66. *Hammers A, Asselin MC, Hinz R, et al. Upregulation of opioid receptor binding following spontaneous epileptic seizures. Brain 2007; 130: 1009-1016*
67. *Bartenstein PA, Duncan JS, Prevett MC et al. Investigation of the opioid system in absence seizures with positron emission tomography. J Neurol Neurosurg Psychiatry 1993; 56: 1295-1302*
68. *Koepp MJ, Richardson MP, Brooks DJ, Duncan JS. Focal cortical release of endogenous opioids during reading-induced seizures. Lancet 1998; 352: 952-955*
69. *Hirvonen J, Kreisl WC, Fujita M et al. Increased in vivo expression of an inflammatory marker in temporal lobe epilepsy. J Nucl Med 2012; 53: 234-240*
70. *Ratib O, Beyer T. Whole-body hybrid PET/MRI: ready for clinical use? Eur J Nucl Med Mol Imaging 2011; 38: 992-995*
71. *Garibotto V, Forster S, Haller S et al. Molecular Neuroimaging with PET/MRI. Clinical and Translational Imaging 2013; 1 : 53-63*
72. *Schlemmer HP, Pichler BJ, Schmand M et al. Simultaneous MR/PET imaging of the human brain: feasibility study. Radiology 2008; 248: 1028-1035*
73. *Judenhofer MS, Wehrl HF, Newport DF et al. Simultaneous PET-MRI: a new approach for functional and morphological imaging. Nat Med 2008; 14: 459-465*
74. *Catana C, Wu Y, Judenhofer MS et al. Simultaneous acquisition of multislice PET and MR images: initial results with a MR-compatible PET scanner. J Nucl Med 2006; 47: 1968-1976*
75. *Beyer T, Pichler B. A decade of combined imaging: from a PET attached to a CT to a PET inside an MR. Eur J Nucl Med Mol Imaging 2009; 36(Suppl 1): S1-2*
76. *Zaidi H, Del Guerra A. An outlook on future design of hybrid PET/MRI systems. Med Phys 2011; 38: 5667-5689*
77. *Zaidi H, Ojha N, Morich M et al. Design and performance evaluation of a whole-body Ingenuity TF PET-MRI system. Phys Med Biol 2011; 56: 3091-3106*
78. *Catana C, van der Kouwe A, Benner T et al. Toward implementing an MRI-based PET attenuation-correction method for neurologic studies on the MR-PET brain prototype. J Nucl Med 2010; 51: 1431-1438*
79. *Cho ZH, Son YD, Choi EJ et al. In-vivo human brain molecular imaging with a brain-dedicated PET/MRI system. MAGMA 2013; 26: 71-79*
80. *Veit-Haibach P, Kuhn FP, Wiesinger F et al. PET-MR imaging using a tri-modality PET/CT-MR system with a dedicated shuttle in clinical routine. MAGMA 2012; 26: 25-35*
81. *Garibotto V, Heinzer S, Vulliemoz S et al. Clinical applications of hybrid PET/MRI in neuroimaging. Clin Nucl Med 2013; 38: e13-18*
82. *Drzezga A, Souvatzoglou M, Eiber M et al. First clinical experience with integrated whole-body PET/MR: comparison to PET/CT in patients with oncologic diagnoses. J Nucl Med 2012; 53: 845-855*
83. *Herzog H, Langen KJ, Weirich C et al. High resolution BrainPET combined with simultaneous MRI. Nuklearmedizin 2011; 50: 74-82*

Address for correspondence:
Dr. Valentina Garibotto , MD
Service de Médecine Nucléaire
et Imagerie Moléculaire
Département d'Imagerie et des Sciences de
l'Information Médicale
Hôpitaux Universitaires de Genève
CH 1205 Genève
Tel. 0041 79 5534459
Fax 0041 223727169
valentina.garibotto@hcuge.ch

Electric and Magnetic Source Imaging of Epileptic Activity

Pierre Mégevand[1,2] and Serge Vulliémoz[1]

[1] EEG and Epilepsy Unit and Functional Brain Mapping Laboratory, Department of Clinical Neurosciences, Geneva University Hospitals and Faculty of Medicine, Geneva, Switzerland

[2] Laboratory for Multimodal Human Brain Mapping, Hofstra North Shore LIJ School of Medicine, Manhasset, NY, USA

Summary

Electroencephalography (EEG) plays a central role in confirming the diagnosis of epilepsy and in characterizing the electro-clinical epilepsy syndrome. Additionally, EEG and magnetoencephalography (MEG) can be used to image the functional activity of the brain with millisecond resolution. Recent progresses in recording systems now allow easily measuring the electromagnetic field generated by cerebral activity using hundreds of sensors spread all over the scalp. Together with these advances in hardware, modern analytic methods that take into consideration the cerebral anatomy of individual patients and account for the involvement of distributed cortical areas have greatly increased the spatial accuracy of electric and magnetic source imaging. These techniques are most useful in the evaluation of patients with drug-resistant focal seizures who are potential candidates for epilepsy surgery. Localizing the source of interictal epileptic spikes recorded by high-density EEG or MEG is a reliable marker of the epileptogenic zone, the brain region whose resection leads to seizure freedom. The accuracy of electric and magnetic source imaging seems higher than that of positron electron tomography (PET) or single-photon emission computed tomography (SPECT) and is on par with that of structural magnetic resonance imaging. Electromagnetic source imaging is also increasingly used to define the neural networks involved in epileptogenesis. Electromagnetic source imaging should be part of the presurgical evaluation of all patients considering epilepsy surgery.

Epileptologie 2013; 30: 122 – 131

Key words: Electroencephalography, magnetoencephalography, functional neuroimaging, epilepsy

Imagerie de source électrique et magnétique de l'activité épileptique

L'électroencéphalographie (EEG) joue un rôle central pour confirmer un diagnostic d'épilepsie et pour caractériser le syndrome épileptique électro-clinique. L'EEG et la magnétoencéphalographie (MEG) peuvent également être utilisées pour localiser l'activité fonctionnelle du cerveau avec une résolution temporelle de l'ordre de la milliseconde. Il est maintenant facile d'enregistrer le champ électromagnétique généré par l'activité cérébrale au moyen de centaines de senseurs répartis sur l'ensemble du scalp. En plus de ces progrès techniques, les méthodes d'analyse modernes, qui incluent l'anatomie cérébrale de chaque patient et qui tiennent compte de l'activité de régions cérébrales étendues, ont nettement amélioré la précision spatiale de l'imagerie de source électrique et magnétique. Ces techniques sont très utiles dans le contexte de l'évaluation de patients souffrant d'épilepsie focale pharmaco-résistante candidats à la chirurgie de l'épilepsie. La localisation de la source des pointes interictales épileptiques est un marqueur fiable de la zone épileptogène, dont la résection supprime les crises épileptiques. La précision de l'imagerie de source électromagnétique semble meilleure que celle de la tomographie par émission de positrons (PET) ou de la tomographie d'émission monophotonique (SPECT) et égale à celle de l'imagerie par résonance magnétique. De plus, l'imagerie de source électromagnétique permet de délimiter les réseaux neuraux qui participent à la génération des crises épileptiques. L'imagerie de source électromagnétique devrait faire partie du bilan préopératoire de tout patient candidat à une chirurgie de l'épilepsie.

Mots clés : Electroencéphalographie, magnétoencéphalographie, neuroimagerie fonctionnelle, épilepsie

Elektrische und magnetische Quellenlokalisation der epileptischen Aktivität

Die Elektroenzephalographie (EEG) spielt eine zentrale Rolle um eine Epilepsie zu diagnostizieren und das epileptische Syndrom zu charakterisieren. Das EEG und die Magnetoenzephalographie (MEG) können die Aktivität des Gehirnes darstellen und zwar mit einer Präzision von Millisekunden. Heuzutage kann man das durch die Hirnaktivität generierte elektromagnetische Feld mit Hunderten von Sensoren auf dem ganzen Kopf relativ einfach registrieren. Neben diesen technischen Fortschritten erlauben moderne Analysemethoden die Darstellung der elektrischen Aktivität von breiten kortikalen Regionen unter Berücksichtigung der individuellen Hirnanatomie, so dass die spatiale Auflösung der elektrischen und magnetischen Bildgebung deutlich verbessert ist. Diese Techniken sind sehr hilfreich in der prächirurgischen Evaluation von Patienten mit pharmako-resistenter Epilepsie. Die Quellenlokalisierung der interiktalen Spitzenpotenziale ist ein zuverlässiger Marker der epileptogenen Zone, deren Resektion zur Anfallsfreiheit führt. Die Präzision der elektromagnetischen Quellenbildgebung scheint höher zu sein als die von nuklearmedizinischen Methoden (PET/SPECT) und gleich gut wie jene der strukturellen Kernspintomographie. Ausserdem kann die Quellenlokalisation die epileptischen neuronalen Netzwerke darstellen, welche zur epileptischen Aktivität beitragen. Die elektromagnetische Quellenbildgebung sollte für alle prächirurgisch evaluierten Patienten eine Routineuntersuchung werden.

Schlüsselwörter: Elektroenzephalographie, EEG, Magnetoenzephalographie, funktionnelle Bildgebung, Epilepsie

EEG and MEG: From Epileptic Focus to Brain Networks

What are electroencephalography (EEG) and magnetoencephalography (MEG) doing in a collection of reviews devoted to advanced imaging in epilepsy? After all, EEG produces squiggly lines (at least to the uninitiated), not pictures of the brain. What's more, one of the first things that residents embarking on clinical neurophysiology training are told is that EEG traces do not simply reflect the activity of the brain area lying directly under the corresponding electrode. So how could EEG ever be expected to localize epileptic activity with the high spatial resolution reached by legitimate neuroimaging methods such as MRI? Then again, if functional neuroimaging using EEG were at all possible, it would be a highly valuable method in epilepsy thanks to its millisecond temporal resolution – several orders of magnitude better than functional MRI.

MEG records the magnetic fields produced by neural activity that diffuse out of the head (whereas EEG measures the electric potential at the scalp surface). Because these magnetic fields are very small (approximately eight orders of magnitude smaller than the magnetic field of the earth), high amplification and strict shielding from outside interference are required. MEG systems are thus large machines that take up a dedicated shielded room. MEG and EEG are sensitive to different physical features of neural activity, and the two techniques can therefore bring complementary information. The relative strengths and weaknesses of each modality will be discussed throughout the article.

Here, we recapitulate how electromagnetic neuroimaging using EEG (Electric Source Imaging, ESI) and Magnetic Source Imaging (MSI) has in fact become a reality in recent years, thanks to developments both in hardware (recording systems) and software (analytic approaches), and how it can crucially inform clinical practice in epilepsy [1, 2].

How Does Electromagnetic Neuroimaging Work?

The inverse problem

Why is it actually difficult to localize the neural generators of EEG signals recorded at the surface of the head (the so-called inverse problem)? The physics of electromagnetism state that any given configuration of the voltage field at the surface of the head could theoretically be generated by an infinite number of configurations of the potential generators. Not all of these configurations are biologically or medically realistic, however, and the practical approach to solving the inverse problem is therefore to set constraints on what the potential solution may be.

The source space

One of these constraints relies on our knowledge of where epileptic EEG signals are generated, i.e. by neurons in the cortex [3]: the generators of any given surface voltage field should therefore lie in the cortical grey matter (including the hippocampus and amygdala), but not in the basal ganglia or thalamus and certainly not in the white matter or the cerebral ventricles. Feeding the patient's own brain anatomy into the inverse solution improves the accuracy of ESI by taking into account individual anatomical variations as well as existing cerebral lesions or malformations [4, 5].

Dipoles vs. distributions

Another constraint concerns the number of sources: some inverse solutions limit the numbers of generators to one or a few point-like sources (i.e. equivalent dipoles), while others attempt to estimate cerebral activity at thousands of points distributed within the brain volume (distributed solutions). Equivalent dipole modelling has intuitive appeal in the context of epilepsy: we like to think of interictal spikes as being generated by a single, well-delineated patch of cortex. The reality is more complex, however: spikes are often generated within a spatially widespread epileptic network, and propagation from the initial source of the spike to other parts of the network happens within milliseconds of its onset [6, 7]. Moreover, dipole localisation is artificially in the "centre of mass" of the region that it represents. Therefore, the orientation of the dipole is as important as its localisation in interpreting such source analysis, and distance measurements between a dipole and a lesion or an intracranial electrode do not really make sense. Distributed inverse solutions are therefore needed if we want to take into consideration the whole epileptogenic network. Multiple algorithms for distributed inverse solutions have been developed, each incorporating specific a priori mathematical and biophysical assumptions. They have been the subject of several recent reviews that detail these points [2, 8 - 11].

Number and position of the sensors

An important factor in determining how well ESI/MSI performs is how precisely and completely the electromagnetic field is sampled at the head surface. Using EEG, increasing the number of electrodes from a standard, 31-electrode montage to 123 electrodes significantly improves the localization of interictal spikes [12]. It is also crucial to sample the electric field below the top of the ears, as routine EEG montages that totally ignore this region cause generators in the inferior and medial temporal lobes to be significantly displaced upwards [13]. Recently developed EEG caps with more than 200 sensors can now easily be applied in minutes, making high-density EEG readily available in the clinical neurophysiology laboratory. Appropriately-sized caps are also available for infants and children. High density of sensors is made particularly relevant by the fact that the ratio between skull and brain conductivity has recently been shown to be higher than previously estimated (1:20 instead of 1:80) [14], so that a high spatial sampling of scalp EEG is definitely more than oversampling of a field smoothened by its passage through the skull. This is naturally even truer in children who show higher skull conductivity than adults. Current MEG systems comprise around 300 sensors to record and image neuronal activity using the same analytic principles that apply to ESI.

Methodological differences between ESI and MSI

Magnetoencephalography and electroencephalography both measure cerebral activity in real time, but since they measure different physical properties of this activity, there are differences in their sensitivity to different configurations of neural generators. Magnetic fields diffuse across the skull and scalp with essentially no distortion, whereas electrical potentials are distorted by variations of skull thickness, cranial foramina, previous craniotomies, etc. [15]. Thus, there is no such thing as a "breach rhythm" in MEG. Also for this reason, MSI is often claimed to be more accurate than ESI in detecting superficial, neocortical sources [16]. However, MEG is only sensitive to the activity of neurons oriented tangentially (i.e. parallel to the skull surface and the MEG sensors, as found in sulcal banks) and not to that of radially-oriented neurons (as found in gyral crowns and fundi). By contrast, EEG is able to record the activity of neurons regardless of their orientation [17]. Another clinically important difference is that MEG is less sensitive to deep sources than EEG [11]. Finally, MEG sensors are affixed to the machine and not to the patient's head, which makes MEG exquisitely sensitive to patient motion. As a result, MEG is impractical for recordings longer than a couple of hours or sleep studies and in young children or non-cooperative patients.

What Can ESI and MSI Image in Epilepsy?

Since ESI is based on the exact same signal as the routine EEG, everything that is recorded by EEG can be subjected to ESI. This ranges from normal spontaneous brain rhythms [18] through sensory-evoked and event-related activity [19] to epileptic activity.

At the EEG and Epilepsy unit of Geneva University Hospitals, we systematically perform high-density EEG recordings as part of the non-invasive evaluation of adult and paediatric patients considered for epilepsy surgery. Our approach to ESI is illustrated in **Figure 1**.

ESI/MSI of interictal spikes

Most studies of ESI and MSI in epilepsy to date focused on localising interictal spikes rather than on seizures. The justification for this lies in their respective nature: spikes can be averaged together in order to improve the signal-to-noise ratio, are usually more frequent than seizures, and their spatiotemporal dynamics are simpler [20]. As previously mentioned, however, interictal spikes do not remain confined to a single neuronal population in a single cortical patch; rather, they propagate within milliseconds to involve cortical areas away from the initial generator [6]. The temporal resolution of EEG and MEG allows disentangling the generation of a spike from its propagation. In order to im-

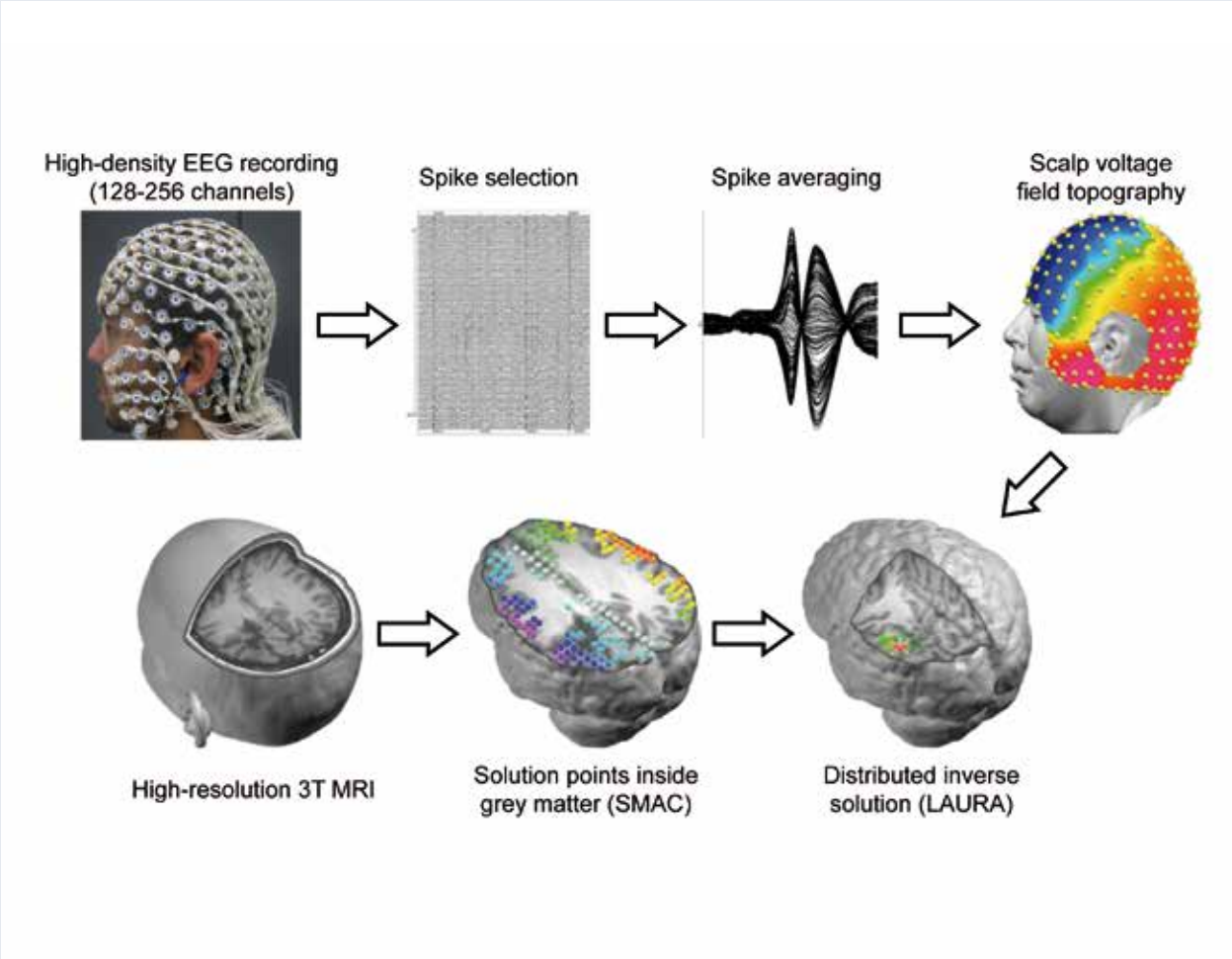

Figure 1: Electric Source Imaging of interictal epileptic spikes. Upper line: high-density EEG is recorded. Spikes are identified by visual analysis and averaged together to improve the signal-to-noise ratio. The topography of the voltage field on the scalp is mapped. Lower line: the patient's own high-resolution MRI is used to define the source space for the inverse solution algorithm (Spherical Model with Anatomical Constraints, SMAC; [4]). A distributed inverse solution (Local AUtoRegressive Average, LAURA; [21]) is used to localize the source of the surface voltage field.

age the initial generators of a spike, it is recommended to perform the ESI around the middle of the upslope of the spike rather than at its peak [7].

ESI/MSI of seizure onsets

Ictal activity can also be localized by ESI [22 - 24]. The procedure is generally applied during the very first seconds around the ictal onset, both because we are more interested in localizing the cortical area where a seizure begins than its potentially multiple and widespread propagation areas, and also because EMG artefacts due to motor activity during the seizure often obscure the EEG so much as to make ESI impossible after a few seconds. Although adequate validation of its accuracy and clinical usefulness is yet lacking, ictal-onset ESI may well find a place in the arsenal of clinical neurophysiologists. High-density EEG caps that allow recording for longer than 24 hours, including while sleeping, will likely increase the number of seizures that are captured and amenable to ESI.

Imaging the ictal onset using MSI has also been reported in a few cases where seizures were serendipitously captured during an MEG recording [25]. However, as mentioned above, MEG machines are very sensitive to motion of the patient. Therefore, anything more than minor motor activity during a seizure will interrupt the recording.

How Accurate Is ESI/MSI?

Here, we focus on clinically relevant measurements of accuracy in the context of epilepsy and leave aside modelling approaches and experimental studies performed in other contexts. Ideally, assessing the accuracy of ESI in epilepsy should be performed by measurin

how far the ESI/MSI lands from the actual epileptic focus (measurement error). This prompts two questions: first, what exactly is an epileptic focus? Second, how do we know for sure where this focus is in the brain, i.e. what is our gold standard to compare ESI against?

In the zone

An approach to defining the "epileptic focus" involves identifying several interrelated, but not necessarily overlapping, zones participating in the electroclinical picture of epilepsy [26]. Of these zones, the epileptogenic zone, a theoretical construct defined by the cortical area whose complete resection is necessary to free the patient from seizures, is the one that we want to localize. However, the epileptogenic zone cannot be delineated preoperatively, and other zones therefore need to be used as surrogates. These include the irritative zone, the cortical area that produces interictal spikes, defined most precisely by intracranial EEG; the ictal onset zone, from where seizures originate, studied by intra-cranial EEG (and also by ictal single-photon emission computed tomography, SPECT); and the epileptogenic lesion, the morphological abnormality (when present) that generates the seizures, revealed by MRI. If there is a single MRI lesion that may plausibly cause the epilepsy (e.g. unilateral hippocampal sclerosis or focal cortical dysplasia), then it is a good approximation to the epileptogenic zone [27]. In cases where there are either no lesion or multiple lesions on the MRI, however, the seizure onset zone is generally thought to be the better surrogate [28].

Irritative zone and seizure onset zone

It becomes clear that ESI/MSI of interictal spikes in fact attempts to localize the irritative zone, and that the clinical usefulness of this technique depends both on its absolute accuracy and on the value of the irritative zone as a surrogate for the seizure onset and epileptogenic zones. A few studies have shown that the irritative zone indeed often co-localises with the seizure onset zone [29 - 31] (**Figure 2A**). In fact, resecting the cortical areas that lie outside the margins of the seizure onset zone but display irritative activity has been associated with a more favourable post-operative outcome [32]. Of course, there are cases when there is an extended or multifocal irritative zone, not all of which participate in seizure generation (so-called secondary irritative zone [33]) (**Figure 2B**). The results of ESI/MSI, like those of any investigation, must therefore always be integrated within the patient's overall clinical, neurophysiological and radiological picture, in order to assess its reliability in estimating the epileptogenic zone.

Accuracy of ESI/MSI with respect to intracranial EEG

Few studies have assessed the accuracy of ESI or MSI in large groups of patients with diverse epilepsy types using intracranial EEG as a gold standard. Co-localization at a sub-lobar level is often reported as a criterion for accuracy rather than absolute measurement error; sub-lobar borders are defined partly arbitrarily according to anatomical landmarks, and sub-lobar regions can differ widely in size and shape. Using MSI, Agirre-Arrizubieta et al. [34] reported concordant localization in 90% of lateral temporal spikes, 80% of interhemispheric and peri-central spikes, 60% of superior frontal spikes, 40% of orbitofrontal spikes, and 0% of medial temporal spikes. Knowlton et al. [35] found the concordance between MSI and the seizure onset zone to be about 80% in patients with lateral temporal lobe epilepsy and 45% in those with medial temporal lobe or extratemporal lobe epilepsy. The same group found that the performance of MSI was on average similar to that of PET and ictal SPECT [36]. Overall, findings from these studies suggest that MSI performs better when the epileptic focus is not in the medial temporal lobe, likely because of the difficulties of MEG in recording the activity of deep-seated brain structures [11].

Accuracy of ESI/MSI with respect to resection and post-operative outcome

Another approach to assessing the accuracy of ESI is to compare its result with the resected brain volume as a function of post-operative outcome: ESI is deemed accurate if it falls within the resection and if the patient is subsequently seizure-free. This approach makes sense in the clinical context of epilepsy surgery; its main drawback is that the resection will always include normal brain tissue (sometimes a considerable volume of it) surrounding the epileptogenic zone, and that the ESI may well lie centimetres away from the epileptogenic zone and still be included in the resection. In the largest study on the performance of ESI in epilepsy surgery so far, performed by the EEG and epilepsy unit of Geneva University Hospitals, the sensitivity of ESI was 84% and its specificity 88% [37]. The accuracy of ESI was further highlighted by the finding that it performed at least as well, and often better, than the more established structural MRI, PET and SPECT. Importantly, ESI performed as well for patients with temporal lobe epilepsy as it did for patients with extratemporal lobe epilepsy [37]. That study also underlined the importance of an adequate sampling of the scalp electrical potential field: when ESI was performed on the standard, 32-channel EEG recordings instead of the 128- or 256-channel high-density EEG systems, the accuracy of ESI fell significantly (sensitivity and specificity around 60%).

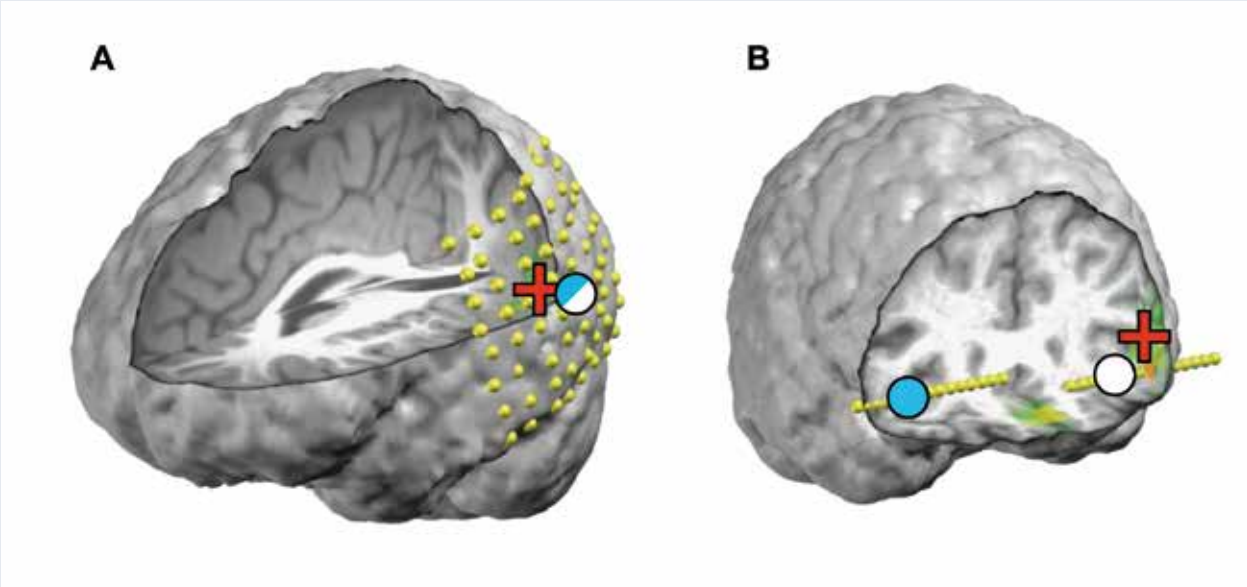

Figure 2: Accuracy of ESI of interictal spikes with intracranial EEG as the gold standard
A: Successful localization of the irritative zone and of the seizure onset zone. In this 15-year-old female patient with tuberous sclerosis, the ESI maximum (red cross) of interictal spikes pointed towards the left angular gyrus. Intracranial EEG showed that both spikes and seizures were generated in the left inferior parietal lobule. The white and blue circle shows the intracranial electrode nearest the ESI maximum that was involved in both the irritative and seizure onset zones.
B: Successful localization of the irritative zone, but unsuccessful localization of the seizure onset zone. This 51-year-old female patient had previously undergone a right frontal resection for a focal cortical dysplasia, which had failed to bring seizure freedom. She had bilateral independent frontal interictal abnormalities. Ictal scalp video-EEG suggested that the seizures still originated from the anterior right hemisphere, but PET and SPECT were non-contributive, and neuropsychological testing found deficits of verbal memory, suggesting left-sided temporal dysfunction. During the high-density EEG, only left-sided spikes were recorded. Intracranial EEG with bilateral frontal and temporal stereotaxic electrodes was therefore performed. The ESI maximum (red cross) lay close to the left frontal irritative zone revealed by intracranial EEG (white circle). All seizures, however, originated from the right frontal lobe (blue circle). In this case, consideration of the electro-clinical pattern and other imaging tools strongly suggest that the spike recorded for ESI is not representative of the seizure onset and the epileptogenic zone. This underlies the importance of integrating ESI with other clinical and imaging data.

Influence of ESI/MSI on surgical planning

The influence of ESI or MSI results on the strategy for implanting intracranial electrodes has been assessed in two MEG studies where the implantation strategy was established twice for each patient: first after reviewing the results of all investigations except MSI, and then again after showing the results of MSI [38, 39]. MSI led to changes in the implantation strategy in 23% to 33% of cases, indicating that this technique brings non-redundant information to a significant proportion of patients who have already undergone multiple non-invasive testing modalities. Findings of a positive association between the inclusion of the ESI or MSI result in the resection and seizure freedom ([37]; see also [40 - 42]) also suggest that the results of ESI or MSI should be taken into account when defining the strategy for resective surgery.

So which one is better: ESI or MSI?

This remains a controversial issue. The ultimate test, where the accuracy of ESI and MSI would be compared against each other using simultaneously recorded interictal spikes, with similar numbers of sensors and head coverage, and with simultaneously acquired intracranial EEG data as the gold standard, has yet to be published. In the interim, most of the attempts at comparing the two techniques suffer from shortcomings that limit the strength of the conclusions that can be drawn from them [11]. For instance, comparing high-density MEG systems against (at most) moderate-resolution EEG recordings artificially tips the balance in favour of MEG [43, 44]. In any case, more importantly than establishing which technique beats the other, it would be more beneficial for patients considering epilepsy surgery to ensure that at least one of the techniques (with state-of-the-art, clinically validated acquisition and analysis strategies) is available to them.

From Source Localisation to Network Analysis

As stated above, the precise localisation of the generators of epileptic activity is of particular relevance for patients who are candidates for epilepsy surgery. However, despite the fact that a very focal cortical resection can lead to seizure freedom, consistent results of several studies using different mapping techniques strongly support the concept that epilepsy is a condition generated by abnormal brain networks and affecting large-scale brain networks, rather than the result of a very focal unique dysfunctional patch of cortex. Scalp EEG [45], intracranial EEG [33], MEG [46], functional MRI [47] and simultaneous EEG-fMRI [48] have all revealed large-scale often bi-hemispheric functional alterations in relation to epileptic activity. Structural imaging such as tractography [49] or cortical volume studies [50] also support this network-based approach. The understanding of such network dysfunctions requires not only to localise the affected network nodes, but also to characterise the interdependencies and flow of information within the network. This can be done with several methods of "functional connectivity". The temporal resolution of EEG and MEG makes them particularly adapted to study the fast-changing dynamics of the connectivity between the network sources. Granger

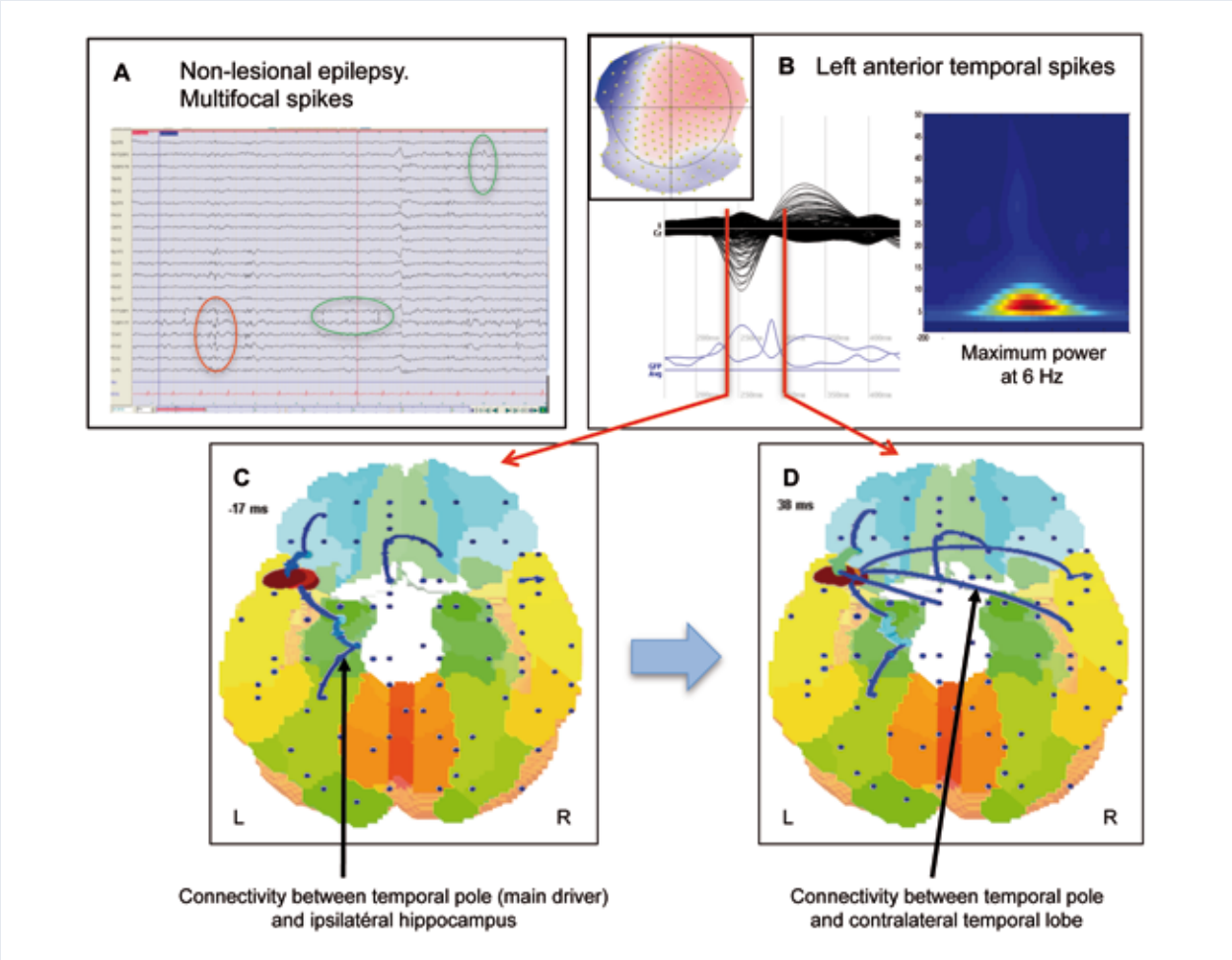

Figure 3: Directed connectivity in a patient with temporal lobe epilepsy using high-density EEG.
A: Temporally independent spikes in the left anterior temporal (red), left posterior temporal and right temporal regions (green).
B: The averaged left anterior temporal spike and the corresponding scalp voltage topography are calculated. The frequency with maximal power (6Hz) is identified. The directed brain connectivity related to the interictal activity can then be estimated for this major frequency for 82 cortical regions based on an atlas (shown in C and D). The connectivity calculation is time-varying so that changes of the connectivity across time during the epileptic spike can be investigated, given the high temporal resolution of EEG.
C: Transverse view of the regions of interest at the level of the temporal lobe. At spike onset, the main outflow of information (dark red spot) estimated by connectivity analysis is in the temporal pole (red spot) and has strong connections (arrows) with the anterior and posterior temporal medial structures.
D: At a later time point there is strong connectivity with the contralateral temporal lobe.
The region of highest outflow was resected and the patient is seizure-free without spike on the post-operative EEG. The connectivity pattern could explain the multifocality of the interictal spikes.

causality allows inferring the causal relationships between the signals of two regions by looking at how much the signal of one region can be reliably predicted knowing the previous values of the other signal (i.e. how much transfer of information, or directed causality, is occurring between the two regions). This approach has been applied to MEG data in a small case series of patients with focal epilepsy and found that the regions contributing most to the outflow of neuro-electrical information were concordant with the epileptogenic regions [46]. Moreover, connectivity between affected regions seems to be related to disease duration [51]. We are currently developing and using functional connectivity analysis of high density EEG and ESI to map the major sources of information ("outflow" = epileptogenic zone ?) and their connectivity in focal epilepsy, which will provide additional information for managing surgical candidates, particularly when multifocal epileptic activity is recorded on the scalp (**Figure 3**).

Why Is ESI/MSI Not Universal? Overcoming Barriers to Their Use in Clinical Routine

Given the accuracy of ESI and MSI and their proven usefulness in the workup of candidates for epilepsy surgery, one may wonder why these techniques have not yet been routinely adopted. We suspect that there are several potential barriers to this, all of which can be remediated. First, the clinicians who routinely work with epileptic patients need to be aware of the techniques and of the potential clinical benefits that they can bring to the patients. However, ESI and MSI still lie on the margin of the curriculum of clinical neurophysiology residents or EEG technicians. This could be remediated by integrating ESI and MSI in the teaching curriculum. Second, learning how to perform ESI or MSI analysis requires adequate training so that the technique can yield its full potential. Appropriately trained personnel can process high-density EEG or MEG recordings and generate ESI or MSI in one to two hours, a relatively small temporal investment given the potential clinical benefits. Fourth, the cost of the equipment may be more of an issue for MEG, where the machine, its environment and the support team cost several million dollars, while the price of acquiring and maintaining a high-density EEG system is at least one order of magnitude lower, which makes it readily affordable for most hospitals in the Western world.

To conclude, integrating ESI or MSI in the routine non-invasive workup of candidates for epilepsy surgery is feasible and is likely to provide significantly higher accuracy in the delineation of the suspected epileptogenic zone, and ultimately meaningful improvement in clinical outcomes.

References

1. *Michel CM, Murray MM. Towards the utilization of EEG as a brain imaging tool. Neuroimage 2012; 61: 371-385*
2. *Kaiboriboon K, Lüders HO, Hamaneh M et al. EEG source imaging in epilepsy – practicalities and pitfalls. Nat Rev Neurol 2012; 8: 498-507*
3. *Brandeis D, Michel C, Amzica F. From neuronal activity to scalp potential fields. In: Michel CM, Koenig T, Brandeis D et al. (eds): Electrical Neuroimaging. Cambridge: Cambridge University Press, 2009: 1-24*
4. *Spinelli L, Andino SG, Lantz G et al. Electromagnetic inverse solutions in anatomically constrained spherical head models. Brain Topogr 2000; 13: 115-125*
5. *Brodbeck V, Lascano AM, Spinelli L et al. Accuracy of EEG source imaging of epileptic spikes in patients with large brain lesions. Clin Neurophysiol 2009; 120: 679-685*
6. *Alarcon G, Guy CN, Binnie CD et al. Intracerebral propagation of interictal activity in partial epilepsy: implications for source localisation. J Neurol Neurosurg Psychiatry 1994; 57: 435-449*
7. *Lantz G, Spinelli L, Seeck M et al. Propagation of interictal epileptiform activity can lead to erroneous source localizations: A 128-channel EEG mapping study. J Clin Neurophysiol 2003; 20: 311-319*
8. *Michel CM, He B. EEG Mapping and source imaging. In: Schomer DL, Lopes Da Silva FH (eds): Niedermeyer's Electroencephalography. Basic Principles, Clinical Applications, and Related Fields. Philadelphia, PA: Lippincott Williams & Wilkins, 2011: 1179-1202*
9. *Pascual-Marqui RD, Sekihara K, Brandeis D et al. Imaging the electric neuronal generators of EEG/MEG. In: Michel CM, Koenig T, Brandeis D et al. (eds): Electrical Neuroimaging. Cambridge: Cambridge University Press, 2009: 49-78*
10. *Michel CM, Murray MM, Lantz G et al. EEG source imaging. Clin Neurophysiol 2004; 115: 2195-2222*
11. *Plummer C, Harvey AS, Cook M. EEG source localization in focal epilepsy: where are we now? Epilepsia 2008; 49: 201-218*
12. *Lantz G, Grave de Peralta R, Spinelli L et al. Epileptic source localization with high density EEG: how many electrodes are needed? Clin Neurophysiol 2003; 114: 63-69*
13. *Sperli F, Spinelli L, Seeck M et al. EEG source imaging in pediatric epilepsy surgery: a new perspective in presurgical workup. Epilepsia 2006; 47: 981-990*
14. *Oostendorp TF, Delbeke J, Stegeman DF. The conductivity of the human skull: results of in vivo and in vitro measurements. IEEE Trans Biomed Eng 2000; 47: 1487-1492*
15. *Hämäläinen M, Hari R, Ilmoniemi RJ et al. Magnetoencephalography – theory, instrumentation, and applications to noninvasive studies of the working human brain. Rev Mod Physics 1993; 65: 413*
16. *Ebersole JS. Magnetoencephalography/magnetic source imaging in the assessment of patients with epilepsy. Epilepsia 1997; 38(Suppl 4): S1-5*
17. *Ahlfors SP, Han J, Belliveau JW, Hämäläinen MS. Sensitivity of MEG and EEG to source orientation. Brain Topogr 2010; 23: 227-232*
18. *Britz J, Van De Ville D, Michel CM. BOLD correlates of EEG topography reveal rapid resting-state network dynamics. Neuroimage 2010; 52: 1162-1170*
19. *Lascano AM, Hummel T, Lacroix JS et al. Spatio-temporal dynamics of olfactory processing in the human brain: an event-related source imaging study. Neuroscience 2010; 167: 700-708*
20. *Ebersole J, Wade P. Spike voltage topography and equivalent dipole localization in complex partial epilepsy. Brain Topogr 1990; 3: 21-34*
21. *Grave de Peralta Menendez R, Murray M, Michel CM et al. Electrical neu-*

roimaging based on biophysical constraints. Neuroimage 2004. 21: 527-539

22. *Holmes MD, Tucker DM, Quiring JM et al. Comparing noninvasive dense array and intracranial electroencephalography for localization of seizures. Neurosurgery 2010; 66: 354-362 10.1227/01.NEU.0000363721.06177.07*
23. *Koessler L, Benar C, Maillard L et al. Source localization of ictal epileptic activity investigated by high resolution EEG and validated by SEEG. Neuroimage 2010; 51: 642-653*
24. *Yang L, Wilke C, Brinkmann B et al. Dynamic imaging of ictal oscillations using non-invasive high-resolution EEG. Neuroimage 2011; 56: 1908-1917*
25. *Fujiwara H, Greiner HM, Hemasilpin N et al. Ictal MEG onset source localization compared to intracranial EEG and outcome: Improved epilepsy presurgical evaluation in pediatrics. Epilepsy Res 2012; 99: 214-224*
26. *Rosenow F, Lüders H. Presurgical evaluation of epilepsy. Brain 2001; 124: 1683-1700*
27. *Spencer S. Huh L. Outcomes of epilepsy surgery in adults and children. Lancet Neurol 2008; 7: 525-537*
28. *Marsh ED, Peltzer B, Brown NW 3rd et al. Interictal EEG spikes identify the region of electrographic seizure onset in some, but not all, pediatric epilepsy patients. Epilepsia 2010; 51: 592-601*
29. *Asano E, Muzik O, Shah A et al. Quantitative interictal subdural EEG analyses in children with neocortical epilepsy. Epilepsia 2003; 44: 425-434*
30. *Hufnagel A, Dümpelmann M, Zentner J et al. Clinical relevance of quantified intracranial interictal spike activity in presurgical evaluation of epilepsy. Epilepsia 2000; 41: 467-478*
31. *Ray A, Tao JX, Hawes-Ebersole SM, Ebersole JS. Localizing value of scalp EEG spikes: a simultaneous scalp and intracranial study. Clin Neurophysiol 2007; 118: 69-79*
32. *Bautista RE, Cobbs MA, Spencer DD, Spencer SS. Prediction of surgical outcome by interictal epileptiform abnormalities during intracranial EEG monitoring in patients with extrahippocampal seizures. Epilepsia 1999; 40: 880-890*
33. *Bettus G, Ranjeva JP, Wendling F et al. Interictal functional connectivity of human epileptic networks assessed by intracerebral EEG and BOLD signal fluctuations. PLoS One 2011; 6: e20071*
34. *Agirre-Arrizubieta Z, Huiskamp GJ, Ferrier CH et al. Interictal magnetoencephalography and the irritative zone in the electrocorticogram. Brain 2009; 132: 3060-3071*
35. *Knowlton RC, Elgavish RA, Limdi N et al. Functional imaging: I. Relative predictive value of intracranial electroencephalography. Ann Neurol 2008; 64: 25-34*
36. *Knowlton RC, Elgavish RA, Bartolucci A et al. Functional imaging: II. Prediction of epilepsy surgery outcome. Ann Neurol 2008; 64: 35-41*
37. *Brodbeck V, Spinelli L, Lascano AM et al. Electroencephalographic source imaging: a prospective study of 152 operated epileptic patients. Brain 2011; 134: 2887-2897*
38. *Knowlton RC, Razdan SN, Limdi N et al. Effect of epilepsy magnetic source imaging on intracranial electrode placement. Ann Neurol 2009; 65: 716-723*
39. *Sutherling WW, Mamelak AN, Thyerlei D et al. Influence of magnetic source imaging for planning intracranial EEG in epilepsy. Neurology 2008; 71: 990-996*
40. *Fischer MJ, Scheler G, Stefan H. Utilization of magnetoencephalography results to obtain favourable outcomes in epilepsy surgery. Brain 2005; 128: 153-157*
41. *Gavaret M, Trébuchon A. Bartolomei F et al. Source localization of scalp-EEG interictal spikes in posterior cortex epilepsies investigated by HR-EEG and SEEG. Epilepsia 2009; 50: 276-289*
42. *Michel CM, Lantz G, Spinelli L et al. 128-channel EEG source imaging in epilepsy: clinical yield and localization precision. J Clin Neurophysiol 2004; 21: 71-83*
43. *Ossenblok P, de Munck JC, Colon A et al. Magnetoencephalography is more successful for screening and localizing frontal lobe epilepsy than electroencephalography. Epilepsia 2007; 48: 2139-2149*
44. *Jansen FE, Huiskamp G, van Huffelen AC et al. Identification of the epileptogenic tuber in patients with tuberous sclerosis: a comparison of high-resolution EEG and MEG. Epilepsia 2006; 47: 108-114*
45. *Lu Y, Yang L, Worrell GA, He B. Seizure source imaging by means of FINE spatio-temporal dipole localization and directed transfer function in partial epilepsy patients. Clin Neurophysiol 2012; 123: 1275-1283*
46. *Dai Y, Zhang W, Dickens DL, He B. Source connectivity analysis from MEG and its application to epilepsy source localization. Brain Topogr 2012; 25: 157-166*
47. *Negishi M, Martuzzi R, Novotny EJ et al. Functional MRI connectivity as a predictor of the surgical outcome of epilepsy. Epilepsia 2011; 52: 1733-1740*
48. *Vulliemoz S, Lemieux L, Daunizeau J et al. The combination of EEG source imaging and EEG-correlated functional MRI to map epileptic networks. Epilepsia 2010; 51: 491-505*
49. *Gross DW. Diffusion tensor imaging in temporal lobe epilepsy. Epilepsia 2011; 52(Suppl 4): 32-34*
50. *Bernhardt BC, Bernasconi N, Kim H, Bernasconi A. Mapping thalamocortical network pathology in temporal lobe epilepsy. Neurology 2012; 78: 129-136*
51. *Madhavan D, Heinrichs-Graham E, Wilson TW. Whole-brain functional connectivity increases with extended duration of focal epileptiform activity. Neurosci Lett 2013; Mar 15: Epub ahead of print*

Address for correspondence:
Dr Serge Vulliémoz
Chef de Clinique Scientifique
Unité d'EEG et Exploration des Epilepsies
Clinique de Neurologie
Hôpitaux Universitaires de Genève
rue Gabrielle-Perret-Gentil 4
CH-1211 Genève 14
Tél. 0041 22 372 83 52
Fax 0041 22 372 83 40
Serge.Vulliemoz@hcuge.ch

Neuroimaging of Temporal Lobe Epilepsy: Lesions and Networks

Eugenio Abela[1,2], Christian Rummel[2], Martinus Hauf[2,3], Christian Weisstanner[1], Kaspar Schindler[1], Roland Wiest[2]

[1] Department of Neurology, Inselspital, University Hospital Bern, University of Bern

[2] Support Center for Advanced Neuroimaging (SCAN), University Institute of Diagnostic and Interventional Neuroradiology, Inselspital, University of Bern

[3] Klinik Bethesda, Tschugg

Supported by the Swiss National Foundation (SNF), grant numbers 33CM30-140332 and 33CM30-124089

Summary

Recent research using multimodal neuroimaging has revealed that focal-onset epilepsies are accompanied by pathological changes in brain structure and function that extend far beyond the site of primary injury. These findings lend support to the notion that epilepsies are in fact network disorders, and that their clinical presentation, time course and treatment responsiveness might critically depend on network-wide effects. Although the network hypothesis is not new, current advances in neuroimaging technology have made it directly quantifiable – in vivo, non-invasively, with high spatiotemporal resolution and minimal inconvenience for the patient. In this article, we provide an overview of recent studies using advanced morphometric and functional magnetic resonance imaging (MRI), show how these modalities can be combined with one another and/or electroencephalographic (EEG) data and present clinical examples of how these techniques might be applied in practice.

Epileptologie 2013; 30: 131 – 137

Key words: Temporal lobe epilepsy, lesion localization, functional connectivity, network effects

Neuroimagerie de l'épilepsie du lobe temporal : lésions et réseaux

Des recherches récentes utilisant la neuroimagerie multimodale ont révélé que les épilepsies focales sont accompagnées par des changements pathologiques de la structure et la fonction cérébrale qui s'étendent bien au-delà du site de la lésion primaire. Ces résultats renforcent la notion que les épilepsies sont en fait des maladies de réseaux et que leur présentation clinique, leur évolution et leur réponse au traitement peut dépendre d'effets à l'échelle du réseau entier. Bien que l'hypothèse de réseau ne soit pas nouvelle, les avancées des techniques de neuroimagerie on rendu cette hypothèse directement quantifiable in vivo, de manière non-invasive avec une haute résolution spatiotemporelle et des inconvénients minimes pour le patient. Dans cet article, nous discutons des études récentes utilisant l'imagerie par résonance magnétique (IRM) fonctionnelle et morphométrique. Nous montrons comment ces techniques peuvent être combinées entre elles et avec les données électro-encéphalographiques (EEG) et nous présentons des exemples cliniques de leur applications.

Mots clés : Epilepsie du lobe temporal, localisation, connectivité fonctionnelle, effet des réseaux

Bildgebung bei Temporallappenepilepsie: von der Läsion zum Netzwerk

Fortschritte in der multimodalen Bildgebung haben neue Erkenntnisse zu den pathologischen Korrelaten fokaler Epilepsien erbracht. Insbesondere zeigt sich, dass die strukturellen und metabolischen Veränderungen weit ausgedehnter sind, als es die fokale Natur dieser Erkrankungen erahnen lassen würde. Dies hat zum Konzept geführt, fokale Epilepsien als Netzwerkerkrankungen zu verstehen, deren Symptomatik, Verlauf und therapeutische Modulierbarkeit sowohl von lokalen wie über das gesamte Netzwerk greifenden Effekten bestimmt werden. Modernes Neuroimaging kann Gehirnnetzwerke in kurzer Zeit mit minimaler Belastung für den Patienten darstellen und damit zu einem integralen Verständnis fokaler Epilepsien beitragen. In diesem Artikel geben wir eine kurze Übersicht zur Darstellung von Netzwerkeffekten fokaler epileptogener Läsionen mittels morphometrischer und funktioneller Neuroimaging-Studien anhand zweier klinischer Beispiele.

Schlüsselwörter: Temporallappenepilepsie, Läsionslokalisation, funktionelle Konnektivität, Netzwerkeffekt

Introduction

It has been known since the work of Ramón y Cajal (1852-1934) that the brain is basically a vast, dynamic, densely connected biological network of breathtaking complexity [1]. Much of clinical neurology to date, including epileptology, has mainly focused on identifying critical nodes within network structures in order to identify lesions that e.g. cause hemiparesis or generate seizures. However, it is well known that a lesion can exert distributed effects across large-scale brain network, leading to metabolic dysfunction or structural alterations of remote brain areas connected to the primary lesion site [2, 3]. An example of these effects is crossed cerebellar diaschisis, classically described as a reduction in regional cerebellar blood flow contralateral to a supratentorial ischemic lesion [4 - 6], but also apparent during focal epileptic seizures and status epilepticus [7, 8]. Indeed, using advances multimodal neuroimaging techniques, network-wide effects have been increasingly recognized in focal epilepsies [3, 9]. It has therefore been proposed to view epilepsies as a „network disorder“ and to integrate local and remote effects into a systems-level model of disease [3, 9 - 11] that would expand the well-known zonal concept commonly used in epileptology [12]. In this article, we provide a brief overview of structural and functional imaging findings that support the network hypothesis in epilepsy. We focus on temporal lobe epilepsies (TLE), because they represent the most prevalent form of focal epilepsies and one of the most frequently investigated with neuroimaging [13, 14]. Also, they can be used as a paradigm for network-wide effects of focal lesions, given their often (at least visually) restricted pathology to structures of the temporal lobe.

Lesion Analysis in TLE

The hallmark of mesial TLE (MTLE) is hippocampal or mesial temporal sclerosis (MTS), which is detected by MRI in 75-85% of the patients [15]. Current clinical MRI protocols for temporal lobe abnormalities incorporate high-resolution T1w, T2w and FLAIR imaging, with at least one set of T2w or FLAIR coronal slices perpendicular to the long axis of the hippocampus [16] . Interpretation should focus on hippocampal volume, increased signal intensity on T2-weighted imaging, and disturbed internal architecture. The presence of MTS on preoperative MRI is predictive for good outcome after epilepsy surgery [17], whereas preoperative temporal lobe volume differences provided equivocal results [18, 19]. In non-lesional MTLE 18F-fluorodeoxyglucose-positron emission tomography (FDG-PET) is predictive for good surgical outcome; whereas an added value of 11C-Flumazenil-PET (FMZ-PET) and proton magnetic resonance spectroscopy (MRS) has not been established [20]. Subtle focal cortical dysplasia may coincide in the temporal lobe or in extratemporal areas ipsilateral to the MTS [21]. While clinical applications of automated voxel-based analyses and cortical thickness analysis for individual patients with MTLE are still experimental, improvements within a range of 10-30% in the detection rate of focal cortical dysplasias have been reported [22 - 24]. In addition to conventional MRI, advanced imaging techniques as functional MRI and tractography lateralize eloquent brain areas (language and motor function), predict effects of temporal lobe resection on memory and visualize the topography and composition of cerebral white matter tracts [25].

Network Analysis in TLE

While lesion analysis and interpretation is the essential task for the neuroradiologist in clinical practice, a substantial body of epilepsy research has shown that focal lesions influence brain areas beyond the epileptogenic lesion, across ensembles of functionally and anatomically connected brain areas [26 - 30] characterized by coherent physiological activity, such as high-frequency oscillations on EEG or low-frequency (< 0.1Hz) blood oxygen level dependent (BOLD) signal fluctuations. The BOLD signal is the most commonly used contrast mechanism in functional MRI and is thought to reflect the hemodynamic response of the brain to exogenous stimuli (such as an image or a tone) or endogenous neural activity (such as interictal epileptiform discharges). Covariance analysis of these fluctuations determines areas of the brain that form functionally connected networks. More than twenty independent networks have been identified that correspond to intrinsic and extrinsic systems, and are associated with internal- and external-oriented processing, respectively [31]. Many studies that investigated alterations of gray matter volume and concentrations using MRI-based automated analysis techniques as voxel-based morphometry and cortical thickness analysis on a whole brain level have shown that structural changes in mTLE patients are not restricted to the hippocampus or the elements of the mesial temporal lobe [32], but show widespread abnormalities that extend into the temporal pole, temporolimbic and frontocentral regions [33, 34], the cerebellum and the thalamus [35] and longitudinal increases in volume loss [36]. Neuronal network damage in TLE with hippocampal atrophy and in MRI-negative TLE has been reported to be more widespread in patients with a left-sided seizure focus [35]. This may be explained by more extensively connected temporofrontal networks in the dominant hemisphere, due to their involvement in language function with more intense seizure propagation in the left hemisphere re-

sulting in a prominent neuronal loss in LTLE [37]. Furthermore, an association between residual seizures and atrophy in temporopolar and insular cortices in TLE with hippocampal atrophy and in the posterior quadrant in MRI-negative TLE has been reported [38] .

Our group has recently examined the spatial relationship between widespread cortical atrophy and functionally connected networks linked to interictal epileptiform discharges, using simultaneous EEG-fMRI in a cohort of patients suffering from mTLE [39]. In EEG-fMRI, both modalities are recorded at the same time using MRI-compatible electrodes. After postprocessing, the time course of interictal epileptiform discharges found on the EEG trace can be used to indentify spatiotemporal correlates of the BOLD signal, i.e. regions of the brain whose hemodynamic response is closely coupled to the EEG-activity. It is thought that these areas represent the irritative zone and its associated network. In the aforementioned study, we detected hemodynamic correlates to interictal epileptiform discharges beyond the seizure onset zone in the ipsilateral insula, the temporal pole and temporo-lateral neocortex, in the cerebellum, along the central sulcus and bilaterally in the cingulate gyrus. Equally widespread reductions in grey matter volume were detected in the middle and inferior temporal gyrus, the uncus to the hippocampus, the insula, the posterior cingulate and the anterior lobe of the cerebellum. These findings were in line with the cortical thickness changes described above. Previous ictal connectivity studies in mTLE exhibited patterns of bilateral increases of cerebral blood flow in the temporal lobes (predominantly the middle and superior temporal gyrus including the temporal pole, the posterior temporal lobe and the cerebellum) and decrease cerebral blood flow in the inferior temporal gyrus, the inferior parietal lobe and posterior cingulated [40]. Of note, there is a tight spatial overlap between hemodynamic and atrophy effects along mesolimbic areas, but not in regions beyond the limbic network [15].

Clues from morphometric analyses and combined EEG/fMRI recordings implicate that the widespread structural damage linked to abnormal hemodynamic responses is suggestive of TLE being a system rather than a focal disorder leading to a disruption of structural networks. Both functional network analysis (derived from a temporal correlation of neurophysiologic signals in different brain regions) to illustrate brain dynamics on a system level and structural network analysis (using advanced neuroimaging techniques as diffusion tensor or diffusion spectrum imaging) provided further advances in knowledge about interregional network disruptions in mTLE [41]. While graph-theoretical analyses revealed a small-world organization of the cerebral cortex in healthy individuals [42], global network organization of patients revealed increased path length in TLE [41]. Several authors demonstrated altered connectivity in patients with mTLE. As a key finding, they reported increased connections within the mesial temporal lobe and decreased connectivity along extratemporal areas, including contralateral temporal regions [43 - 45]. Others suggested altered bitemporal connectivity patterns in patients with mTLE [46]. These findings suggest a deleterious impact of the epileptic lesion and the epileptogenic zone on the whole brain, potentially impacting multiple cerebral networks [47].

Network Relationships across Modalities

What is the relationship between the functional and structural changes reviewed above? A recent study by Voets et al. examined the association between resting-state functional networks, brain atrophy and changes in white matter microstructure in 35 patients with TLE [48]. Interestingly, Voets et al. reported reduced functional interactions between the hippocampus and anterior temporal and sensorimotor cortices that covaried with the extent of grey matter atrophy, i.e. reduced integration of the hippocampus with the rest of the network could be explained by the degree of grey matter volume reduction in the same areas. Of note, these areas parallel those that we found to correlate with IEDs in simultaneous EEG-fMRI. Additionally Voets et al. discovered that functional integration outside this network, e.g. between frontal and temporal areas, was dependent on white matter microstructure rather than grey matter atrophy.

Network Relationships across Modalities: Clinical Examples

We present two cases where we used visual and automated methods to identify the epiletogenic lesion, EEG-fMRI to map the interictal network, and functional connectivity to define the lesion-dependent network.

Case 1

We used surface based morphometry (SBM) with FreeSurfer [49, 50] as a tool for comparison of cortical properties like thickness, curvature and sulcal depth between subject groups. As mentioned above, in [51] it was shown that SBM may also be useful for quantitative assessment of cortical malformations in individual epilepsy patients during pre-surgical evaluation. Here we compared cortical thickness of our patient (female, 34 years) to a gender matched control group of 16 females (age 30 to 40 years, mean 33.4, standard error of the mean 0.9) who received T1 weighted imaging with the same MR sequence (MPRAGE, TE=2.2ms, TR=1950ms, TI=900ms). While on the left hemisphere no significant deviations from the control group were found, several regions survived false discovery rate (FDR) correction on level 0.05 in the right hemisphere

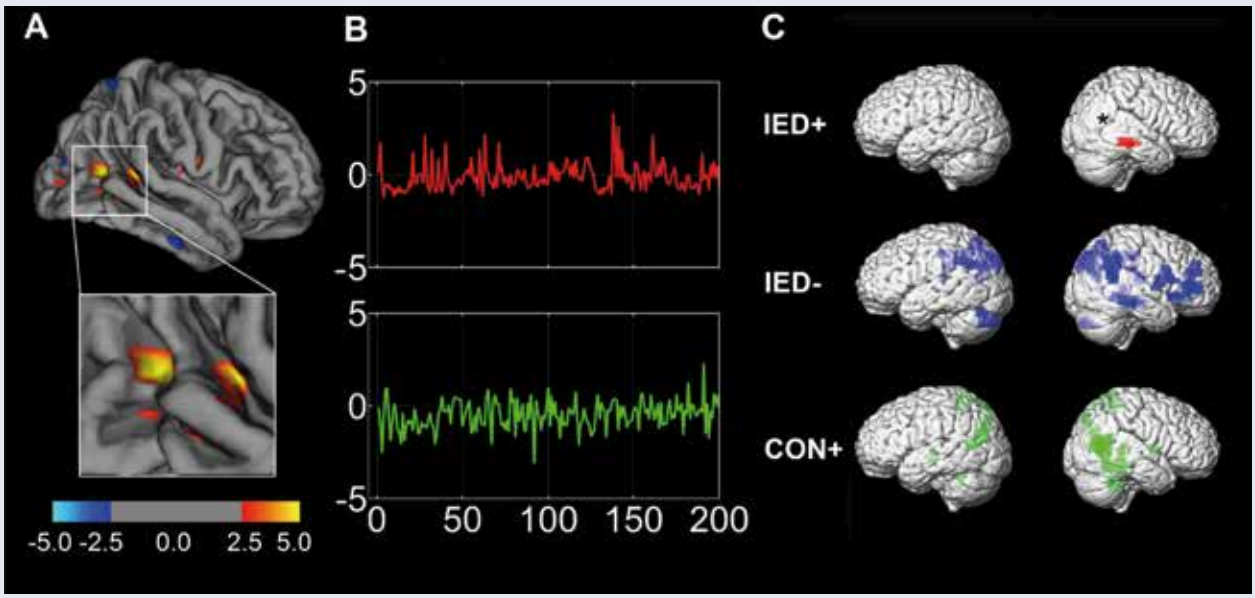

Figure 1. Patient example: lateral TLE.
A: Lesion in the right temporo-parietal cortex leads to extended deactivations of the default-mode network during interictal epileptiform discharges (IED), and shows pathological resting-state connectivity to the same areas. A: surface-based cortical thickness analysis (increase in hot colors, decrease in cool colors). Color bar represents z-scores compared to healthy controls. Insert shows a magnification of the largest cluster of cortical thickness increase in the right temporo-parietal junction, corresponding to an extended cortical heterotopia.
B: Upper row, (rectified) time course of IED, derived from a multivariate analysis of the EEG inside the scanner during simultaneous EEG-fMRI. Lower row, time course of BOLD-signal fluctuations from the same examination, extracted from the cortical thickness cluster seen in Panel A. Time courses are normalized to unit standard deviations of each time series (y-axis). For clarity, only the first 200 of 460 time points (scans) have been plotted (x-axis).
C: BOLD-correlation maps superimposed on 3D renderings of the patient's brain (peak threshold $p < .001$, uncorrected, extent threshold $p < .05$, FDR-corrected). Upper row: positive (IED+) correlation between BOLD-signal and IED time course in the lateral and inferior temporal gyrus on the right. Middle row: negative (IED-) correlations between BOLD-signal and IED time course in an extended network including (i) on the right the lateral and inferior temporal gyrus, the parietal operculum, the inferior frontal cortex (ii) on the left the anterior cerebellum, and (iii) bilaterally the precuneus and the inferior parietal cortex. Lower row: positive resting-state functional connectivity (CON+) between the cortical heterotopia and a network overlapping with IED- above, including (i) right inferior temporal cortex and (ii) bilateral inferior parietal cortex and precuneus. (*) indicates approximate center of mass from Panel A.

(**Figure 1**, Panel A). These included notably two large clusters of increased cortical thickness in the temporo-parietal junction and the middle temporal gyrus, corresponding to an extended cortical heterotopia, but also significant atrophy in the fusiform gyrus (not shown). It has recently been shown that these malformations might still be functionally connected to healthy cortex [52], which might have epileptogenic effects. We therefore calculated the functional connectivity using cross-correlations between the BOLD-signal from the heterotopic cortex (**Figure 1**, Panel B, lower row) and the rest of the brain. We found a bilateral functional network (**Figure 1**, Panel C, lower row) that included the inferior parietal cortex and the precuneus bilaterally, areas known to participate in the DMN. Interestingly, a broadly similar network was found to be anticorrelated with, or deflected during, IED (Panel C, middle row), which extended into right frontal areas and the contralateral anterior cerebellum. Note that this pattern of deactivation has already been shown in a group of TLE patients using cerebral blood flow measurements with SPECT [40], underscoring the validity of our single-subject results. Note also that the region that correlated positively with the IED time course (Panel C, upper row) was restricted to a localized region close to the heterotopia, in strong contrast to the network-wide, possibly pathological functional connectivity effects (Panel C, lower row). Due to the volume of heterotopic cortex, no surgery could be performed.

Case 2

This 21 years old female suffered from longstanding pharmacoresistant epilepsy (from 5 years of age) due to left MTS (**Figure 2**, Panel A). She underwent presurgical EEG-fMRI to identify BOLD-correlates linked to IED (**Figure 2**, Panel B, upper row) that could be found

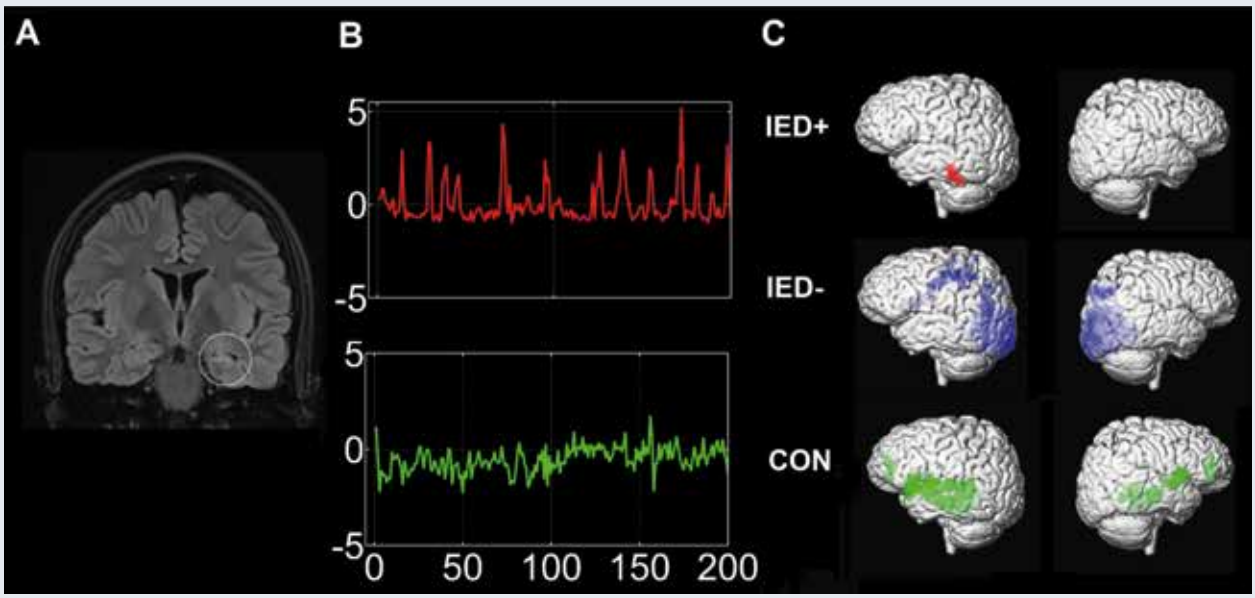

Figure 2. Patient example: mesial TLE with left hippocampal sclerosis.
A: Coronal section through a fluid-attenuated inversion recovery image shows left signal hyperintensity and volume loss of the hippocampal formation.
B: Upper row, (rectified) time course of IED from simultaneous EEG-fMRI, as in Figure 1. Lower row, time course of BOLD-signal fluctuations, extracted from a cytoarchitectonic probabilistic map of the left hippocampal CA1 region. Time courses are normalized and plotted as in Figure 1.
C: BOLD-correlation maps superimposed on 3D renderings of the patient's brain (peak threshold $p < .001$, uncorrected, extent threshold $p < .05$, FDR-corrected). Upper row, significantly positive (IED+) correlation between BOLD-signal and IED time course in left posterior parahippocampal gyrus (projects onto brain surface due to semitransparent plotting). Middle row: Significantly negative (IED-) correlations between BOLD-signal and IED time course in an extended network including (i) left postcentral gyrus (ii) bilateral cuneus, precuneus and inferior parietal cortex. Lower row: Positive resting-state functional connectivity (CON+) between left hippocampus and (i) left lateral temporal cortex, (ii) right hippocampus (iii) bilateral anterior cingulate cortex and insula.

in the depth of the left posterior temporal lobe (semi-transparent rendering in **Figure 2**, Panel C, upper row). Similarly to the 1st case, there was a widespread deactivation including the bilateral posterior parietal cortex, cuneus and precuneus and the left sensorimotor cortex. We used the BOLD-time series from the epileptogenic lesion to generate brain-wide maps of functional connectivity (**Figure 2**, Panel C) and detected a bilateral mesio-temporal connectivity network including bilaterally the hippocampus, insula, anterior cingulate and parietal operculum, and the lateral temporal cortex on the left (**Figure 2**, Panel C). In contrast to Case 1, there was no apparent overlap between IED- and functional connectivity networks. Of note, the left polar and lateral temporal regions visible on the functional connectivity map were included in the surgical resection. The patient has remained seizure-free (current follow-up 2.5 years).

Conclusions

An increasing body of literature – further illustrated by two clinical cases – indicates that epiletogenic lesions have widespread effects on the network structure of the brain. Here, we provided two examples of a network perspective on epilepsy that could further implicate clinical research and practice in future. One practical implication of the network concept is that it may radically alter our current classification of epilepsies [53]. Further, a concept of network organization along strategic nodes and connections may influence surgical planning. Several outcome studies indicated that seizure freedom can be attained in 60-70% of TLE patients with different resective approaches (anterior, medial or lateral temporal lobectomy and combinations thereof) [17, 54].

Despite the promises of a network-based perspective in epileptology, translation to the bedside remains challenging. From a methodological point of view, integrating multimodal data sets into a coherent analysis framework is a non-trivial problem, and will certainly necessitate advanced statistical modeling techniques. Much research is needed in this area. On the other

hand, there are practical questions for the daily clinical routine that need to be answered, before these methods can be brought to fruition. For instance, what is the sensitivity and specificity of neuroimaging techniques, alone or in combination [55]? How can results be reported in a rapid, easily understandable manner? What is the added value of multimodality neuroimaging and network analysis for patients and doctors; do they really inform clinical decision-making and improve treatment outcomes, or just add another layer of complexity to an already challenging situation? As we have shown with practical examples, methods are already in place to examine these questions and might help to advance epilepsy into a truly network-based medical discipline [53, 56, 57].

References

1. *Llinas RR. The contribution of Santiago Ramon y Cajal to functional neuroscience. Nat Rev Neurosci 2003; 4: 77-80*
2. *Alstott J, Breakspear M, Hagmann P et al. Modeling the impact of lesions in the human brain. PLoS Comput Biol 2009; 5: e1000408*
3. *Laufs H. Functional imaging of seizures and epilepsy: evolution from zones to networks. Curr Opin Neurol 2012; 25: 194-200*
4. *Komaba Y, Osono E, Kitamura S, Katayama Y. Crossed cerebellocerebral diaschisis in patients with cerebellar stroke. Acta Neurol Scand 2000; 101: 8-12*
5. *Lin DD, Kleinmann JT, Wityk RJ. Crossed cerebellar diaschisis in acute stroke detected by dynamic susceptibility contrast MR perfusion imaging. AJNR Am J Neuroradiol 2009; 30: 710-715*
6. *Srinivasan A, Miller W, Stys P, Goyal M et al. Crossed cerebellar diaschisis in stroke. Neurology 2004; 62: 2130*
7. *Rabinowicz AL, Salas E, Beserra F et al. Changes in regional cerebral blood flow beyond the temporal lobe in unilateral temporal lobe epilepsy. Epilepsia 1997; 38: 1011-1014*
8. *Cole AJ. Status epilepticus and periictal imaging. Epilepsia 2004; 45(Suppl 4): 72-77*
9. *Spencer SS. Neural networks in human epilepsy: evidence of and implications for treatment. Epilepsia 2002; 43: 219-227*
10. *Lopes da Silva F, Blanes W, Kalitzin SN et al. Epilepsies as dynamical diseases of brain systems: basic models of the transition between normal and epileptic activity. Epilepsia 2003; 44(Suppl 12): 72-83*
11. *Rummel C, Goodfellow M, Gast H et al. A systems-level approach to human epileptic seizures. Neuroinformatics 2013; 11: 159-173*
12. *Rosenow F, Luders H. Presurgical evaluation of epilepsy. Brain 2001; 124: 1683-1700*
13. *Ell PJ, Costa DC. Role of routine functional brain imaging in temporal lobe epilepsy. Lancet 1989; 1: 959*
14. *Wang A, Peters TM, de Ribaupierre S, Mirsattari SM. Functional magnetic resonance imaging for language mapping in temporal lobe epilepsy. Epilepsy Res Treat 2012; 2012: 198183*
15. *Bernasconi N, Bernasconi A, Caramanos Z et al. Mesial temporal damage in temporal lobe epilepsy: a volumetric MRI study of the hippocampus, amygdala and parahippocampal region. Brain 2003; 126: 462-469*
16. *Jackson GD, Berkovic SF, Duncan JS, Connelly A. Optimizing the diagnosis of hippocampal sclerosis using MR imaging. AJNR Am J Neuroradiol 1993; 14: 753-762*
17. *Engel J, Jr. Surgery for seizures. N Engl J Med 1996; 334: 647-652*
18. *Mueller CA, Scorzin J, von Lehe M et al. Seizure outcome 1 year after temporal lobe epilepsy: an analysis of MR volumetric and clinical parameters. Acta Neurochir (Wien), 2012; 154: 1327-1336*
19. *Jardim AP, Neves RS, Caboclo LO et al. Temporal lobe epilepsy with mesial temporal sclerosis: hippocampal neuronal loss as a predictor of surgical outcome. Arq Neuropsiquiatr 2012; 70: 319-324*
20. *Malmgren K, Thom M. Hippocampal sclerosis--origins and imaging. Epilepsia 2012; 53(Suppl 4): 19-33*
21. *Blümcke I, Thom M, Aronica E et al. The clinicopathologic spectrum of focal cortical dysplasias: a consensus classification proposed by an ad hoc Task Force of the ILAE Diagnostic Methods Commission. Epilepsia 2011; 52: 158-174*
22. *Duncan J. The current status of neuroimaging for epilepsy. Curr Opin Neurol 2009; 22: 179-184*
23. *Wagner J, Weber B, Urbach H et al. Morphometric MRI analysis improves detection of focal cortical dysplasia type II. Brain 2011; 134: 2844-2854*
24. *Focke NK, Symms MR, Burdett JL, Duncan JS. Voxel-based analysis of whole brain FLAIR at 3T detects focal cortical dysplasia. Epilepsia 2008; 49: 786-793*
25. *Duncan JS. Imaging in the surgical treatment of epilepsy. Nat Rev Neurol 2010; 6: 537-550*
26. *Wong BY, Prince DA. The lateral spread of ictal discharges in neocortical brain slices. Epilepsy Res 1990; 7: 29-39*
27. *Gale K. Subcortical structures and pathways involved in convulsive seizure generation. J Clin Neurophysiol 1992; 9: 264-277*
28. *Rafiq A, DeLorenzo RJ, Coulter DA. Generation and propagation of epileptiform discharges in a combined entorhinal cortex/hippocampal slice. J Neurophysiol 1993; 70: 1962-1974*
29. *Bear J, Fountain NB, Lothman EW. Responses of the superficial entorhinal cortex in vitro in slices from naive and chronically epileptic rats. J Neurophysiol 1996; 76: 2928-2940*
30. *Bertram EH. Functional anatomy of spontaneous seizures in a rat model of limbic epilepsy. Epilepsia 1997; 38: 95-105*
31. *Doucet G, Naveau M, Petit L et al. Brain activity at rest: a multiscale hierarchical functional organization. J Neurophysiol 2011; 105: 2753-2763*
32. *Salmenperä T, Kälviäinen R, Partanen K, Pitkänen A. Quantitative MRI volumetry of the entorhinal cortex in temporal lobe epilepsy. Seizure 2000; 9: 208-215*
33. *Keller SS, Roberts N. Voxel-based morphometry of temporal lobe epilepsy: an introduction and review of the literature. Epilepsia 2008; 49: 741-757*
34. *Bernhardt BC, Worsley KJ, Besson P et al. Mapping limbic network organization in temporal lobe epilepsy using morphometric correlations: insights on the relation between mesiotemporal connectivity and cortical atrophy. Neuroimage 2008; 42: 515-524*
35. *Riederer F, Lanzenberger R, Kaya M et al. Network atrophy in temporal lobe epilepsy: a voxel-based morphometry study. Neurology 2008; 71: 419-425*
36. *Cascino GD. Temporal lobe epilepsy is a progressive neurologic disorder: Time means neurons! Neurology 2009; 72: 1718-1719*
37. *Powell HW, Parker GJ, Alexander DC et al. Hemispheric asymmetries in language-related pathways: a combined functional MRI and tractography study. Neuroimage 2006; 32: 388-399*
38. *Bernhardt BC, Bernasconi N, Concha L, Bernasconi A. Cortical thickness analysis in temporal lobe epilepsy: reproducibility and relation to outcome. Neurology 2010; 74: 1776-1784*

39. Wiest R, Estermann L, Scheidegger O et al. Widespread grey matter changes and hemodynamic correlates to interictal epileptiform discharges in pharmacoresistant mesial temporal epilepsy. J Neurol 2013; ss: www-ddd
40. Weder BJ, Schindler K, Loher TJ et al. Brain areas involved in medial temporal lobe seizures: a principal component analysis of ictal SPECT data. Hum Brain Mapp 2006; 27: 520-534
41. Bernhardt BC, Chen Z, He Y et al. Graph-theoretical analysis reveals disrupted small-world organization of cortical thickness correlation networks in temporal lobe epilepsy. Cereb Cortex 2011; 21: 2147-2157
42. Van den Heuvel MP, Stam CJ, Boersma M, Hulshoff Pol HE. Small-world and scale-free organization of voxel-based resting-state functional connectivity in the human brain. Neuroimage 2008; 43: 528-539
43. Liao W, Zhang Z, Pan Z et al. Altered functional connectivity and small-world in mesial temporal lobe epilepsy. PLoS One 2010; 5: e8525
44. Seidenberg M, Kelly KG, Parrish J et al. Ipsilateral and contralateral MRI volumetric abnormalities in chronic unilateral temporal lobe epilepsy and their clinical correlates. Epilepsia 2005; 46: 420-430
45. Bettus G, Guedj E, Joyeux F et al. Decreased basal fMRI functional connectivity in epileptogenic networks and contralateral compensatory mechanisms. Hum Brain Mapp 2009; 30: 1580-1591
46. Morgan VL, Rogers BP, Sonmezturk HH et al. Cross hippocampal influence in mesial temporal lobe epilepsy measured with high temporal resolution functional magnetic resonance imaging. Epilepsia 2011; 52: 1741-1749
47. Tracy J, Osipowicz K, Spechler Pet al. Functional connectivity evidence of cortico-cortico inhibition in temporal lobe epilepsy. Hum Brain Mapp 2012; Sept 15: Epub ahead of print
48. Voets NL, Beckmann CF, Cole DM et al. Structural substrates for resting network disruption in temporal lobe epilepsy. Brain 2012; 135: 2350-2357
49. Dale AM, Fischl B, Sereno MI. Cortical surface-based analysis. I. Segmentation and surface reconstruction. Neuroimage 1999; 9: 179-194
50. Fischl B, Sereno MI, Dale AM. Cortical surface-based analysis. II: Inflation, flattening, and a surface-based coordinate system. Neuroimage 1999; 9: 195-207
51. Thesen T, Quinn BT, Carlson C et al. Detection of epileptogenic cortical malformations with surface-based MRI morphometry. PLoS One 2011; 6: e16430
52. Christodoulou JA, Walker LM, Del Tufo SN et al. Abnormal structural and functional brain connectivity in gray matter heterotopia. Epilepsia 2012; 53: 1024-1032
53. Richardson MP. Large scale brain models of epilepsy: dynamics meets connectomics. J Neurol Neurosurg Psychiatry 2012; 83: 1238-1248
54. Bell ML, Rao S, So EL et al. Epilepsy surgery outcomes in temporal lobe epilepsy with a normal MRI. Epilepsia 2009; 50: 2053-2060
55. Hauf M, Jann K, Schindler K et al. Localizing seizure-onset zones in presurgical evaluation of drug-resistant epilepsy by electroencephalography/fMRI: effectiveness of alternative thresholding strategies. AJNR Am J Neuroradiol 2012; 33: 1818-1824
56. Barabasi AL, Gulbahce N, Loscalzo J. Network medicine: a network-based approach to human disease. Nat Rev Genet 2011; 12: 56-68
57. Engel J Jr, Thompson PM, Stern JM et al. Connectomics and epilepsy. Curr Opin Neurol 2013; 26: 186-194

Address for correspondence:
Prof. Dr. med. Roland Wiest
Support Center for Advanced Neuroimaging (SCAN)
Institute of Diagnostic and Interventional Neuroradiology
Inselspital, Freiburgstrasse
CH 3010 Bern
Tel. 0041 31 6322655
Fax 0041 31 6324872
roland.wiest@insel.ch

Alfred-Hauptmann-Preis

Dieser Preis ist nach dem deutschen Neurologen und Psychiater Alfred Hauptmann (1881 - 1948) benannt. Er hatte u.a. schon 1912 – noch als Assistenzarzt – erstmals auf die antiepileptische Wirkung von Phenobarbital aufmerksam gemacht. 1935 wurde er aufgrund seiner jüdischen Abstammung von den Nationalsozialisten aus dem Dienst als Direktor der Psychiatrischen und Nervenklinik der Universität Halle/Saale entfernt und musste in die USA emigrieren.

Der Preis wurde von 1980 bis 2008 in der Regel alle zwei Jahre durch das Epilepsie-Kuratorium e.V. vergeben, seit 2009 ist es ein gemeinsamer Preis der Deutschen und Österreichischen Gesellschaften für Epileptologie und der Schweizerischen Liga gegen Epilepsie mit Vergabe auf den alle zwei Jahre stattfindenden gemeinsamen Tagungen.

Ausgezeichnet wird die beste wissenschaftliche Arbeit aus dem deutschsprachigen Raum auf dem Gebiet der experimentellen und klinischen Epileptologie aus den beiden letzten, der Verleihung vorangegangenen Jahren.

Arbeiten werden besonders aus den Fachgebieten Neurologie, Pädiatrie, Psychiatrie, klinische Pharmakologie, Neurophysiologie und Neurobiologie erwartet.

Die ausgezeichneten Personen erhalten eine Urkunde. Darüber hinaus ist der Preis mit

10’000 Euro

dotiert. Das Preisgeld wird seit 2009 von der Firma UCB GmbH (Deutschland), Monheim, zur Verfügung gestellt. Es können mehrere Einzelpersonen oder Arbeitsgruppen ausgezeichnet werden.

Die Arbeiten sollten in englischer Sprache verfasst sein. Zusätzlich zu den Arbeiten sind folgende weitere Unterlagen einzureichen:

- ein Lebenslauf,
- eine Stellungnahme des Klinik-/Institutsvorstandes zur Bewerbung,
- für den Fall von Mehrautorenarbeiten, bei denen nicht alle Autoren am Preis beteiligt werden sollen, eine Aussage über den Anteil der einzelnen Autoren an der publizierten Arbeit.

Die Arbeiten sind in vierfacher Ausführung bis zum

31.12.2014

an den Vorsitzenden des Kollegiums zu senden:

Herrn Dr. med. Günter Krämer
Präsident Schweizerische Liga gegen Epilepsie
Seefeldstrasse 84
Postfach 1084
CH 8034 Zürich

Es können sowohl unveröffentlichte als auch publizierte Arbeiten eingereicht werden. Bei der Einreichung ist mitzuteilen, ob und wo die Arbeit zum ersten Mal veröffentlicht wurde. Die Arbeiten sollen in deutscher oder englischer Sprache verfasst sein. Dem Kollegium können auch Arbeiten zur Preisvergabe vorgeschlagen werden.

Preisrichterkollegium: Dr. med. Günter Krämer (Vorsitzender), Prof. Dr. med. Rudolf Korinthenberg, Universitätskinderklinik Freiburg, Prof. Dr. med. Wolfgang Löscher, Institut für Pharmakologie, Toxikologie und Pharmazie, Hannover, Günther Sperk, Univ.-Prof. Dr. Abteilung Pharmakologie, Medizinische Universität, Innsbruck.

Epilepsie-Liga

forscht – hilft – informiert

Der Epilepsie-Bericht 2013 gibt einen Überblick über die Versorgungssituation heute in der Schweiz. Er enthält Informationen über die Häufigkeit von Epilepsie in der Bevölkerung und deren Einstellung zu dieser Krankheit, aber auch über ökonomische Aspekte. Weitere Themen sind die Grundlagenforschung, die Entwicklungen in Diagnostik und Therapie sowie Angebote für Patienten und Angehörige. Ausserdem finden sich darin die wichtigsten Adressen von spezialisierten Institutionen, Patienten- und Fachorganisationen.

Bestellungen des Epilepsie-Berichts 2013 nimmt die Epilepsie-Liga gerne entgegen, Tel. 043 488 67 77 oder info@epi.ch.

Bestellgutschein

Senden Sie mir bitte:

D	F	I	
■	■		Flyer „Epilepsie im Alter“
■	■	■	Flyer „Mann und Epilepsie“
■	■	■	Flyer „Was ist Epilepsie“
■	■	■	Flyer „Ursachen von Epilepsien“
■	■	■	Flyer „Merkmale von Anfällen“
■	■	■	Flyer „Häufige Anfallsformen bei Kindern“
■	■	■	Flyer „Medikamentöse Behandlung“
■	■	■	Flyer „Erste Hilfe bei Epilepsie“
■	■	■	Flyer „Frau und Epilepsie“
■	■	■	Flyer „Kinderwunsch und Epilepsie“
■	■	■	Flyer „Reisen und Epilepsie“
■	■		Programmheft Veranstaltungen der Epilepsie-Liga
■	■	■	Flyer „Autofahren und Epilepsie“
■	■		Flyer „Sport und Epilepsie”
■	■		Flyer „Arbeit und Epilepsie”
■	■		Fachzeitschrift „Epileptologie“
■	■		Flyer „Ketogene Diäten“
■	■	■	Einzahlungsschein(e) zur Unterstützung der Epilepsie-Liga
■	■	■	Ratgeber für Legate
■	■	■	Ratgeber „Epilepsie und Versicherungen”
■	■		Flyer „Vagusnervstimulation“
■	■		Flyer „Compliance“

DVDs und übrige Publikationen siehe www.epi.ch

Ich (wir) möchte(n):

■ Einzelmitglied der Epilepsie-Liga werden und bezahle mindestens 50 Franken jährlich.

■ Kollektivmitglied der Epilepsie-Liga werden und bezahlen mindestens 100 Franken jährlich.

Epilepsie-Preise

Gerne machen wir Sie auf die Broschüre „Epilepsie. Auszeichnungen, Preise, Stipendien und Stiftungen 2012/2013“ von Günter Krämer und Claudia Mühlebach aufmerksam. Darin finden Sie alle Informationen (Termine, Bedingungen), die Sie für eine Bewerbung benötigen. Bitte weisen Sie mögliche Anwärter in Ihrem Umfeld auf die Broschüre hin. Diese können Sie auf www.epi.ch unter Publikationen herunterladen oder bei info@epi.ch bzw. der Geschäftsstelle der Epilepsie-Liga, Seefeldstrasse 84, Postfach 1084, 8034 Zürich, bestellen.

Absender/in

Name | Vorname

Strasse | Nr.

PLZ | Ort

Telefon

eMail

Bitte frankieren

Schweizerische Liga gegen Epilepsie

Seefeldstrasse 84
Postfach 1084
CH 8034 Zürich

Epilepsie-Liga-Mitteilungen

Ausschreibung – Forschungsförderung

Förderung der wissenschaftlichen Forschung im Bereich der Epilepsie (vorwiegend Starthilfen) durch die Schweizerische Liga gegen Epilepsie (Epilepsie-Liga)

Die Epilepsie-Liga unterstützt wissenschaftliche Projekte im Bereich der Epileptologie im Gesamtbetrag von

CHF 25'000.—

pro Jahr. Insbesondere soll die Erforschung von Ursachen und Behandlungen der Epilepsie gefördert werden.

Stipendien für Aus- oder Weiterbildung oder Auslandaufenthalte werden nicht ausgerichtet. Hingegen können Reise- und Aufenthaltskosten (ohne Salär) für Kurzaufenthalte (maximal einige Wochen) finanziert werden, sofern sie dem Erlernen von Methoden dienen, welche im Rahmen eines unterstützten Projektes in der Schweiz eingesetzt werden.

Falls der Antragsteller/die Antragstellerin bereits anderswo Anträge für Unterstützung gestellt hat, ist offen zu legen, bei wem und mit welchem Ergebnis.

Termin für die Einreichung von Gesuchen: 31. Dezember 2013

Formulare und Wegleitung für Gesuchstellende können angefordert werden bei:

Schweizerische Liga gegen Epilepsie
Seefeldstrasse 84 | Postfach 1084
8034 Zürich
Tel. 043 488 67 77 | Fax 043 488 67 78
info@epi.ch

Vorschau Epileptologie 3 | 2013

Kombination von elektrischer und hämodynamischer Bildgebung in der Epilepsiediagnostik
Christoph Michel | Genf

Structure, Function and Genes – What Can We Learn From MRI
Giorgi Kuchukhidze | Innsbruck, Österreich

Genetische und chemokonvulsive Zebrafischmodelle für die Entwicklung neuer Antiepileptika
Alexander Crawford | Leuven, Belgien

Hereditäre epileptische Enzephalopathie mit Amelogenesis imperfecta – Kohlschütter-Tönz-Syndrom (KTZS). Bericht über einen weiteren, posthum erfassten Patienten aus der Zentralschweiz
Otmar Tönz | Luzern

Ausschreibung – Promotionspreis

Die Schweizerische Liga gegen Epilepsie (Epilepsie-Liga) vergibt alle 3 Jahre einen Preis in Höhe von

CHF 5'000.—

für die beste Dissertation auf dem Gebiet der Epileptologie.

Bewerbungen sind aus allen Fachbereichen und Berufsgruppen möglich und erwünscht, sowohl aus Grundlagen- als auch klinischen Fächern. Eine Altersbeschränkung erfolgt nicht.

Das Preisrichterkollegium setzt sich aus drei Vorstandsmitgliedern der Epilepsie-Liga zusammen, das bei Bedarf zusätzlich externe Gutachter hinzuziehen kann. Es trifft seine Entscheidung in geheimer Wahl.

Falls der Antragsteller/die Antragstellerin bereits anderswo Anträge für Unterstützung gestellt hat, ist offen zu legen, bei wem und mit welchem Ergebnis.

Die Preisverleihung erfolgt jeweils im darauf folgenden Jahr anlässlich der Jahrestagung oder Mitgliederversammlung der Epilepsie-Liga.

Bewerbungen sind **bis zum 31.12.2015** an die **Geschäftsstelle der Epilepsie-Liga** (Seefeldstrasse 84, Postfach 1084, 8034 Zürich) einzureichen und müssen beinhalten: vier Exemplare der abgeschlossenen und beim Dekanat eingereichten Dissertation, vier Exemplare einer Stellungnahme des Doktorvaters (dabei kann es sich auch um das entsprechende Gutachten für die Dissertation handeln).

Verabschiedung Giovanni Battista Foletti

Lieber Giovanni

Im Namen des gesamten Vorstands, der verschiedenen Kommissionen, Mitarbeiterinnen der Geschäftsstelle und natürlich auch der Mitglieder möchte ich mich bei dir für deinen jahrzehntelangen unermüdlichen Einsatz und dein aussergewöhnliches Engagement für Menschen mit Epilepsie und die Schweizerische Liga gegen Epilepsie bedanken.

Du warst seit März 1982 Kraft deines Amtes als zunächst Leitender Arzt und ab 1990 Medizinischer Direktor der Institution von Lavigny Vorstandsmitglied der Liga und bist Ende 2011 parallel zum Ausscheiden mit Übergabe der Leitungsfunktion an Frau Dr. Maeder aus dem Vorstand und verschiedenen Kommissionen zurückgetreten. Von 2004 bis 2011 hast du dankenswerterweise das Amt des Vizepräsidenten bekleidet und mich wiederholt tatkräftig unterstützt.

Freundlicherweise hast du mich mit einigen Daten zu deinem Leben versorgt. Du wurdest am 23. Februar 1947 in Massagno im Tessin in einer Medizinerfamilie geboren. Dein Vater, Onkel und Grossonkel waren Ärzte, weshalb auch deine berufliche Orientierung bald feststand. Das erste Jahr des Medizinstudiums hast Du in Zürich absolviert, danach bist du nach Fribourg gewechselt und hast das Studium schliesslich 1974 in Lausanne mit der Promotion abgeschlossen.

Dann hast du zunächst in verschiedenen Krankenhäusern in der Romandie sowie im Tessin eine allgemeinmedizinische Ausbildung zum „Generalisten“ in Medizin und Chirurgie begonnen und eine Arztstelle im Verzascatal im Tessin angenommen, wo du u.a. mit toxischen „Delirien“ bei in den 70er-Jahren im Tessin noch endemischen Typhusinfektionen konfrontiert wurdest, die dein Interesse an Psychiatrie weckten. Psychotherapie war jedoch nicht „dein Ding“, weshalb du beschlossen hast, Franco Regli (damals Titular-Professor in Lausanne) nach einer Stelle zu fragen, die du 1978 auch antreten konntest. Bei der anschliessenden Facharztweiterbildung in Zürich, Fribourg, Rom und Lausanne war in Lausanne unser früherer Präsident Paul André Despland dein Mentor.

Aufgrund neuer Finanzierungsstrukturen – dieses Problem gab es also auch schon damals – musste sich das Institut von Lavigny 1981-82 neu orientieren. Dies erforderte u.a. eine Aufteilung des Spital- und Wohnbereichs und du warst mit deiner Ausbildung sowohl in Neurologie als auch Psychiatrie ein idealer Kandidat für die vakante Stelle der Medizinischen Leitung.

Während deiner Zeit in Lavigny hast du immer eine enge Kooperation mit der Abteilung für Neurologie am CHUV (auch als Konsiliararzt; médecin adjoint) aufrechterhalten, warst auch an etwa 30 Publikationen beteiligt und hast eine Arbeit für den Master of Education verfasst.

Ab 1985 hast du in Lavigny zusätzlich einen kleinen Bereich für Neurorehabilitation übernommen, wiederum in erster Linie als Kooperationsprojekt mit der Abteilung für Neurologie am CHUV. Inzwischen ist Lavigny die Neurorehabilitations-Klinik des Kantons Waadt geworden. Obwohl der Bereich Epilepsie in diese Struktur integriert ist, ist er aus medizinischer Sich unabhängig und damit auch für die Zukunft die historische Mission der Institution Lavigny gewährleistet.

Nicht unerwähnt bleiben soll auch, dass du über viele Jahre hinweg vielen Kollegen in der Neurologie und Epileptologie in der Schweiz bei ihrer Ausbildung geholfen hast, die dank deiner fachlichen und menschlichen Erfahrung zu besseren Ärzten wurden. Das gilt nicht nur für das CHUV in Lausanne, sondern auch für die Neurologie in Genf. Auch dort wurdest du als starker und guter Partner erlebt und warst ein geschätzter „Keyplayer“ in dem gemeinsamen epilepsiechirurgischen Zentrum Genf-Lausanne, der kollegial mit allen Beteiligten die Patienten betreut hat, vor und nach resektiver Chirurgie oder auch hippokampaler Tiefenhirnstimulation. Bezüglich letzterer gehörtest du damit zur „Avantgarde“ nicht nur unter den Schweizer Epileptologen, sondern auch international.

Inzwischen bist du zwar immer noch in Teilzeit als Epileptologe tätig, speziell bei Menschen mit Epilepsie und geistiger Behinderung, hast aber jetzt doch mehr Zeit, um dich um deine Frau und deine vier inzwischen erwachsenen Kinder zu kümmern.

Dabei wünschen wir alle dir viel Glück und nochmals ganz herzlichen Dank für deine wertvolle Mitarbeit in der Liga!

Günter Krämer

Wahlen

An der 47. Mitgliederversammlung der Epilepsie-Liga vom 10. Mai in Interlaken anlässlich der 8. Dreiländertagung der Deutschen und Österreichischen Gesellschaft für Epileptologie und der Schweizerischen Liga gegen Epilepsie wurden zwei neue Vorstandsmitglieder und drei neue korrespondierende Mitglieder gewählt.

Aus dem Vorstand der Epilepsie-Liga haben sich Dr. med. Max Kaufmann und Dr. med. Andrea Capone Mori verabschiedet. Ihnen gebührt grosser Dank für ihren jahrelangen Einsatz. Die übrigen Vorstandsmitglieder wurden für weitere drei Jahre in ihren Ämtern bestätigt. Neu gewählt wurde Dr. med. Anna Marie Hew-Winzeler für Andrea Capone Mori und Dr. med. Alexandre Datta für Max Kaufmann.

Anna Marie Hew-Winzeler machte in Schaffhausen die Matura und studierte in Zürich, Sheffield und Paris Medizin. Sie spezialisierte sich in der Folge im Fachgebiet Neurologie, wobei sie am Universitätsspital Zürich bei Professor G. Baumgartner tätig war. Eine längere Ausbildung in EEG erfolgte bei Professor R. Hess am Universitätsspital Zürich, bei Professor G. Dumermuth an der Universitätskinderklinik in Zürich und bei Professor Scollo-Lavizzari am Universitätsspital Basel. Seit mehr als 25 Jahren führt sie eine neurologische Praxis mit Schwerpunkt Epileptologie in Zürich.

Nach dem Abschluss der Schulzeit in Münchenstein studierte Alexandre Datta in Basel Medizin. Sein beruflicher Weg führte danach nach Zofingen, Mendrisio, Basel bei den Professoren U. B. Schaad und J. Lütschg, Genf bei PD Dr. med. Ch. A. Haenggeli und Professorin S. Suter, Aarau bei Professor Buettner und Paris bei Professor O. Dulac. Seit 2007 arbeitet er in Basel auf der Neuropädiatrie mit den Schwerpunkten Epileptologie und Schlafmedizin. 2008 erhielt der den Forschungsförderungspreis der Schweizerischen Liga gegen Epilepsie.

Die versammelten Mitglieder ernannten auf Vorschlag des Vorstands ausserdem drei neue korrespondierende Mitglieder: die Professoren Blaise Bourgeois, Boston, Fernando Lopes da Silva, Amsterdam, und Donald L. Schomer, Boston.

Heute im Children's Hospital in Boston tätig, studierte Blaise F.D. Bourgeois in Zürich, Lausanne und Genf Medizin. Nach weiteren Ausbildungsjahren in Brasilien, Irvine USA, Genf, und St. Louis USA. 1982 bis 1987 war er Leiter des Kinderbereiches der damaligen Schweiz. Epilepsie-Klinik. Seit 1998 ist er Professor für Neurologie an der Harvard Medical School in Boston. Er engagiert sich in zahlreichen Kommissionen und Editorial Boards und forscht insbesondere auf dem Gebiet der Antiepileptika.

Der gebürtige Portugiese Fernando Lopes da Silva studierte in Lissabon Medizin und arbeitete anschliessend in London auf dem Gebiet der Physiologie und darauf in Utrecht in der Neurophysiologie. Von 1993 bis 2000 war er Direktor des neu geschaffenen Instituts für Neurobiologie der Universität Amsterdam und Mitglied des „Scientific Governing Board oft he Graduate School Neurosciences" Amsterdam. Fernando Lopes da Silva erhielt zahlreiche Preise und Ehrungen und blieb der Lehre auch nach seiner Emeritierung verbunden.

Donald L. Schomer ist Direktor des Laboratoriums der Klinischen Neurophysiologie und Professor für Neurologie an der Harvard Universität in Boston. Er war mehrheitlich in Boston tätig und verbrachte die Jahre 1995 bis 1997 in Genf auf der Neurologischen Klinik des Universitätsspitals. Als aktives Mitglied engagierte er sich in mehreren Fachgesellschaften, so war er Präsident der American Clinical Neurophysiology Society und danach der American Academy of Clinical Neurophysiology.

Mise au concours – Soutien de la recherche

Promotion de la recherche scientifique dans le domaine de l'épilepsie (surtout sous forme d'aide initiale) par la Ligue Suisse contre l'Epilepsie (Ligue contre l'Epilepsie)

La Ligue contre l'Epilepsie soutient les projets scientifiques dans le domaine de l'épileptologie par un montant total de

CHF 25'000.—

par an, la priorité étant accordée aux projets cherchant à élucider les causes et à mettre au point des traitements de l'épilepsie.

Aucune bourse ne sera octroyée pour la formation de base ou continue ou pour des séjours à l'étranger. En revanche, la prise en charge de frais de voyage et de séjour (sans salaire) est possible pour les séjours de courte durée (quelques semaines au maximum) lorsque ces séjours servent à apprendre des méthodes appliquées dans le cadre d'un projet bénéficiant de soutien en Suisse.

Si le requérant a déjà fait une demande de soutien ailleurs, il faut nous en informer en spécifiant où et avec quel résultat.

Délai de remise des demandes :

31 décembre 2013

Les formulaires, ainsi que le guide pour les candidats peuvent être demandés à l'adresse suivante :

Ligue Suisse contre l'Epilepsie
Seefeldstrasse 84
Case postale 1084
8034 Zurich
Tél. 043 488 67 77
Fax 043 488 67 78
info@epi.ch

Mise au concours – Prix de promotion

La Ligue Suisse contre l'Epilepsie (Ligue contre l'Epilepsie) décerne tous les 3 ans un prix d'un montant de

CHF 5'000.—

pour la meilleure dissertation dans le domaine de l'épileptologie.

Tous les domaines spécialisés et tous les groupes professionnels couvrant les disciplines fondamentales ou cliniques sont invités à soumettre leur candidature. Aucune limite d'âge n'a été fixée.

Le jury décernant le prix se compose de trois membres du comité directeur de la Ligue contre l'Epilepsie. Il peut être complété au besoin par des experts externes. La décision est prise par vote secret.

Si le requérant a déjà fait une demande de soutien ailleurs, il faut nous en informer en spécifiant où et avec quel résultat.

Le prix est toujours décerné l'année suivante dans le cadre de l'assemblée annuelle ou générale de la Ligue contre l'Epilepsie.

Les dossiers de candidature doivent parvenir au Secrétariat de la Ligue contre l'Epilepsie (Seefeldstrasse 84, case postale 1084, 8034 Zurich) jusqu'au

31.12.2015

et comporter les pièces suivantes :

- quatre exemplaires de la dissertation achevée et remise au décanat,
- quatre exemplaires d'une prise de position du directeur de thèse (il peut par exemple s'agir de l'expertise concernant la dissertation).

Cher Giovanni,

Au nom de l'ensemble du comité directeur, des différentes commissions, des collaboratrices du secrétariat général et bien sûr aussi de nos membres, je souhaite te remercier pour l'engagement exceptionnel et inlassable dont tu as fait preuve durant plusieurs décennies en faveur des personnes atteintes d'épilepsie ainsi que de la Ligue Suisse contre l'Épilepsie.

C'est tout d'abord en ta qualité de chef de service puis, à partir de 1990, de directeur médical de l'institution de Lavigny que tu as été, dès mars 1982, membre du comité directeur de la Ligue, avant de quitter ce dernier ainsi que les différentes commissions, fin 2011, parallèlement à ta démission des fonctions de direction qui ont été alors confiées à la Dr méd. Maeder. Nous te sommes reconnaissants d'avoir, de 2004 à 2011, occupé les fonctions de vice-président, dans lesquelles tu m'as soutenu énergiquement à mainte reprise.

Tu as eu la gentillesse de me fournir quelques données biographiques te concernant. Tu es né le 23 février 1947 à Massagno, au Tessin, dans une famille de médecins. Ton père, ton oncle et ton grand-oncle étaient médecins, et cela a précocement déterminé ton orientation professionnelle. Tu as passé la première année de tes études à Zurich avant de partir tout d'abord à Fribourg, puis de terminer ton cursus universitaire en obtenant ton Doctorat à Lausanne en 1974.

Dans un premier temps, tu as alors débuté une formation de généraliste en médecine et en chirurgie dans différents hôpitaux de Romandie et du Tessin, puis occupé un poste de médecin dans le Val Verzasca, au Tessin, où tu as été confronté notamment avec des « délires » toxiques liés aux infections de typhus qui étaient encore endémiques au Tessin dans les années 1970, ce qui a éveillé ton intérêt pour la psychiatrie. Mais la psychothérapie n'étant pas « ta tasse de thé », tu as choisi de demander un poste à Franco Regli (alors professeur titulaire à Lausanne), poste que tu as obtenu en 1978. Au cours de la formation continue de spécialiste que tu as alors suivie à Zurich, Fribourg, Rome et Lausanne, c'est notre ancien président, Paul André Despland, qui a été ton mentor à Lausanne.

En raison d'une restructuration financière – ce problème existait donc déjà à l'époque –, l'Institut de Lavigny a fait l'objet d'une réorientation en 1981-82. Celle-ci exigeait une séparation des domaines hospitalier et résidentiel et, grâce à ta double formation en neurologie et en psychiatrie, tu étais un candidat idéal pour la place vacante de directeur médical.

Durant les années que tu as passées à Lavigny, tu as toujours veillé à entretenir une coopération étroite avec le service de neurologie du CHUV (y compris en tant que médecin adjoint), as participé à une trentaine de publications et rédigé un mémoire pour le Master of Education.

À partir de 1985, tu as en outre pris en charge à Lavigny un petit département de neuroréhabilitation, constituant aussi principalement un projet de coopération avec le service de neurologie du CHUV. Désormais, Lavigny est devenu la clinique de neuroréhabilitation du canton de Vaud. Bien qu'intégré à cette structure, le département d'épilepsie est indépendant du point de vue médical, ce qui garantit pour le futur la poursuite de la mission historique de l'institution de Lavigny.

Comment ne pas évoquer également que durant de nombreuses années, tu as accompagné dans le cadre de leur formation en neurologie et en épileptologie sur le territoire suisse un grand nombre de collègues qui, grâce à ton expérience tant professionnelle qu'humaine, sont devenus de meilleurs médecins. Ceci vaut non seulement pour le CHUV à Lausanne, mais également pour la neurologie genevoise. Là-bas aussi, tous ceux qui t'ont côtoyé t'ont perçu comme un partenaire fort et fiable, et tu as été un acteur-clé très apprécié du centre conjoint de chirurgie de l'épilepsie Genève-Lausanne, suivant les patients de façon collégiale aux côtés de l'ensemble du personnel concerné, avant et après une chirurgie résective ou une stimulation cérébrale profonde de l'hippocampe. Concernant cette dernière, tu fais donc partie de l'« avant-garde » – et ce, non seulement parmi les épileptologues suisses, mais aussi au plan international.

Si tu exerces aujourd'hui encore à temps partiel en tant qu'épileptologue, et ce, tout particulièrement auprès de personnes atteintes à la fois d'épilepsie et de handicap mental, tu as néanmoins désormais davantage de temps à consacrer à ton épouse et à tes quatre enfants, eux-mêmes adultes à présent.

Tous nos vœux t'accompagnent et nous te remercions tous encore une fois pour ta précieuse collaboration auprès de la Ligue !

Günter Krämer

2013

23.-27.6.2013 | Montreal, Canada
30th International Epilepsy Congress
Information: ILAE/IBE Congress Secretariat,
7 Priory Hall, Stillorgan, Dublin 18, Ireland,
e-mail: claire@epilepsycongress.org,
www.epilepsymontreal2013.org

27.-29.6.2013 | Bern
Swiss Academy of Young Neurologists
Information: Office SNG,
c/o IMK Institut für Medizin und Kommunikation AG,
Münsterberg 1, 4001 Basel,
Tel. 0041 / 61 / 2713551,
Fax 0041 / 61 / 2713338,
e-mail: swissneuro@imk.ch,
http://www.swissneuro.ch/

14.-26.7.2013 | San Servolo, Venedig, Italien
Brain Exploration and Epilepsy Surgery
Epilepsy Summer Course
Information: Metella Patrlini,
Fax 0039 / 02 / 700445211,
e-mail: epilepsysummercourse@univiu.org

15.8.2013 | Basel, Hotel Hilton, 9.30 – 18.00 Uhr
Basler Epilepsietag: Epilepsie – Therapeutische Optionen
Information : Tel. 0041 / 61 / 2654166
e-mail: jfleury@uhbs.ch

18.-23.8.2013 | Tallinn, Estonia
7th Baltic Sea Summer School on Epilepsy (BSSSE 7)
Information: Petra Novotny, BSSSE office
e-mail: petra.novotny@wolfstiftung.org,
http://www.epilepsiestiftung-wolf.de/

4.-6.9.2013 | Ljubljana, Slowenien
13th European Conference on Epilepsy & Society
Information: IBE Congress Secretariat,
7 Priory Hall, Stillorgan, Dublin 18, Ireland,
Tel. 0353 / 1 / 2056720,
Fax 0353 / 1 / 2056156,
e-mail: Ljubljana@epilepsycongress.org

6.-7.9.2013 | Berlin
International Epilepsy Symposium
Information: Epilepsie-Zentrum Berlin-Brandenburg am Evangelischen Krankenhaus, Königin Elisabeth Herzberge, z.Hd. Frau Cordula Hegemann,
Herzbergstrasse 79, 10365 Berlin,
Tel. 030 / 5472 / 3501, Fax 030 / 5472 / 3502,
e-mail: c.hegemann@keh-berlin.de

12.-14.9.2013 | Prien am Chiemsee, Deutschland
Jahrestagung des Deutsch-Österreichisch-Schweizer Arbeitskreises Epilepsie
Information: Prof. Dr. Hermann Stefan,
Claudia Saint-Lôt, Universitätsklinikum Erlangen,
Neurologische Klinik, Schwabachanlage 10,
D 91054 Erlangen,
e-mail: claudia.saint-lot@uk-erlangen.de

16.-20.9.2013 | Erlangen, Deutschland
1st International Summer School for Neuropathology and Epilepsy Surgery (INES)
Information: Ingmar Blümcke, MD, Chairman and Full Professor, Dept. of Neuropathology,
University Hospital Erlangen, Schwabachanlage 6
„Kopfklinikum“, 91054 Erlangen, Deutschland,
Tel. 0049 / 9131 / 8526031,
Fax 0049 / 9131 / 8526033,
e-mail: bluemcke@uk-erlangen.de,
www.epilepsie-register.de

18.-21.9.2013 | Dresden
86. Kongress der Deutschen Gesellschaft für Neurologie
Information: Congrex Deutschland GmbH,
Joachimstaler Str. 12, 10719 Berlin,
Tel. 0049 / 30 / 887108550,
Fax 0049 / 30 / 8871085579,
e-mail: dgn@congrex.com, www.congrex.de oder
www.dgnkongress.org/2013/anmeldung

19.9.2013 | Bern, 17 Uhr
Fachveranstaltung der Epilepsie-Liga
Information: Epilepsie-Liga, Seefeldstrasse 84,
Postfach 1084, 8034 Zürich,
Tel. 0041 / 43 / 4886777,
Fax 0041 / 43 / 4886778,
e-mail: info@epi.ch, www.epi.ch

19.9.2013 | Bern, 19.30 Uhr
Publikumsveranstaltung der Epilepsie-Liga
Information: Epilepsie-Liga, Seefeldstrasse 84,
Postfach 1084, 8034 Zürich,
Tel. 0041 / 43 / 4886777,
Fax 0041 / 43 / 4886778,
e-mail: info@epi.ch, www.epi.ch

21.-26.9.2013 | Wien, Österreich
21st World Congress of Neurology
Information: Univ.-Prof. Dr. Bruno Mamoli,
Garnisongasse 7/22, A 1090 Wien, Österreich,
Tel. 0043 / 1 / 512809019,
Fax 0043 / 1 / 512809180,
e-mail: oegn@admicos.com, www.oegn.at

26.9.2013 | Zürich, Schweiz. Epilepsie-Zentrum
Herbstsymposium
Information: Silvia Baader,
Tel. 0041 / 44 / 3876304,
Fax 0041 / 44 / 3876396,
e-mail: silvia.baader@swissepi.ch, www.swissepi.ch

30.9.-06.10.2013 | Jerusalem, Israel
5th Eilat International Educational Course: Pharmacological Treatment of Epilepsy
Information:Target Conferences, P.O. Box 29041,
Tel Aviv 61290, Israel,
Tel. 00972 / 3 / 5175150,
Fax 00972 / 3 / 5175155,
e-mail: eilatedu@targetconf.com, www.eilat-aeds.com

10.10.2013 | Genf, 16 Uhr
Fachveranstaltung der Epilepsie-Liga
Information: Epilepsie-Liga, Seefeldstrasse 84,
Postfach 1084, 8034 Zürich,
Tel. 0041 / 43 / 4886777,
Fax 0041 / 43 / 4886778,
e-mail: info@epi.ch, www.epi.ch

10.10.2013 | Genf, 19 Uhr
Publikumsveranstaltung der Epilepsie-Liga
Information: Epilepsie-Liga, Seefeldstrasse 84,
Postfach 1084, 8034 Zürich,
Tel. 0041 / 43 / 4886777,
Fax 0041 / 43 / 4886778,
e-mail: info@epi.ch, www.epi.ch

13.-15.10.2013 | New Orleans, Louisiana, USA
Annual Meeting of the American Neurological Association (ANA)
Information: American Neurological Association,
5841 Cedar Lake Road, Suite 204, Minneapolis,
MN 55416, USA,
Tel. 001 / 952-545-6284,
Fax 001 / 952-545-6073,
e-mail: anameeting@llmsi.com, www.aneuroa.org

30.11.2013 | Zürich
Patiententag
Information: Epilepsie-Liga, Seefeldstrasse 84,
Postfach 1084, 8034 Zürich,
Tel. 0041 / 43 / 4886777,
Fax 0041 / 43 / 4886778,
e-mail: info@epi.ch, www.epi.ch

6.-10.12.2013 | Washington, DC, USA
67th Annual Meeting of the American Epilepsy Society
Information: American Epilepsy Society, 342 North
Main Street, West Hartford, CT 06117-2507 USA,
Tel. 001 / 860 / 5867505,
Fax 001 / 860 / 5867550,
e-mail: info@aesnet.org, www.aesnet.org

Impressum

Herausgeber | Administration | Schlussredaktion
Schweizerische Liga gegen Epilepsie
Margret Becker, lic. phil. I
Seefeldstrasse 84, Postfach 1084,
CH-8034 Zürich
Tel. 0041 43 488 67 79
Fax 0041 43 488 67 78
becker@epi.ch

Konzeption | Gestaltung | Reinzeichnung
screenblue Büro für Design | Birgit Depping
Gazellenkamp 99, D-22529 Hamburg
bd@screenblue.de, www.screenblue.de

Belichtung | Druck
J.C.C. Bruns Betriebs GmbH
D-32423 Minden, www.jccbruns.de

Auflage
1.500 Exemplare

Versand
Eingliederungs- und Dauerwerkstätte
des Schweiz. Epilepsie-Zentrums
Bleulerstrasse 72, 8008 Zürich

Levetiracetam-Mepha® Teva

Der First-line Wirkstoff bei fokaler Epilepsie[2]

kassenzulässig

bis zu 34% günstiger als das Original[1]

Lactab® 250 mg

Lactab® 500 mg

Lactab® 1000 mg

* Zum Scannen des QR-Codes mit dem Smartphone brauchen Sie eine Applikation, die Sie z.B. im App Store unter «Scan» oder «QR» herunterladen können.

1 BAG, SL, 1.10.2012
2 Crepeau AZ et al. Levetiracetam: a comprehensive review, Expert Rev Neurother, 2010 Feb. 10(2), 159–171

Levetiracetam-Mepha® Teva, Z: Lactab® zu 250 mg *(blau)*: Color.: E 132, E 133, 500 mg *(gelb)*: Color.: E 102, E 132 oder 1000 mg *(weiss)* Levetiracetam. **I:** Monotherapie von partiellen Anfällen mit oder ohne sekundäre Generalisierung bei Patienten ab 16 Jahren mit Epilepsie oder als Zusatzbehandlung bei Erwachsenen und Kinder ab 4 Jahren. **D:** Tagesdosis in 2 Gaben unzerkaut mit Flüssigkeit einnehmen. Monotherapie > 16J: initial 2 × 250 mg/Tag nach 2 Wochen 2 × 500 mg/Tag bis max. 2 × 1500 mg/Tag. Zusatzbehandlung (≥ 18 Jahre) und Jugendliche (12–17 Jahre) ab 40 kg: initial 1000 mg/Tag bis max. 3000 mg/Tag. Kinder von 4–11 Jahren unter 40 kg: initiale therapeutische Dosierung 10 mg/kg Körpergewicht zweimal pro Tag. Spezielle Dosierungsanweisungen vgl. Arzneimittel-Kompendium. **Kt:** Überempfindlichkeit gegenüber Levetiracetam bzw. verwandten Substanzen oder einem der Hilfsstoffe. Schwangerschaft/Stillzeit. **V:** Psychiatrische Erkrankungen, Suizidversuche und Gedanken. **UW:** Infektionen, Nasopharyngitis, Thrombozytopenie, Anorexie, Gewichtszunahme, Agitation, Depression, emotionale Labilität/Stimmungsschwankungen, Feinseligkeit, Aggression, Schlaflosigkeit, Nervosität, Reizbarkeit, Persönlichkeitsveränderungen, abnormales Denken, Somnolenz, Amnesie, Ataxie, Konvulsion, Benommenheit, Kopfschmerzen, Hyperkinesie, Tremor, Gleichgewichtsstörungen, Aufmerksamkeitsstörungen, Beeinträchtigung des Gedächtnisses, Diplopie, verschwommenes Sehen, Schwindel, Husten, Abdominalschmerzen, Diarrhoe, Dyspepsie, Nausea, Erbrechen, Hautausschlag, Ekzem, Juckreiz, Myalgie, Asthenie, Müdigkeit, unfallbedinge Verletzungen, Ruhelosigkeit. **IA:** Enzym-induzierende Substanzen. Liste: B. [2312] Für weiterführende Informationen siehe Arzneimittel-Kompendium der Schweiz.

Mepha Pharma AG, 4051 Basel, Telefon 061 705 43 43, Fax 061 705 43 85, www.mepha.ch

4112

mepha Qualidoc online

Bioäquivalenz-Daten und Präparateprofile finden Sie online unter: www.mepha.ch, Fachpersonen, Qualidoc oder via QR-Code.*

Die mit dem Regenbogen

mepha