Epileptologie | Jahrgang 24 2 | 2007 ISSN 1660-3656

Epilepsie-Liga
Seefeldstrasse 84
CH-8034 Zürich

Inhalt

Schweizerische Liga gegen Epilepsie
Ligue Suisse contre l'Epilepsie
Lega Svizzera contro l'Epilessia
Swiss League Against Epilepsy

Richtlinien für die Autoren

Allgemeines

Epileptologie veröffentlicht sowohl angeforderte als auch unaufgefordert eingereichte Manuskripte über alle Themen der Epileptologie. Es werden in der Regel nur bislang unveröffentlichte Arbeiten angenommen. Die Manuskripte oder wesentliche Teile daraus dürfen auch nicht gleichzeitig anderen Zeitschriften angeboten werden oder anderweitig bereits zur Publikation angenommen worden sein. Alle Manuskripte werden zweifach begutachtet. Von den Beiträgen werden keine Sonderdrucke erstellt, sie werden jedoch als pdf-Datei zusätzlich auf der Liga-Homepage **(www.epi.ch)** veröffentlicht und können von dort heruntergeladen werden.

Redaktionsanschrift

Unaufgefordert eingereichte Manuskripte (inkl. Briefe an die Herausgeber) sind zu richten an: ***Frau M.Becker, Redaktion Epileptologie, Schweizerische Liga gegen Epilepsie, Seefeldstr. 84, Postfach 1084, 8034 Zürich. Tel. 043 488 67 79, Fax 043 488 67 78, e-mail: becker@epi.ch.***

Hinweise zur Manuskripterstellung

Manuskripte werden nur akzeptiert, wenn sie den folgenden Kriterien entsprechen. Nicht entsprechend abgefasste Manuskripte werden vor der Begutachtung zurückgesandt.

1. **Sprache:** Neben deutsch auch englisch und französisch möglich.
2. **Schreibweise (deutsch)**: Als Schreibweise gilt die deutsche Form mit „z“ und „k“ (also z.B. Karzinom), lateinische Fachtermini behalten aber ihre Schreibweise (also z. B. Arteria carotis).
3. **Form:** Der gesamte Text, einschliesslich Literaturverzeichnis, Tabellen und Abbildungslegenden, ist folgendermassen zu formatieren:
   - DIN-A4-Papier, einseitig (1 1/2- oder 2-zeilig mit max. 30 Zeilen je Seite).
   - Literaturverweise werden gemäss der Reihenfolge, in der sie im Text vorkommen, arabisch nummeriert; im Text erscheinen die Verweiszahlen in eckigen Klammern.
   - Tabellen und Abbildungen haben eine jeweils fortlaufende arabische Nummerierung.
4. **Reihenfolge:** 1. Titelblatt (ggf. inkl. Danksagung, Förderung durch Hilfe anderer oder Drittmittelfinanzierung), 2. Zusammenfassung in Deutsch, Résumé in Französisch und Summary in Englisch sowie je drei bis fünf Schlüsselwörter, 3. Text, 4. Literatur, 5. Tabellen, 6. Abbildungslegenden und 7. Abbildungen:
   - Das Titelblatt enthält den vollen Titel der Arbeit (deutsch und englisch), Namen und Titel der Autoren, die Kliniken bzw. Institutionen, an denen alle Autoren arbeiten, sowie die vollständige Adresse des federführenden Autors mit Telefon- und Faxnummer sowie e-mail.
   - **Zusammenfassung, Résumé und englischer Abstract (mit Titel der Arbeit):** Ohne Literaturzitate und Akronyme sowie unübliche Abkürzungen (je maximal 250 Wörter).
   - **Text:** Dabei bei Originalarbeiten Gliederung in Einleitung, Methode (inkl. Untersuchungsmaterial, Patienten, Versuchstiere etc., ggf. auch Angabe über Einwilligung bzw. Einhaltung der Deklaration von Helsinki inkl. Votum einer Ethikkommission), Ergebnisse und Diskussion. Abkürzungen sind bei ihrem ersten Erscheinen im Text voll auszuschreiben.
   - **Literaturverzeichnis:** Am Ende der Arbeit werden die Literaturstellen in der im Text zitierten Reihenfolge aufgeführt und nach untenstehendem Muster zitiert. Persönliche Mitteilungen, unveröffentlichte Befunde oder zur Publikation eingereichte Manuskripte werden nicht aufgenommen, sondern entsprechend im Text vermerkt. Zitierungen „im Druck“ bzw. „in press“ beziehen sich nur auf von einer Zeitschrift bereits angenommene Arbeiten (mit Angabe von Zeitschrift und – soweit bekannt – Band und Erscheinungsjahr. Das Zitieren von Arbeiten als „in Vorbereitung“ oder „in preparation“ ist nicht zulässig. Kongressmitteilungen können nur als zitierbare Abstracts oder Beitrag in Proceedings-Bänden berücksichtigt werden.
   - **Tabellen:** Jede Tabelle steht auf einer neuen Seite und hat eine kurze erklärende Überschrift. Abkürzungen oder Zeichen sind in einer Fussnote zu erklären.
   - **Abbildungslegenden:** Die Legende für jede Abbildung steht auf einer neuen Seite; alle Abkürzungen oder Zeichen sind darin zu erklären.
   - **Abbildungen:** Strichzeichnungen, schattierte Zeichnungen oder Fotografien (SW oder Farbe).
   - **Zitierweise:** Zeitschriftenartikel: Daoud AS, Batieha A, Abu-Ekteish F et al. Iron status: a possible risk factor for the first febrile seizure. Epilepsia 2002; 43: 740-743 (bei bis zu vier Autoren werden alle genannt; Abkürzungen der Zeitschriften nach der „List of Journals indexed in Index Medicus“); Bücher: Shorvon S. Status Epilepticus. Its Clinical Features and Treatment in Children and Adults. Cambridge: Cambridge University Press, 1994; Buchkapitel: Holthausen H, Tuxhorn I, Pieper T et al. Hemispherectomy in the treatment of neuronal migrational disorders. In: Kotagal P, Lüders HO (eds): The Epilepsies. Etiologies and Prevention. San Diego, London, Boston et al.: Academic Press, 1999: 93-102

Was ist an die Redaktion einzureichen?

Alle Manuskripte sind inklusive Abbildungen und Tabellen in dreifacher Ausführung einzureichen. Bevorzugt wird eine elektronische Manuskripteinreichung per e-mail (Textverarbeitung: MS Word), alternativ die Zusendung von drei Ausdrucken und einer Diskette (für Abb. und Tab. ist das verwendete Programm anzugeben).

Bildgebungsverfahren bei Epilepsie

Prof. Dr. med. Margitta Seeck

Bildgebung in der Epilepsy wird «klassischerweise» zur Identifizierung und Lokalisation eines epileptogenen Fokus angewandt und umfasst das anatomische MRI, F-Glucose ^{18}F fluoro-deoxyglucose (^{18}FDG) PET und SPECT-Untersuchungen als etablierte Techniken. Diese werden seit >10-15 Jahren erfolgreich bei Patienten zur Diagnostik angewandt, vor allem wenn sie sich einer prächirurgischen Evaluation unterziehen.

In den letzten Jahren hat sich die Bildgebung in der Epileptologie jedoch weiter entwickelt. Zum einen sind die oben genannten Methoden verfeinert worden, wie beispielsweise beim PET. Spezifischere Tracer sind beschrieben worden, mit dem Ziel, den Fokus noch exakter zu lokalisieren und/oder ergänzende Informationen zu bestimmten Epilepsiesyndromen zu bekommen, wie zum Beispiel der autosomal dominanten frontalen nächtlichen Epilepsie, die wahrscheinlich Netzwerke betreffen und weniger eine einzelne Region. Fabienne Picard fasst in ihrem Artikel die neuesten Studien in diesem Gebiet zusammen.

Auch das MRI hat sich vom rein abbildenden anatomischen MRI zu einer Bildtechnik mit funktionellen Informationen weiterentwickelt. Serge Vulliémoz und seine Mitarbeiter diskutieren dies in ihrem Artikel „Diffusion Tension Imaging“. Diese Technik kann Projektionen zwischen und innerhalb der zerebralen Hemisphären visualisieren. Die Relevanz für die Epileptologie ist evident: Verbindungen zwischen klinisch relevanten Strukturen sowie ihre Dichte, im Vergleich zu normalen Personen, können uns helfen, Unterschiede in der Semiologie, neuropsychologische Ausfälle und eventuell auch die Prognose nach einem operativen Eingriff besser zu verstehen. Zum anderen können wichtige Bahnen präoperativ identifiziert und so bei einer Resektion geschont werden.

Der dritte Artikel zur Fokuslokalisation beschreibt Methoden der Konvergenz verschiedener Bildgebungstechniken, und wie dies direkt für die Planung und Ausführung des epilepsiechirurgischen Eingriffs ausgenutzt wird. Zwei erfahrene Neurochirugen aus den Universitätsspitälern Genf (Shahan Momjian) und Lausanne (Claudio Pollo) und ihre Mitarbeiter fassen die „state-of-art“ zusammen.

Ausserdem wurde und wird Bildgebung auch zur Darstellung von kognitiven Funktionen benützt. Da diese im Rahmen von chronischen Epilepsieerkrankungen auch betroffen sein können, sind Kenntnisse darüber, welcher Fokus welche Funtionen in Mitleidenschaft zieht, wünschenswert. In der klinischen Praxis werden Gedächtnis- und Sprachfunktionen am häufigsten untersucht, da Einbussen post-operativ ein signifikantes Handicap werden können. Es gibt jedoch auch andere Funktionen, die vielleicht weniger sichtbar, aber ebenfalls wichtig sind. Dazu gehören Emotionen und ihre Wahrnehmung, welche sich auf die Integrität bestimmter Strukturen stützt. Patrik Vuilleumier und seine Gruppe haben sich auf die Erforschung von emotionellen Prozessen spezialisiert und berichten über Evidenz, dass distinkte Strukturen wie die Amygdala für bestimmte Subprozesse in der Verarbeitung von emotionalen Stimuli und sozialer Wahrnehmung notwendig sind. Die Amygdala ist bei chronischer Temporallappen-Epilepsie, die häufigste fokale Epilepsie, oft pathologisch verändert, so dass sich hier eine direkte Applikation der Erkenntnisse ergibt.

Körperschema-Repräsentationen haben ebenfalls kortikale Korrelate und resultieren aus einem Zusammenspiel von visuellen, somatosensorischen, vestibulären und limbischen Repräsentationen, die sich im temporo-parietalen Kortex austauschen. Autoskopische Erfahrungen, Heautoskopien oder „Out-of-Body“-Erleben, das heisst das Gefühl, über dem eigenen Ich zu schweben, sind seltene Anfallskorrelate, die von Olaf Blanke und Veronica Castillo anhand eines Fallbespiels diskutiert werden.

M. Seeck

Margitta Seeck

Diffusion Magnetic Imaging Applied to Epilepsy

Serge Vulliémoz[1], Reto Meuli[3], Philippe Maeder[3], Margitta Seeck[1] et Jacqueline Delavelle[2]
[1]Unité d'Evaluation Pré-chirurgicale de l'Epilepsie, Clinique de Neurologie, Hôpitaux Universitaires de Genève
[2]Service de Neuro-Radiologie, Département de Radiologie, Hôpitaux Universitaires de Genève
[3]Service de Neuro-Radiologie, Département de Radiologie, Centre Hospitalier Universitaire Vaudois

Summary

Diffusion imaging is a new imaging method based on Magnetic Resonance Imaging (MRI) that allows in vivo measurement of local diffusion properties of water molecules in the brain. Based on the Diffusion Tensor, it is increasingly used to characterize both grey and white matter. This can provide valuable information regarding cellular packing, cellular loss or regional edema in focal status epilepticus. Tractography is a method that reconstructs white matter neural tracts starting from any region studied. These imaging tools are increasingly used in clinical neurology and notably in epilepsy patients to detect subtle structural lesions that could be the cause of the epileptogenic activity. The precise and detailed knowledge of the trajectory of white matter tracts helps to plan difficult epilepsy surgical procedures and to better understand the propagation of epileptic seizures.

Epileptologie 2007; 24: 60 – 65

Key words: Epilepsy, surgery, diffusion MRI, white matter tracts

Diffusions-Bildgebung bei Epilepsie

Die Diffusion-Bildgebung ist eine neue Bildgebungsmethode, die auf Magnet-Resonanz-Imaging (MRI) basiert und die *in vivo*-Messungen der lokalen Diffusionseigenschaften der Wassermoleküle im Gehirn erlaubt. Damit können wertvolle Informationen bezüglich zellulärer Dichte, Zellverlust oder regionale Ödeme durch fokalen Status epilepticus erhoben werden. Die Traktographie ist eine Methode, mit der neuronale Faserbahnen in jeder denkbaren Hirnregion rekonstruiert werden können. Die Bildgebungsmethoden werden mehr und mehr in der klinischen Neurologie und besonders bei Epilepsiepatienten verwandt, um subtile strukturelle Läsionen zu entdecken, die der epileptogenen Aktivität zugrunde liegen könnten. Das präzise und detaillierte Wissen der Bahnen in der weissen Substanz kann hilfreich sein, um schwierige epilepsiechirurgische Interventionen zu planen und die Propagation von epileptischen Anfällen besser zu verstehen.

Schlüsselwörter: Epilepsie, Chirurgie, Diffusions-MRI, weisse Substanz, Bahnen

Imagerie de diffusion appliquée à l'épilepsie

L'imagerie de diffusion est une nouvelle méthode basée sur l'Imagerie par Résonance magnétique (IRM) qui permet de mesurer in vivo les propriétés locales de diffusion des molécules d'eau dans le tissu cérébral. Basée sur le Tenseur de Diffusion, elle est utilisée de façon croissante pour caractériser la substance grise et la substance blanche cérébrale. Des informations importantes concernant la densité ou la perte cellulaire ou encore la présence d'un œdème local dans le cas d'un état de mal épileptique. La tractographie est une méthode de reconstruction des fibres nerveuses dans la substance blanche à partir de n'importe quelle région étudiée. Ces outils d'imagerie sont utilisés de manière croissante en neurologie clinique et notamment chez les patients épileptiques pour détecter des lésions structurelles subtiles sous-jacentes à une maladie épileptique. La connaissance précise et détaillée de la trajectoire des voies dans la substance blanche aide à planifier les interventions difficiles en chirurgie de l'épilepsie et à mieux comprendre la propagation de l'activité épileptique.

Mots clés : Epilepsie, chirurgie, IRM de diffusion, substance blanche, faisceaux d'axones

Introduction

Epilepsy affects 0.5-1% of the general population. Approximately 20% of all epileptic patients are said to be pharmaco-resistant because their seizures are not controlled by drug treatment. In some of these patients, surgical treatment can be proposed and can be superior to long-term drug treatment [1]. A non-invasive presurgical evaluation determines if surgical resection will control the seizures without any major risk of post-operative neurological or cognitive deficit [2, 3]. In patients with normal Magnetic Resonance Imaging (MRI), additional imaging tools are needed to locate the epileptogenic focus. In other patients, the presence of a large le-

sion (malformation, tumor) leads to abnormal development or displacement of important connecting neural pathways, while in other cases, it is the vicinity of important cortical and subcortical networks (motricity, language, vision) that makes surgical procedure very risky. Diffusion imaging and tractography are new developments of MRI that are increasingly involved in clinical diagnostic studies and non-invasive surgical planning and that aid in the management of difficult cases.

This paper presents a brief technical survey of the physical and radiological principles of diffusion and its measurement, followed by a review of the application to epilepsy surgery. Four clinico-radiological vignettes illustrate the potential role of diffusion MRI in diagnostic and treatement of epilepsy, including epilepsy surgery.

Physical and radiological principles underlying diffusion imaging

Diffusion: physical introduction

In the human body, random motion of water molecules is caused by thermal energy. This molecular displacement is called *diffusion*. When the molecules can diffuse equally in all directions of a tridimensional space, the medium is described as *isotropic*, like the free diffusion of a drop of ink in a glass of water, which is limited only by the walls of the glass. In a biological structure, the water molecules are supposed to diffuse freely inside of the intra-cellular space and inside of the extra-cellular space, while the passage from one compartment to the other is limited but not excluded by cellular membranes. In a tissue where the intracellular volume is high compared to extracellular volume, the cell membranes limit long range diffusion compared to a tissue where the extracellular volume predominates. Therefore, the diffusion coefficient will be low in the former tissue and high in the latter. These structural properties can be used to detect regions of high intracellular volume like cell swelling in cytotoxic edema (early status epilepticus, acute stroke, ...) or abnormally packed neurons (disorders of brain development). Similarly, regions of increased extracellular volume can be detected and occur in vasogenic edema (late status epilepticus, subacute stroke) and cellular loss (gliosis).

In a highly organized structure like the brain, nerve fibres are tightly packed in white matter bundles. Therefore, the diffusion is favoured in certain directions and restricted in others because of resistance of the cellular membranes to the crossing of water molecules. The myelin sheets and intra-axonal skeleton (microtubules) seem to play a minor role in the diffusion properties. The diffusion in such structures is called *anisotropic*. A *Diffusion Tensor* is a mathematical representation to describe the diffusion properties of a tissue with 6 variables: 3 for the position at which the diffusion is measured and 3 for principal orthogonal directions to represent anisotropic properties. This Diffusion Tensor can then be used to calculate the *mean diffusivity and fractional anisotropy* (directionality of the motion) [4, 5].

Measurement of diffusion with MRI

Magnetic Resonance Imaging (MRI) offers a unique tool to measure the diffusion properties through *Diffusion Tensor Imaging* (DTI), where additional gradients in the magnetic field are designed to display prominently the diffusion effect. The magnetic properties of the water molecules which move into a given volume element (voxel) during the acquisition sequence will be different from those of immobile molecules (phase shift), causing a decrease of the signal intensity. By measuring the diffusion properties at each position (voxel) in 3 perpendicular directions, the diffusion tensor can be obtained to determine the deriving mean diffusivity and fractional anisotropy. The *Diffusion Weighted Imaging* (DWI), *Apparent Diffusion Coefficient* (ADC) and Fractional Anisotropy (FA) [4 - 6] sequences that are now recorded in routine structural MRI can be derived from this tensor.

Tractography

This is a post-processing method used to display the data obtained from the DTI in order to represent white matter tracts in a 3D image or with colour coding. Starting from a given region of interest, the directions of maximal diffusion, assumed to be the direction of axonal bundles in the white matter, can be followed from one position to the next. In this way, pathways of facilitated water diffusion reflecting white matter neural tracts can be tracked across the brain. These pathways can be started at any “Region Of Interest” (ROI) in the brain: a ROI in the internal capsule or the motor cortex will give an image of the cortico-spinal tract; a ROI in the occipital lobe will give the optical radiation. The main problem of the technique is the measurement of fibre crossing because the diffusion has two “competing” peak-directions and the anisotropy is falsely reduced, making the tracking difficult. Recently, the measurement of diffusion in a greater number of directions has partly overcome the problem. State-of-the-art imaging includes *Diffusion Spectrum Imaging* and *Q-ball Imaging* that are not yet used routinely because of the duration of the acquisition and the need for specific MRI equipment and scientific expertise [4].

Diffusion MRI applied to epilepsy imaging

Structural brain modification associated with seizures

The occurrence of epileptic seizures can produce subtle morphologic changes in the brain. MRI can image these changes and their time course, especially after prolonged (status epilepticus) or very frequent seizures. In the acute phase, during (ictal) or shortly after (post-ictal) the seizure, cytotoxic edema causes cellular swelling, and therefore an increase of the intra-cellular space and water content. Consequently the free diffusion of water molecules is focally reduced and could be imaged through diffusion MRI. Focal swelling is associated with hyperintensity on T2-weighted/FLAIR imaging or reduced ADC coefficient. This phase of cytotoxic edema is followed by another phase of vasogenic edema, where the vessel permeability rises. Thereby, there is an increase of the extra-cellular volume, where water diffuses more easily compared to intra-cellular volume. The ADC coefficient is increased. After single seizures, MRI changes have been described but are less consistent. A study looking at diffusion-weighted focal changes less than an hour after single seizures identified focal changes after 50% of single partial complex and secondary generalized seizures. The involved region corresponded to the putative focus of the seizures only in a minority of the patients suggesting that the method probably revealed networks involved in the seizures rather than the zone of onset [7]. The final evolution can be towards a complete resolution of these changes suggesting only a transitory dysfunction or towards permanent abnormalities in the form of tissue atrophy and gliosis, a cellular loss reflected as an increase of the ADC **(Vignette 1)**. A progression of these changes toward MRI changes compatible with hippocampal sclerosis can be seen after limbic status epilepticus **(Vignette 2)**. The detection of the permanent structural abnormalities can be sometimes seen already after 2 months (hippocampal sclerosis) even in the absence of acute modifications of the MRI signal. On the other hand, resolution of the diffusion abnormalities can be seen after status epilepticus, preceding or following functional recovery. A precise knowledge of the timing of these changes needs to be addressed with serial imaging in larger group of subjects.

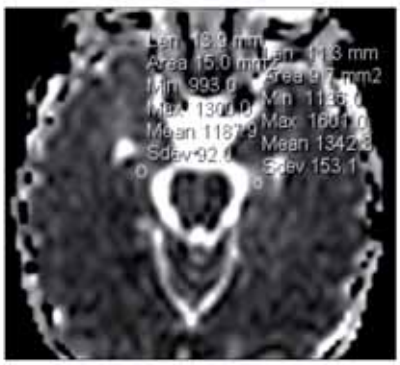

Vignette 1: Hippocampal lesion in temporal lobe epilepsy: Map of Apparent Diffusion Coefficient (ADC) in a patient with left-sided hippocampal sclerosis (axial view). The value of Mean ADC is higher on the affected side (1342.8 ± 153.1 vs 1187.9 ± 92) probably in relation to cellular loss and gliosis that increase the extracellular space.

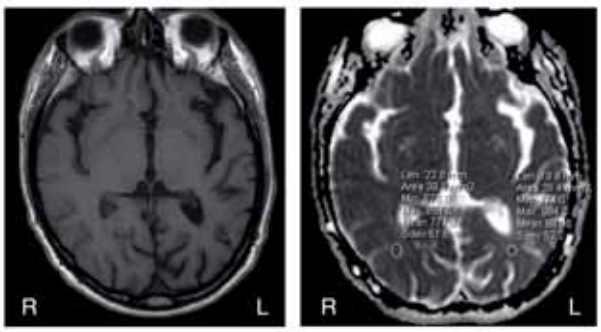

Vignette 2: High sensitivity of diffusion images in cryptogenic epilepsy: This 46 year-old patient suffers from chronic left-sided temporo-occipital status epilepticus of cryptogenic origin. T1-weighted image shows only a discrete left-sided cortical and subcortical atrophy (axial view, left panel). The ADC map shows significantly higher values of Mean ADC in the left than right temporo-occipital white matter (891.6 ± 52.2 vs 777.9 ± 51.6; axial view, right panel). This allows more precise localisation of the structural abnormalities and precise monitoring of the disease.

Lateralisation and localisation of the epileptogenic focus

One of the biggest expectations, regarding any new imaging tool involved in presurgical work-up of epilepsy, is that this new tool could help localizing the epileptogenic focus or any underlying structural abnormality that was not revealed by other imaging tests. “Interictal” and “post-ictal” imaging can be useful localizing subtle lesions and epileptogenic foci and they can be of great help if the standard imaging tests are normal or show multiple abnormalities.

In the case of temporal lobe epilepsy, lateralisation of the focus with the help of diffusion imaging was highly correlated with the presence of unilateral hippocampal sclerosis on conventional MRI but could not help to lateralize the focus when the conventional MRI was not conclusive [8]. In extra-temporal epilepsy, reports describe diffusion abnormalities in brain regions compatible with the seizure electro-clinical pattern in patients that have normal conventional MRI [8, 9]. Resection and histopathological analysis revealed subtle gliosis and a very good outcome confirming that the seizure onset zone was linked with the diffusion abnormalities [10].

In temporal lobe epilepsy with unilateral hippocampal sclerosis, diffusion imaging showed that structural abnormalities extend far beyond the sclerotic hippocampus to involve large regions on the ipsilateral temporal lobe, contralateral hippocampus and even frontal areas. However, these extensive findings do not seem to indicate a worse surgical outcome [11] and could even be reversible: in about half of the patients who underwent temporal lobe surgery and became seizure free, post-operative imaging showed a resolution of the diffusion abnormalities in the contralateral hippocampus [12]. In an interesting study with diffusion MRI in patients investigated with intracerebral electrodes, ADC abnormalities (probably reflecting gliosis or cellular loss) were better correlated with seizure onset zones than FA abnormalities that reflected rather a distant disorder of white matter connections. Moreover, the correlation was better in extra-temporal epilepsy (83%) than in temporal epilepsy (20%). Thus, diffusion imaging could help to choose electrode placement in difficult cases of cryptogenic partial epilepsy [13].

In patients with temporal lobe epilepsy, some studies show a correlation between findings of DTI and clinical characteristics: interictal psychosis correlates with lower FA in both frontal and temporal regions, higher mean diffusivity in bilateral frontal regions [14]; epigastric aura is associated with lower diffusivity ipsilateral to the epileptogenic focus and a positive history of febrile seizure is associated with bilateral higher anisotropy [15].

Trauma and post-traumatic epilepsy

Increase of the mean diffusivity and decrease of the fractional anisotropy can be measured in widespread brain regions after brain trauma and the affected territories can be much more extensive than those seen on standard MR images. These changes reflect cell loss, diffuse axonal injury and secondary Wallerian degeneration in the corresponding regions, allowing to map precisely the post-traumatic damages [16]. Moreover, a greater extent of the abnormalities observed with diffusion imaging seem to be correlated with a greater risk of developing post-traumatic epilepsy [17].

Brain development and congenital malformations

Diffusion imaging is particularly promising to study patterns of brain development. Increases in fractional anisotropy precede the appearance of myelin. Decrease in ADC reflects the progressive increase of the size of neurons and glial cells.

Diffusion imaging is therefore very informative in developmental disorders. It can reveal very subtle areas of *cortical dysplasia* through changes in mean diffusivity reflecting abnormally packed cells or through abnormal anisotropy of the underlying white matter bundles, caused either by disturbed connectivity or by ectopic neurons located in the white matter [18, 19]. The abnormal pattern seen in diffusion imaging is often more extensive than the malformation seen on standard MRI. This suggests that the malformed area and possibly the epileptogenic focus may not be restricted to abnormal regions seen on standard MRI. This reflects histopathological findings that show more widespread abnormal tissue than the extent seen on MRI. It could also explain the frequent bad outcome of epilepsy surgery in patients with cortical dysplasia or periventricular heterotopia.

Periventricular Nodular Heterotopia (PNH) or *Band Heterotopia* (BH) is a condition where some neurons did not migrate from the subependimal region toward the cortex, but stayed packed around the ventricule or in the subcortical regions, sometimes producing an appearance of “double cortex”. In these patients, epilepsy can arise from the heterotopia themselves or from other brain regions that appear normal on the standard MRI. Histopathological studies show that there are generally other sites of brain development disorder, either in the overlying cortex or at distant sites [20, 21]. The study of the connectivity of those structures indicates that white matter tracts run through or end within the band heterotopia [22], confirming histopathological studies and the fact that there is often no focal neurological deficit in these patients.

The precise description of the abnormal trajectory or morphology of the main white matter tracts with the help of tractography is also very important when epilepsy surgery is contemplated in a patient with a disorder of brain development. Isolated cases of various origins (cerebral palsy, agenesis of the corpus callosum, schizencephaly, polymicrogyria and other pediatric encephalopathies) are well documented in the literature [23 - 26].

Another particulary interesting condition is *Tuberous Sclerosis*, a genetic condition with skin lesions and multiple cerebral malformative lesions (tubers) that can be very epileptogenic. However, the phenotype is not strongly related to conventional MR patterns. Epilepsy surgery can sometimes significantly improve the seizures if the epileptogenic tuber can be identified even though the malformations are diffuse and multifocal. Interestingly, epileptogenic tubers have increased ADC values in the white matter underlying them, when compared to non-epileptogenic tubers, whereas the largest tuber identified by conventional and decreased FA values was less accurate [27, 28].

Tractography

In case of neurosurgical procedures in the context of a large lesion or malformation, the anatomical pathways might follow unusual trajectories or start

from atypical cortical regions. The in vivo representation of important white matter tracts, such as the cortico-spinal tract, can greatly help neurosurgical intervention for epilepsy or any other indication **(Vignette 3)**. In temporal lobe epilepsy surgery, the main feared complication, besides memory decline, is post-operative visual field defect. This defect is correlated with the extent of temporal lobe that is removed (from the anterior pole) but individual variation can be important. A recent study showed that the optical radiation can be represented for individual patients and that a patient with a resection volume including part of the radiation had a post-

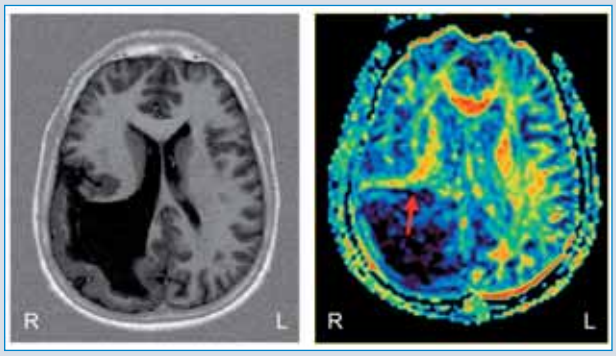

Vignette 3: Tractography for surgical planning: 30 year-old patient with pharmaco-resistant complex partial epilepsy in the context of a posterior hemi-hemi-megalencephaly (axial T1-weighted image, left panel). The neurological exam is normal. Diffusion Tensor Imaging (axial view, right panel,) shows the localization of the cortico-spinal tracts that is anterior to the malformation (red arrow). A mutilobar parieto-temporo-occipital resection starting posterior to the central sulcus was performed. The patient is seizure free since then and suffers only from a mild visual field deficit.

operative visual deficit whereas another with surgery sparing the radiation did not [29]. Tractography of the optical radiation, as well as other white matter bundles of nervous fibers can thus be used to tailor neurosurgical interventions. A patient with an epileptogenic malformation (periventricular nodular heterotopia) adjacent to the optical radiation also benefited from tractography of this radiation to allow a safe resection of the epileptogenic malformation with no post-operative deficit [30]. In case of cortical development disorders, aberrant white matter connections could lead to atypical seizure propagation, and discordant results of non-invasive imaging tests used to locate the epileptogenic focus **(Vignette 4)**.

Diffusion imaging also gives insight into functional organisation of the brain in healthy subjects and epileptic patients. In epileptic patients with atypical language lateralisation, structural diffusion tensor imaging revealed an asymmetric fraction of anisotropy, with lower values in the left hemisphere, which was not found in other patients without atypical language organisation. Moreover, the mapping of tracts from or to a specific cortical area gives information about the connections and neuronal network involved. The corticospinal tract can be tracked down from the motor cortex defined by fMRI [31].

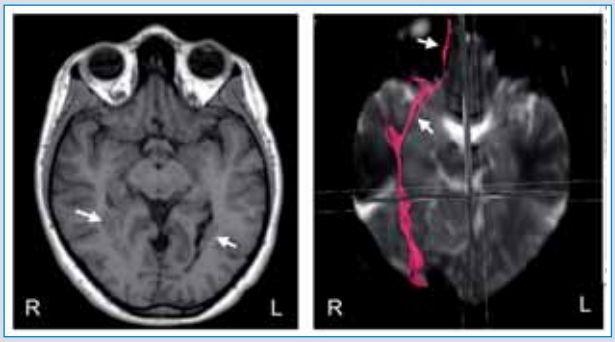

Vignette 4: Tractography from periventricular nodular heterotopia. This 25 year-old woman suffers from weekly complex partial hypermotor seizures suggesting fronto-temporal seizures. A non-invasive presurgical work-up revealed bilateral brain developmental disorder in the form of bilateral periventricular nodular heterotopia (white arrows, T1-weighted image, left panel). The ictal/interictal EEG neuropsychological tests and ictal SPECT showed a bilateral anterior temporal focus with right predominance. This axial view shows the tracking of white matter fibres from/to the heterotopia. The tracts project anteriorly towards the orbito-frontal and anterior temporal structures suggesting aberrant connectivity (pink tract with white arrows, left panel). This could help understand the discrepancy between the results of the different tests. A posterior projection from the heterotopia is also present and seems to connect the heterotopia with the visual cortex.

Future perspectives

In epilepsy surgery planning, the precision of tractography will increase with the development of algorithms solving the problem of fibre crossing. The knowledge of the white matter tracts will be combined with other imaging modalities into neuro-navigation devices helping the monitoring of surgery with imaging during the operation and predicting the occurrence of post-operative deficits, especially when combined with brain areas activated during fMRI tasks.

In research, tractography of the nervous fibres connecting varying brain areas could be assessed by fMRI or EEG to study their functional connectivity in cognitive or other brain functions. Recent studies even suggest that diffusion MRI could detect changes related to the activity of cortical neurons and could therefore be used as a functional imaging tool [32]. Moreover, knowledge of the electrical conductivity assessed by diffusion MRI will enable more precise models of the seizure propagation in fundamental neuroscience research [33].

Conclusion

Diffusion MRI and tractography are new MRI methods, relying on the displacement properties of the water molecules in the brain that are entering research and clinical activity at a tremendous pace. The improvement of the imaging of fibre crossing and of the time necessary to obtain a good quality image allows very sensitive detection of structural and functional abnormalities as well as the representation of nervous fibres in the brain. More research is needed to understand precisely the meaning of abnormal results and how they are causally related to epilepsy.

References

1. *Wiebe S, Blume WT, Girvin JP, Eliasziw M. A randomized, controlled trial of surgery for temporal-lobe epilepsy. N Engl J Med 2001; 345: 311-318*
2. *Blume WT, Parrent AG. Assessment of patients with intractable epilepsy for surgery. Adv Neurol 2006; 97: 537-548*
3. *Koepp MJ, Woermann FG. Imaging structure and function in refractory focal epilepsy. Lancet Neurol 2005; 4: 42-53*
4. *Hagmann P, Jonasson L, Maeder P et al. Understanding diffusion MR imaging techniques: From scalar diffusion-weighted imaging to diffusion tensor imaging and beyond. Radiographics 2006; 26(Suppl 1): S205-223*
5. *Tuch DS, Reese TG, Wiegell MR, Wedeen VJ. Diffusion MRI of complex neural architecture. Neuron 2003; 40: 885-895*
6. *Pierpaoli C, Jezzard P, Basser PJ et al. Diffusion tensor MR imaging of the human brain. Radiology 1996; 201: 637-648*
7. *Salmenpera TM, Symms MR, Boulby PA et al. Postictal diffusion weighted imaging. Epilepsy Res 2006; 70: 133-143*
8. *Wehner T, Lapresto E, Tkach J et al. The value of interictal diffusion-weighted imaging in lateralizing temporal lobe epilepsy. Neurology 2007; 68: 122-127*
9. *Hakyemez B, Erdogan C, Yildiz H et al. Apparent diffusion coefficient measurements in the hippocampus and amygdala of patients with temporal lobe seizures and in healthy volunteers. Epilepsy Behav 2005; 6: 250-256*
10. *Rugg-Gunn FJ, Eriksson SH, Symms MR et al. Diffusion tensor imaging in refractory epilepsy. Lancet 2002; 359: 1748-1751*
11. *Gross DW, Concha L, Beaulieu C. Extratemporal white matter abnormalities in mesial temporal lobe epilepsy demonstrated with diffusion tensor imaging. Epilepsia 2006; 47: 1360-1363*
12. *Thivard L, Tanguy ML, Adam C et al. Postoperative recovery of hippocampal contralateral diffusivity in medial temporal lobe epilepsy. Epilepsia 2007; 48: 599-604*
13. *Thivard L, Adam C, Hasboun D et al. Interictal diffusion MRI in partial epilepsies explored with intracerebral electrodes. Brain 2006; 129: 375-385*
14. *Flugel D, Cercignani M, Symms MR et al. Diffusion tensor imaging findings and their correlation with neuropsychological deficits in patients with temporal lobe epilepsy and interictal psychosis. Epilepsia 2006; 47: 941-944*
15. *Thivard L, Lehericy S, Krainik A et al. Diffusion tensor imaging in medial temporal lobe epilepsy with hippocampal sclerosis. Neuroimage 2005; 28: 682-690*
16. *Wieshmann UC, Symms MR, Clark CA et al. Blunt-head trauma associated with widespread water-diffusion changes. Lancet 1999; 353: 1242-1243*
17. *Gupta RK, Saksena S, Agarwal A et al. Diffusion tensor imaging in late posttraumatic epilepsy. Epilepsia 2005; 46: 1465-1471*
18. *Eriksson SH, Rugg-Gunn FJ, Symms MR et al. Diffusion tensor imaging in patients with epilepsy and malformations of cortical development. Brain 2001; 124: 617-626*
19. *Gross DW, Bastos A, Beaulieu C. Diffusion tensor imaging abnormalities in focal cortical dysplasia. Can J Neurol Sci 2005; 32: 477-482*
20. *Aghakhani Y, Kinay D, Gotman J et al. The role of periventricular nodular heterotopia in epileptogenesis. Brain 2005; 128: 641-651*
21. *Tassi L, Colombo N, Cossu M et al. Electroclinical, MRI and neuropathological study of 10 patients with nodular heterotopia, with surgical outcomes. Brain 2005; 128: 321-337*
22. *Eriksson SH, Symms MR, Rugg-Gunn FJ et al. Exploring white matter tracts in band heterotopia using diffusion tractography. Ann Neurol 2002; 52: 327-334*
23. *Huisman TA, Klein A, Werner B et al. Serial MR imaging, diffusion tensor imaging, and MR spectroscopic findings in a child with progressive encephalopathy, edema, hypsarrhythmia, and optic atrophy (PEHO) syndrome. AJNR Am J Neuroradiol 2006; 27: 1555-1558*
24. *Lim CC, Yin H, Loh NK et al. Malformations of cortical development: high-resolution MR and diffusion tensor imaging of fiber tracts at 3T. AJNR Am J Neuroradiol 2005; 26: 61-64*
25. *Takanashi J, Oba H, Barkovich AJ et al. Diffusion MRI abnormalities after prolonged febrile seizures with encephalopathy. Neurology 2006; 66: 1304-1309; discussion 1291*
26. *Trivedi R, Gupta RK, Hasan KM et al. Diffusion tensor imaging in polymicrogyria: a report of three cases. Neuroradiology 2006; 48: 422-427*
27. *Chandra PS, Salamon N, Huang J et al. FDG-PET/MRI coregistration and diffusion-tensor imaging distinguish epileptogenic tubers and cortex in patients with tuberous sclerosis complex: a preliminary report. Epilepsia 2006; 47: 1543-1549*
28. *Jansen FE, Braun KP, van Nieuwenhuizen O et al. Diffusion-weighted magnetic resonance imaging and identification of the epileptogenic tuber in patients with tuberous sclerosis. Arch Neurol 2003; 60: 1580-1584*
29. *Powell HW, Parker GJ, Alexander DC et al. MR tractography predicts visual field defects following temporal lobe resection. Neurology 2005; 65: 596-599*
30. *Stefan H, Nimsky C, Scheler G et al. Periventricular nodular heterotopia: A challenge for epilepsy surgery. Seizure Epub 2006; Nov 28*
31. *Guye M, Parker GJ, Symms M et al. Combined functional MRI and tractography to demonstrate the connectivity of the human primary motor cortex in vivo. Neuroimage 2003; 19: 1349-1360*
32. *Le Bihan D. Looking into the functional architecture of the brain with diffusion MRI. Nat Rev Neurosci 2003; 4: 469-480*
33. *Akhtari M, Salamon N, Duncan R et al. Electrical conductivities of the freshly excised cerebral cortex in epilepsy surgery patients; correlation with pathology, seizure duration, and diffusion tensor imaging. Brain Topogr 2006; 18: 281-290*

Address for correspondence:
Dr Serge Vulliémoz
Unité d'Evaluation préchirurgicale de l'Epilepsie
Clinique de Neurologie
Hôpitaux Universitaires de Genève
1211 Genève 14
Tel. 0041 22 372 8376
Fax 0041 22 372 8375
Serge.Vulliemoz@hcuge.ch

New PET Tracers in Epilepsy

Fabienne Picard,
Department of Neurology, HUG, Geneva

Summary

The current aim of positron emission tomography (PET) investigation in pharmacoresistant epileptic patients is the in vivo study of the neurotransmission abnormalities underlying neuronal hyperexcitability, with the hope of better delineating the epileptogenic zone non-invasively. This approach is based on the binding of various radioligands on specific receptors, such as $GABA_A$, serotonine, opiate receptors, or on the brain uptake of radioactive neurotransmitter precursors. Although promising studies have been reported, at the present state, the PET studies using these new tracers are confined to research in a few centres and their clinical role and utility in presurgical assessment of pharmacoresistant focal epilepsies are difficult to evaluate, partly due to the lack of large multicentric controlled studies. The new and very latest PET tracers studies will be reviewed.

Epileptologie 2007; 24: 66 – 72

Key words: Epilepsy, PET, radiotracer, neurotransmission

Neue PET-Tracer bei Epilepsie

Das Ziel der Positron-Emissions-Tomographie (PET)-Studien in der Untersuchung von pharmakoresistenten epileptischen Patienten ist die in vivo-Charakterisierung von Neurotransmitteranomalien, die der neuronalen Übererregbarkeit zugrunde liegen, in der Hoffnung, so die epileptogene Zone besser zu bestimmen. Diese Methode basiert auf der Bindung von Radioliganden mit spezifischen Rezeptoren, wie $GABA_A$, Serotonin, Opiat-Rezeptoren, oder auf der zerebralen Aufnahme von Neurotransmitter-Vorstufen. Obwohl viel versprechende Studienresultate berichtet wurden, sind PET-Untersuchungen mit neuen Tracern wenigen Forschungszentren vorbehalten, und ihre klinische Rolle und Nützlichkeit ist aufgrund mangelnder multizentrischer kontrollierter Studien noch schwierig zu beurteilen. Die neuesten PET-Tracer-Studien werden hier besprochen.

Schlüsselwörter: Epilepsie, PET, Radiotracer, Neurotransmission

Les nouveaux traceurs PET en épileptologie

Un des buts actuels des investigations par tomographie à émission de positons (PET) chez les patients épileptiques pharmacorésistants est l'étude in vivo des anomalies de neurotransmission qui sous-tendent l'hyperexcitabilité neuronale, avec l'espoir de mieux délimiter, d'une manière non invasive, la zone épileptogène. Cette approche est basée sur la liaison de divers radioligands sur des récepteurs spécifiques, tels que les récepteurs $GABA_A$, sérotonine, opiacés, ou sur la captation cérébrale de précurseurs de neurotransmetteur radioactifs. Bien que des études prometteuses aient été rapportées, à l'heure actuelle les études PET utilisant ces nouveaux traceurs sont limitées à de la recherche dans quelques centres et il est difficile d'évaluer leur rôle et utilité cliniques dans l'évaluation préchirurgicale des épilepsies focales pharmacorésistantes, en particulier en raison du manque de larges études multicentriques contrôlées. Cet article passe en revue les nouveaux traceurs PET existant pour les divers systèmes de neurotransmission.

Mots clés : Epilepsie, PET, radiotraceurs, neurotransmission

Introduction

Positron emission tomography (PET) has been the first functional neuroimaging technique applied to presurgical evaluation of pharmacoresistant focal epilepsies, in the late seventies, before MRI was available. It used the fluorodeoxyglucose labeled with ^{18}F isotope (^{18}FDG) to obtain images of interictal brain glucose metabolism. It was particularly useful in patients with a normal brain CT scan, showing a focal interictal glucose hypometabolism. Today ^{18}FDG PET remains a routinely used examination in the presurgical assessment of drug refractory focal epilepsies. Another objective of PET investigation which has been progressively developed, is to get images of neurotransmission abnormalities underlying neuronal hyperexcitability. This requires radioactively labeled tracers which are either ligands of specific receptors or neurotransmitter precursors. Thus, one of the most promising applications of PET in epilepsy studies consists of imaging the distribution of brain receptors in the interictal state. The most widely used PET ligand in epilepsy at present is the selective antagonist of $GABA_A$ receptors, [^{11}C]-flumazenil. A localized reduction of [^{11}C]-flumazenil binding, closely correlating with the side and site of seizure onset, is usually observed in patients with refractory focal seizures. This reduced binding is thought to largely reflect an underlying neuronal loss, as demonstrated in temporal lobe epilepsy associated with mesial temporal sclerosis (review in [1]).
Less known specific ligands or precursors usable for PET studies are now available for various neurotransmitter and neuromodulator systems including the serotonin, dopamine, glutamate/NMDA, nicotinic acetylcholine, adenosine and opioid systems. The PET studies using these new tracers are confined to research in a few centers and are

not in routine clinical use. Obviously, no epilepsy center has the capacity of developing all the tracers. Large multicentric controlled studies are lacking and to date no PET technique has proved its capacity to map the epileptogenic zone with enough precision to guide cortical resection. This paper will present an overview of the new tracers and describe their potential in clinical and experimental epileptology. Most of the reported studies have used statistical parametric mapping (SPM) for the statistical analyses of the data.

I. Serotonin system

The serotonin system originates from the raphe nuclei, with widespread projections to the whole CNS. Studies in experimental models of epilepsy have suggested an inhibitory role of serotonin (5-HT) on epileptiform discharges [2, 3] and antiepileptic and anticonvulsant properties of 5-HT_{1A} receptor activation in rodents [4]. The anti-seizure effects of 5-HT_{1A} receptor activation is blocked by the highly selective 5-HT_{1A} antagonist WAY-100635 [5]. It is interesting to note that enhanced serotoninergic innervation has been described in the epileptogenic tissue of patients with cortical dysplasia [6].

I.1. α[^{11}C]methyl-L-tryptophan (AMT)

Serotonin is synthesized from the neutral amino acid L-tryptophan. Several lines of evidence support the validity of alpha-methyl tryptophan (AMT) as a tracer for measuring the rate of serotonin synthesis. PET studies using AMT have been performed in different epileptic populations. One of the main advantages of using PET with AMT for imaging in epilepsy is that it shows increased (rather than decreased) uptake in epileptic foci. The basis for increased AMT uptake in patients with epilepsy has not been completely elucidated.

Several studies have demonstrated the unique ability of AMT PET to successfully identify the epileptogenic tuber(s) in patients with tuberous sclerosis and intractable epilepsy [7 - 10]. AMT PET scanning shows locally increased uptake of AMT in and around the epileptogenic tuber, while it shows normal or decreased uptake in non-epileptogenic tubers [9]. Theses findings are not related to nonspecific changes in perfusion or metabolism (lack of changes with interictal markers of blood flow or markers of metabolism). In a study of 17 children who underwent resective epilepsy surgery following AMT PET, the tuber with the highest uptake was located in an ictal EEG onset region in each patient [10]. Tubers with at least 10% increase of AMT uptake proved to be epileptogenic based on intracranial EEG and outcome criteria. The different studies demonstrated that resection of tubers with increased AMT uptake is essential to achieve seizure-free surgical outcome in these patients.

The occurrence of increased AMT uptake is higher in patients with histologically proven cortical dysplasia compared to those with nonspecific pathological changes (i.e. gliosis) [11]. This correlates with previous human epileptic tissue studies showing serotoninergic hyperinnervation in dysplastic tissues [6]. In patients with intractable epilepsy and cortical dysplasia, the increased uptake of AMT was shown to be highly co-localized to the area of neocortical seizure onset defined on electrocorticography. Remote cortex involved in seizure propagation does not appear to show increased uptake on AMT PET images. In contrast, the regions of reduced metabolism on ^{18}FDG PET are widespread and nonspecific.

Increased AMT uptake was also found in a very high proportion of epileptogenic brain tumors, including low-grade gliomas and dysembryoplastic neuroepithelial tumors, but it is not always related to epileptogenicity as it has also been observed in some gliomas not associated with seizures [12].

It appears that AMT PET has a lower sensitivity for the localization and lateralization of epileptic foci in patients with cryptogenic focal epilepsy. However increased focal uptake of AMT may be observed in a proportion of patients with no detectable lesion on MRI and can be a valuable addition to current methods of investigation [13]. One study showed that AMT PET might be useful for lateralizing the epileptic focus in patients with temporal lobe epilepsy (TLE) and normal hippocampal volumes: an increased AMT uptake was shown in the hippocampus ipsilateral to the seizure focus in a group of seven TLE patients with normal hippocampal volumes [14]. However other larger studies are needed to further substantiate the clinical use of AMT PET in evaluation of patients with suspected TLE and no signs of hippocampal sclerosis on MRI.

Lastly, AMT PET was shown to be a useful imaging approach for identification of non-resected epileptic cortex in patients with a previously failed neocortical epilepsy surgery [15]. It is proposed to wait at least 2 months after surgery before scanning the patients.

The conclusion of these studies is that AMT is a useful tracer in the presurgical evaluation of patients with epilepsy and that it displays a particularly high specificity for the dysplastic lesions of tuberous sclerosis or cortical dysplasia.

I.2. Ligands of 5-HT_{1A} receptors

The 5-HT_{1A} receptors constitute the best characterized subtype of currently known 5-HT receptors.

I.2.1. [^{11}C]-WAY-100635 and [^{18}F]-FCWAY

[^{11}C]-WAY is an antagonist ligand of 5-HT_{1A} receptors. It is very specific with a much higher affinity than endogenous serotonin for 5-HT_{1A} receptors (Kd in the range of 20 pmol), so [^{11}C]-WAY does not interact with serotonin.

PET using [^{11}C]-WAY-100635 was performed in patients

with severe mesial temporal lobe epilepsy (MTLE) to test the hypothesis that in MTLE there is involvement of serotonin systems outside of mesial structures, suggesting a mechanism for affective symptoms in this population [16]. Fourteen patients (6 with left-, 8 with right-sided mesial temporal lobe focus) and 14 controls were studied. The 5-HT_{1A} receptor binding potential was calculated for hippocampus, amygdala, orbitofrontal, insular, lateral temporal, anterior cingulate cortex, raphe nuclei, and in two regions presumably uninvolved in the epileptogenic process (parietal, and dorsolateral frontal neocortex). The 5-HT_{1A} binding was significantly reduced in the epileptogenic hippocampus and amygdala ($p = 0.0001$) in all patients, including the six with normal [^{18}F]-FDG PET and MRI. It was also reduced in the anterior cingulate, insular, and lateral temporal cortex ipsilaterally to the focus, in contralateral hippocampus, and in the raphe nuclei. Thus the reduced 5-HT_{1A} receptor binding potential was observed in the EEG focus and its limbic connections. According to the authors, the affective symptoms in MTLE may result from reductions in 5-HT_{1A} binding in the insular and cingulate cortex. In conclusion, [^{11}C]-WAY-100635 PET may provide additional information to EEG, [^{18}F]-FDG PET, and MRI when evaluating patients with intractable seizures.

PET using [^{11}C]-WAY-100635 was also performed in 12 patients with juvenile myoclonic epilepsy (Savic, personal communication, "The new and very new PET tracers in epilepsy", Satellite symposium to the 26th IEC, Orsay, Paris). There was a 25% reduction of 5-HT_{1A} binding in the dorsolateral prefrontal cortex. It is worth noting that the same patients were investigated with MR spectroscopy showing reduction in N-acetylaspartate (NAA) in the dorsolateral prefrontal cortex, and also had impaired working memory. In addition, an unexpected finding was a bilateral reduction of [^{11}C]-WAY-100635 binding in the hippocampus, despite hippocampal volumes which were not decreased and despite normal grey matter fraction. The authors suggest that 5-HT_{1A} receptor binding could be a useful approach in future to detect potential hippocampal changes which are not visible on MRI in neocortical epilepsies, generalized epilepsies or in psychiatric disorders.

[^{18}F]-FCWAY presents an affinity for 5-HT_{1A} receptors comparable to that of the original WAY-100635 labeled with ^{11}C. A PET study with [^{18}F]-FCWAY showed decreased temporal 5-HT_{1A} binding ipsilateral to seizure foci in patients with TLE [17]. A complementary study demonstrated that decreased 5-HT_{1A} binding in insula and mesial temporal structures ipsilateral to temporal lobe epileptic foci is not an artifact related to partial volume effect because of the mesial temporal sclerosis and structural atrophy [18]. The studies suggest that the receptor loss may be part of the initial phase of neuronal dysfunction in TLE, followed by hypometabolism and eventual structural atrophy. The decrease in 5-HT_{1A} binding exceeded both ^{18}FDG hypometabolism and hippocampal atrophy, and could be detected in mesial temporal regions in patients with normal MRI. Thus [^{18}F]-FCWAY PET might be particularly useful for early detection of functional abnormalities in TLE patients.

I.2.2. [^{18}F]-MPPF

MPPF (4-(2'-methoxyphenyl)-1-[2'-[N-(2''-pyridinyl)-p-fluorobenzamido]ethyl]-piperazine) is another selective antagonist of 5-HT_{1A} receptors. It has an affinity close to that of endogenous serotonin for 5-HT_{1A} receptors and is thus sensitive to endogenous serotonin variations. Thus a decrease of [^{18}F]-MPPF binding can be interpreted as reflecting either a decrease in receptor density or an increase of endogenous serotonin, resulting in a competition for receptor binding by the radioligand.

PET studies with [^{18}F]-MPPF carried out in a group of TLE patients with hippocampal ictal onset showed significant decreases ipsilateral to the epileptogenic zone in the hippocampus, temporal pole, insula and temporal neocortex [19, 20]. It was concluded from these data that the decrease in 5-HT_{1A} receptor binding in epileptic patients could reflect the loss of neurons in the hippocampus. However, this interpretation has recently been challenged by the report in epileptic foci of an increase in P-glycoprotein, an ATP-driven transmembrane efflux pump, known to strongly regulate the penetration of [^{18}F]-MPPF in the brain [21]. The binding of [^{18}F]-MPPF might be modified by extracellular 5-HT levels, internalization of 5-HT_{1A} receptors and the expression of P-glycoproteins. So, although [^{18}F]-MPPF proves a successful 5-HT_{1A} receptor imaging agent, the development of novel 5-HT_{1A} PET radioligands will be required to further characterize 5-HT neurotransmission and 5-HT_{1A} receptors in human brain [22].

II. Dopamine system

Studies in animal models and epileptic patients have suggested that circuits of the basal ganglia may control epileptic seizures and that striatal dopaminergic transmission plays a key role in seizure interruption [23]. In addition, there is evidence from clinical experience that antagonizing D2 receptors lowers seizure threshold.

II.1. [^{18}F]-fluoro-L-Dopa

[^{18}F]-fluoro-L-Dopa is a radiotracer that permits measurements of presynaptic dopaminergic function. A [^{18}F]-fluoro-L-Dopa PET study was performed in patients with a ring chromosome 20 epilepsy, characterized by long-lasting seizures suggesting a dysfunction in the seizure control system. It showed a significantly decreased uptake in both putamen and caudate nucleus, indicating that a dysfunction of the striatal dopamine neurotransmission may impair the mechanisms that interrupt seizures [24].

Thereafter, patients with generalized seizures and patients with focal seizures related to hippocampal sclerosis were studied [25]. There was a decreased [^{18}F]-fluoro-L-DOPA uptake, especially in the substantia nigra bilaterally, in all patients. [^{18}F]-fluoro-L-DOPA uptake was also decreased in the putamen, bilaterally, in patients with gene-

Periphere neuropathische Schmerzen

Im Strudel des Schmerzes…

…endlich Ruhe finden

LYRICA®
PREGABALIN

- *Schnelle Wirkung – ohne Titration*[1]
- *Starke Wirkung*[1]
- *Einfach – 2 x täglich 1 Kapsel*[2]

Referenzen: 1 Freynhagen R et al. Efficacy of pregabalin in neuropathic pain evaluated in a 12-week, randomised, double-blind, multicentre, placebo-controlled trial of flexible- and fixed-dose regimens. Pain 2005; 115: 254-263 **2** Arzneimittel-Kompendium der Schweiz

Gekürzte Fachinformation Lyrica® (Pregabalin)
Indikation: Periphere neuropathische Schmerzen. Epilepsie: Zur Zusatztherapie von partiellen Anfällen mit oder ohne sekundäre Generalisierung bei Patienten, die auf andere Antiepileptika ungenügend ansprechen. **Dosierung:** Anfangsdosis: 150 mg verabreicht in 2 oder 3 Einzeldosen. Maximale Erhaltungsdosis: 600 mg in 2 oder 3 Einzeldosen. Dosisreduktion bei eingeschränkter Nierenfunktion. **Kontraindikationen:** Überempfindlichkeit gegenüber einem der Inhaltsstoffe. **Vorsichtsmassnahmen:** Leber- und schwere Nierenfunktionsstörungen, Herzinsuffizienz, sedativer Effekt bei älteren Patienten; Schwangerschaft, Stillzeit. **Interaktionen:** Es ist unwahrscheinlich, dass Pregabalin pharmakokinetischen Wechselwirkungen unterliegt, es kann aber die Wirkung von Oxycodon, Lorazepam und Ethanol verstärken. **Häufigste unerwünschte Wirkungen:** Benommenheit, Schläfrigkeit. **Packungen:** Kapseln 25 mg: 14; 50 mg: 84; 75 mg: 14 und 56; 100 mg: 84; 150 mg: 56 und 168; 200 mg: 84; 300 mg: 56 und 168. Verkaufskategorie B. **Zulassungsinhaberin:** Pfizer AG, Zürich. Weitere Angaben siehe Arzneimittel-Kompendium der Schweiz.

Pfizer AG
Schärenmoosstr. 99
8052 Zürich

LPD 15DEC05

66640-160-Jan07

TRILEPTAL®
Oxcarbazepin

UNBESCHWERT und FREI

Als **einziges neueres Antiepileptikum** bereits bei **Säuglingen** (ab 1 Monat) zugelassen

Trileptal® – das moderne Antiepileptikum* ab 1 Monat[1]

- **hoch wirksam:** effektive Anfallskontrolle[2–4]
- **gute Verträglichkeit** schon bei Säuglingen ab 1 Monat[2, 5–8]
- **einfach anwendbar** bei Säuglingen, Kindern und Erwachsenen[8–10]

* bei partieller Epilepsie mit oder ohne sekundärer Generalisation bei generalisierten tonisch-klonischen Anfällen

1 Piña-Garza JE, et al. Oxcarbazepine as adjunctive therapy is effective and safe in infants and very young children with inadequately controlled partial seizures
2 Bill PA, et al. A double-blind controlled clinical trial of oxcarbazepine versus phenytoin in adults with previously untreated epilepsy. Epilepsy Res 1997; 27: 195–204
3 Beydoun A, et al. Oxcarbazepine monotherapy for partial onset seizures. Neurology 2000; 54: 2245–2251
4 Zsótér A, et al. Long-term retention rates of the newer antiepileptic drugs in childhood onset epilepsies difficult to treat. Neuropaediatrics 2004; 35: 60 (abstract)
5 Albani F, et al. Immediate (overnight) switching from carbamazepine to oxcarbazepine monotherapy is equivalent to a progressive switch. Seizure 2004; 13: 254–263
6 Reinikainen KJ, et al. Comparison of oxcarbazepine and carbamazepine: a double-blind study. Epilepsy Res 1987; 1: 284–289
7 Dam M, et al. A double-blind study comparing oxcarbazepine and carbamazepine in patients with newly diagnosed previously untreated epilepsy. Epilepsy Res 1989; 3: 70–76
8 Guerreiro MM, et al. A double-blind controlled trial of oxcarbazepine versus phenytoin in children and adolescents with epilepsy. Epilepsy Res 1997; 27: 205–213
9 Schmidt D, et al. Recommendations on the clinical use of oxcarbazepine in the treatment of epilepsy: a consensus view. Acta Neurol Scand 2001; 104: 167–170
10 Arzneimittel-Kompendium der Schweiz 2006, www.kompendium.ch

Z: Oxcarbazepin, Filmtabletten mit Bruchkerbe zu 150 mg, 300 mg und 600 mg. Orale Suspension 60 mg/ml. **I:** Behandlung von partiellen Anfällen mit oder ohne sekundär generalisierten tonisch-klonischen Anfällen und generalisierten tonisch-klonischen Anfällen, bei Erwachsenen und bei Kindern im Alter von 1 Monat oder älter. **D:** Mono- oder Kombinationstherapie. Filmtabletten und orale Suspension sind bei gleicher Dosierung austauschbar. Auf 2 Einzeldosen verteilt einnehmen. Erwachsene: 600–2400 mg/d. Kinder ab 1 Monat: 8–10 mg/kg/d. Wenn klinisch indiziert, kann die Tagesdosis bei Kindern in Abständen einer Woche in Schritten von höchstens 10 mg/kg/d bis zu einer max. Tagesdosis von 60 mg/kg/d gesteigert werden. Detaillierte Informationen zur Dos.: s. Kompendium. **KI:** Überempfindlichkeit gegenüber Oxcarbazepin oder einen der Hilfsstoffe. **VM:** Überempfindlichkeitsreaktionen auf Carbamazepin. Über schwere Hautreaktionen einschliesslich Stevens-Johnson-Syndrom, toxische epidermale Nekrolyse (arzneimittelinduziertes Lyell's Syndrom) und Erythema multiforme wurde in sehr seltenen Fällen berichtet. Multi-Organ Hypersensitivitätsreaktionen traten in engem zeitlichem Zusammenhang mit dem Beginn der Behandlung mit Trileptal auf. Es liegen nur wenige Berichte vor und das Beschwerdebild dieser Störung war sehr variabel. Besonders bei älteren Patienten, bei vorbestehender renaler Erkrankung, vorbestehendem niedrigem Natriumspiegel und bei gleichzeitiger Behandlung mit Natriumspiegel senkenden Arzneimitteln oder nichtsteroidalen Antirheumatika, bei Hyponatriämie: Serumnatriumspiegel vor der Behandlung bestimmen, danach nach etwa zwei Wochen und dann während drei Monaten der Behandlung monatlich. Bei Herzinsuffizienz regelmässige Gewichtskontrolle, um das Auftreten einer Flüssigkeitsretention festzustellen. Vorsicht bei vorbestehender Störung der Reizleitung am Herzen. Leberfunktionsstörung. Abrupter Behandlungsabbruch. Hormonelle Kontrazeptiva. Alkohol. **IA:** Hemmt CYP2C19, induziert CYP3A4 und CYP3A5. Hormonale Kontrazeptiva. Andere Antiepileptika. Lithium. **UW:** Sehr häufig: Müdigkeit, Benommenheit, Schwächegefühl, Kopfschmerzen, Schläfrigkeit, Doppelsehen, Übelkeit, Erbrechen, Schwindel. Häufig: Asthenie, körperliche Unruhe, Affektabilität, Gedächtnisstörung, Apathie, Ataxie, Verwirrtheit, Depression, Nystagmus, Aufmerksamkeitsstörung, Tremor, Lethargie, Akne, Alopezie, Exanthem, verschwommenes Sehen, Sehstörungen, Verstopfung, Durchfall, Bauchschmerzen, verminderter Appetit, Hyponatriämie, erhöhte Blutharnsäure. Gelegentlich: Urticaria, Leukopenie, Zunahme der Transaminasen und/oder alkalischen Phosphatase. Sehr selten: Angioödem, Multi-Organ-Hypersensivität, schwere allergische Reaktionen einschliesslich Stevens-Johnson-Syndrom, systemischer Lupus erythematodes, Arrhythmie, Thrombozytopenie, Hepatitis, symptomatische Hyponatriämie. Seltene/sehr seltene unerwünschte Wirkungen: s. Kompendium. **P:** Filmtabletten zu 150 mg: 50*; zu 300 mg: 50* und zu 600 mg: 50*. Orale Suspension zu 60 mg/ml: 100 ml*, 250 ml*. Verkaufskategorie B.
*kassenzulässig

12734

NOVARTIS

Novartis Pharma Schweiz AG, Postfach, 3001 Bern, Tel. 031 377 51 11, www.novartispharma.ch

ralized seizures and unilaterally, ipsilateral to the hippocampal sclerosis, in patients with focal seizures. This study provides further evidence that the basal ganglia, and especially the substantia nigra, are involved in human epilepsy.

II.2. [^{18}F]-Fallypride

PET using the highly selective, high-affinity, dopamine D2/D3-receptor ligand [^{18}F]-Fallypride is suitable for measuring D2/D3 receptor availability in the extrastriatal regions of the brain. A group of seven patients with TLE and hippocampal sclerosis, was compared with a group of age-matched controls [26]. Compared with controls, [^{18}F]-Fallypride binding potential was significantly decreased in the epileptogenic temporal lobe in all patients. On the analysis of regions of interest, this reduction was evident in areas surrounding the seizure onset zone, at the temporal pole (-34%) and the anterior part of the lateral temporal lobe (-33%). Although the hippocampal [^{18}F]-FDG uptake (-8%) and hippocampal MR volume (-35%) were significantly reduced, no significant decrease of [^{18}F]-Fallypride binding potential was found in the hippocampal area. Thus, D2/D3-receptor binding is reduced at the pole and in lateral parts of the epileptogenic temporal lobe in patients with mesial TLE and HS. This area of decreased binding might correspond to "the irritative zone", suggesting that D2/D3 receptors might play a specific role in the pathophysiology of mesial TLE.

III. Glutamate / NMDA system

Glutamate is the principal excitatory neurotransmitter in the human brain. Its receptors are divided into ionotropic and metabotropic receptors. N-methyl-D-aspartate (NMDA) receptors form a subclass of ionotropic glutamate receptors. Enhanced excitatory transmission plays a central role in the generation of seizures and the development of epilepsy. The NMDA receptors have been studied in human epileptogenic brain with conflicting results. Increased as well as decreased receptor binding has been reported in epileptogenic tissue.

III.1. [^{11}C]-CNS 5161

CNS 5161 is an NMDA antagonist that binds to NMDA ion channel sites with high affinity. [^{11}C]-CNS 5161 is currently developed as a potential PET tracer. Four healthy control subjects and a single pilot case with mesial TLE were scanned with this tracer (Hammers, "The new and very new PET tracers in epilepsy", Satellite symposium to the 26th IEC, Orsay, Paris). While hippocampal volume on the affected side was reduced by 27% compared to the contralateral side, [^{11}C]-CNS 5161 volume of distribution was reduced by only 13%. This may indicate an actual increase in open NMDA channels per volume unit of tissue on the epileptogenic side. Larger studies, with partial volume correction, are needed.

Another study aimed to correlate hippocampal [^{11}C]-CNS 5161 volume of distribution and memory performances in eight healthy volunteers, with the hypothesis that the number of "active" NMDA receptors would be positively correlated with memory performances [27]. The predicted association between hippocampal [^{11}C]-CNS 5161 volume of distribution in the "resting" state and (verbal) memory performance was found, so NMDA activity might be a general marker for the ability to learn new material. Thus initial evaluations have yielded promising results, with a potential usefulness for both group studies and longitudinal studies. However, the two performed pilot scans in patients with epilepsy have highlighted the difficulties in modeling, due to the binding in vivo being neither clearly reversible nor irreversible, and due to the current restricted knowledge of in vivo binding behaviour.

III.2. [^{11}C]-ketamine

Ketamine is an anaesthetic which binds specifically and reversibly to the PCP-recognition site of the NMDA receptor in a non-competitive manner. Receptor affinity (Kd) is in the μmol range. PET studies, especially in monkeys, but also in humans, have shown that the distribution of [^{11}C]-S-ketamine corresponds to regions with high density of glutamate receptors.

Eight patients with mesial TLE were evaluated by PET using [^{11}C]-ketamine [28]. The uptake of [^{11}C]-ketamine in the temporal lobe of ictal onset was compared with the contralateral side and correlated to changes in regional glucose metabolism measured by PET with FDG. A side-to-side comparison revealed a 9-34% reduction of tracer radioactivity in the temporal lobes of ictal onset. The magnitude and distribution of the reduction were similar to the metabolic pattern seen on PET scans with FDG. This reduction may reflect reduced NMDA receptor density, reduced perfusion, focal atrophy, or other factors. Further studies with correction for partial volume effects and perfusion differences are needed.

IV. Nicotinic cholinergic system

About ten years ago, mutations were identified in one form of familial non lesional focal epilepsy, the autosomal dominant nocturnal frontal lobe epilepsy (ADNFLE), in genes coding for two different subunits of the neuronal nicotinic acetylcholine receptor (nAChR), respectively the α4 and the β2 subunits. To date, such mutations have been found in nearly fifteen families [29]. These subunits are known to assemble and form the main brain nicotinic receptor subtype in humans. The nAChRs are excitatory receptor channels permeable with cations (Na^+, K^+, Ca^{2+}), widely distributed throughout the brain. Most of these

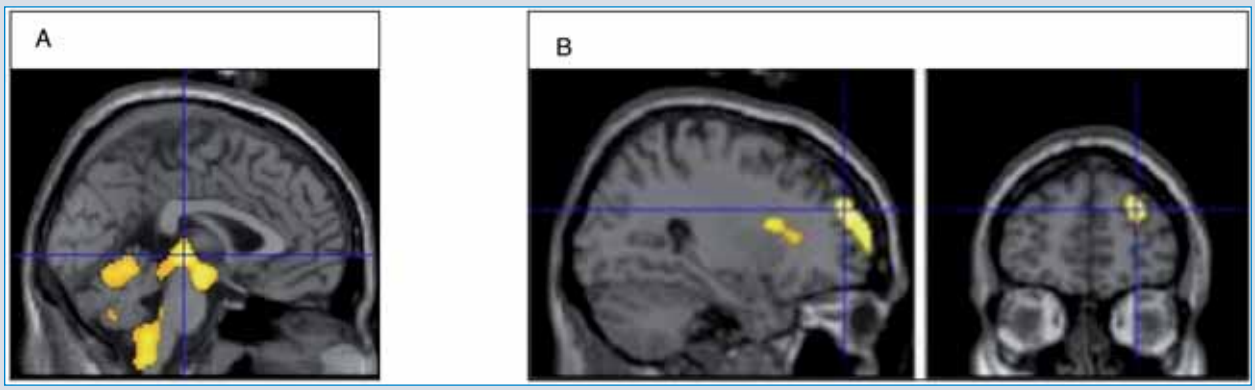

Figure 1. A) SPM analysis of [18F]-F-A-85380 PET hyperfixation in ADNFLE patients, corresponding to regions of increased density of nicotinic receptors (patients n = 8; controls n = 7; P uncorrected < 0.001, P corrected at cluster level < 0.05). These images focus on the mesencephalic cluster, with the blue cross centered on the voxel with the highest Z score (Z = 4.63; MNI coordinates: -2 -22 0). This voxel is located in the epithalamus. The cluster extends in the ventral mesencephalon. B) SPM analysis of [18F]-F-A-85380 PET hypofixation in ADNFLE patients, corresponding to the regions of decreased density of nicotinic receptors (patients n = 8; controls n = 7; P uncorrected < 0.001, P corrected at cluster level < 0.05). The right side is on the right on the coronal MRI image. The hypofixation is located in the right dorsolateral prefrontal region.

receptors are presynaptic and have a neuromodulatory role consisting of an enhancement of the release of GABA, glutamate, dopamine, norepinephrine, serotonin or ACh.

PET study of nAChRs offers a unique opportunity to investigate some in vivo consequences of the molecular defect in ADNFLE patients. Formerly, the ligand used for the nAChRs was nicotine labeled with ^{11}C. But its cerebral fixation was flow-dependent and partially nonspecific [30]. Later, the 2-Fluoro-A-85380 (3-[2(S)-2-azetidinylmethoxy]pyridine) labeled by a positron emitter isotope, the fluorine-18, was synthesized at Orsay CEA [31]. The F-A-85380 has remained a ligand with a high affinity and specificity for the central $\alpha4\beta2$ nAChRs. The brain tracer concentration reflects the receptor concentration [32].

A PET using [^{18}F]-F-A-85380 was performed in a group of 8 patients with ADNFLE carrying a mutation in a nAChR subunit, in comparison with a group of 7 age-matched healthy volunteers [33]. Patients and volunteers were all non-smokers. Parametric images of volumes of distribution were generated using the ratio between brain tissue concentration and the unchanged plasma concentration. The images showed a clear difference in the pattern of the nAChR density in the brains of the patients compared to the healthy volunteers. The volumes of distribution calculated on several brain regions delineated on individual MRI of patients with ADNFLE and of control subjects revealed a significant increase (between 12 and 21%, $p < 0.05$) in the patients in the mesencephalon, the pons and the cerebellum. Statistical parametric mapping (SPM) confirmed clear regional differences between patients and controls: patients had increased nAChR density in the epithalamus, ventral mesencephalon and cerebellum, but decreased nAChR density in the right dorsolateral prefrontal region. In 5 patients who underwent an additional [^{18}F]-FDG PET experiment, hypometabolism was observed in the neighbouring area of the right orbitofrontal cortex. The demonstration of a regional nAChR density decrease restricted in the prefrontal cortex, despite the known distribution of these receptors throughout the cerebral cortex, is consistent with focal epilepsy involving the frontal lobe. In addition, based on the known biochemical and cellular circuits in the brainstem, these results suggest that the nAChR density increase in the mesencephalon is involved in the pathophysiology of ADNFLE through the role of brainstem ascending cholinergic systems in arousal. An important step now, is to extend this PET examination to other forms of epilepsy, to confirm the specificity of the above-mentioned results for ADNFLE.

V. Adenosine system (A1 adenosine receptor)

Adenosine is different from regular transmitters: it is not released in a vesicular way, not released in synapses. Instead, it is produced in the cell like the “sweat” of the cell. Whenever the cell has to work, adenosine production increases intra and extra-cellularly, activating the modulatory adenosine receptors. There are four different types of receptors, which have different affinities for adenosine. The receptors with the highest affinity are the A1 and A2A subtypes. The decision to choose the A1 adenosine receptors for tracer developments was mainly made because the A1 receptor is widely distributed throughout the brain.

In cases of high energy demand, such as in the early phases of an epileptic seizure, there is a massive increase of adenosine that is transported from the inside to the outside of the cell and thus can activate A1 receptors. It has been shown in animal models in the last two decades that the activation of A1 receptors increases activation of inhibitory G proteins and then helps stopping seizure activity. Adenosine is considered to be responsible for seizure arrest and for post-ictal refractoriness and thus

appears to be an endogenous antiepileptic regulator. The deficiencies within this system might result in a higher susceptibility for seizures or epileptogenesis. Most studies report reductions of A1 receptor density in experimental epilepsy models and in human post-mortem brain material of patients with epilepsy.

The radiotracer available for the A1 adenosine receptor is CPFPX, which stems from the same group as caffeine (caffeine being a non-selective blocker of adenosine receptors). CPFPX is fluorinated ([^{18}F]-CPFPX). It has relatively high affinity of 1.3 nM with rather high selectivity: A1/A2A >700. In the human brain, there is a high uptake within the striatum, the caudate nucleus, the putamen, part of the medial anterior thalamus and neocortical regions.

A study performed in a F98 rat model for brain tumors showed that there was an increased density of adenosine A1 receptors surrounding the tumor as well as surrounding the necrosis which is visible in the tumor [34]. The upregulation of A1 receptors is primarily on astrocytes.

A PET study using [^{18}F]-CPFPX in a patient with a glioma also revealed increases in A1 adenosine receptor density in the immediate vicinity of the tumor (invasion zone of the tumor), similar to the findings in the rat. However, in contrast to the rat findings, there was a decrease of A1 receptor binding surrounding this zone of increased receptors. This zone of "reduction of inhibitory capacity" could contribute to tumor-associated epilepsy. So the density of A1 receptors is within the normal range in the tumour, increased in the immediate peri-tumoral zone and decreased in the extra-tumoral area, which may result in an increased excitability of the brain.

Two patients with TLE have been studied (Bauer, "The new and very new PET tracers in epilepsy", Satellite symposium to the 26th IEC, Orsay, Paris). In the first case, including unilateral hippocampal sclerosis, there was a reduction of the hippocampal [^{18}F]-CPFPX signal on the sclerotic side. In a second case of TLE plus with dystrophic changes seen in the neocortex, lateralized decreased signal was observed compared to the contralateral side and compared to control levels. These data are not partial volume corrected.

It has to be noted that in autoradiographic studies of surgically resected hippocampi, densities were far lower than in control samples.

VI. Opioid system

The opioid receptors can be classified into at least three types: μ-, δ- and κ-receptors. Opioid peptide release is calcium-dependent and requires high frequency neuronal firing; thus opioid peptides act as mediators of use-dependent synaptic activity and as co-transmitters to modulate the actions of the primary transmitter [35]. Opioid receptor availability reflects endogenous opioid concentrations. Animal and limited human data suggest an important anticonvulsant role for opioid peptides and their receptors. Exogenously applied opioids have predominantly inhibitory actions on neuronal activity and transmitter release throughout the CNS. There is a large body of animal data showing that endogenous opioid release may occur following induced and spontaneous seizures and that increased opioid neurotransmission has an anticonvulsant role. However, the human relevance of these studies can only, at best, be inferential.

The tracer diprenorphine (DPN) is a non-selective partial agonist, which has similar affinity for μ-, δ- and κ-receptors. It is displaced by endogenous opioids [36]. It shows high binding to basal ganglia, amygdala, and layers V and VI of the cerebral cortex.

A recent study aimed to provide direct human in vivo evidence for changes in opioid receptor availability following spontaneous seizures [37]. Nine patients with refractory TLE were scanned by PET using [^{11}C]-DPN within hours of spontaneous temporal lobe seizures (median interval: 8.5 h postictally, range: 1.5 - 21.3 h). A second scan was acquired days to weeks later, after as long a seizure-free period was achievable in a given patient, and served as an intrasubject control (corresponding to interictal binding). A regionally specific increase of opioid receptor availability was evident following seizures in the temporal pole and fusiform gyrus ipsilateral to the seizure focus. Thus this study confirmed changes in opioid receptor availability in the hours following seizures, suggesting an important role of the opioid system in seizure control. On the contrary, previous studies performed during reading-induced seizures and absences demonstrated decreased [^{11}C]-DPN binding [38, 39]. Taking together the results of these previous studies and the recent study, the authors suggest that "synaptic opioid levels increase at the time of seizures, leading to a reduction in [^{11}C]-DPN binding, and that this is followed by a gradual recovery of available surface receptors with an overshoot over basal levels which is detected by PET about 8 h after seizures, with a gradual return to normal levels during the interictal phase".

References

1. *Mauguiere F, Ryvlin P. The role of PET in presurgical assessment of partial epilepsies. Epileptic Disord 2004; 6: 193-215*
2. *Neuman RS, Thompson PM. Serotonin mediates suppression of focal epileptiform activity induced by noxious stimulation. Epilepsia 1989; 30: 307-313*
3. *Watanabe K, Minabe Y, Ashby CR Jr, Katsumori H. Effect of acute administration of various 5-HT receptor agonists on focal hippocampal seizures in freely moving rats. Eur J Pharmacol 1998; 350: 181-188*
4. *Wada Y, Shiraishi J, Nakamura M, Koshino Y. Role of serotonin receptor subtypes in the development of amygdaloid kindling in rats, Brain Res 1997; 747: 338-342*
5. *Clinckers R, Smolders I, Meurs A et al. Anticonvulsant action of hippocampal dopamine and serotonin is independently mediated by D and 5-HT receptors. J Neurochem 2004; 89: 834-843*
6. *Trottier S, Evrard B, Vignal JP et al. The serotonergic innervation of the cerebral*

cortex in man and its changes in focal cortical dysplasia. Epilepsy Res 1996; 25: 79-106
7. Chugani DC, Chugani HT, Muzik O et al. Imaging epileptogenic tubers in children with tuberous sclerosis complex using alpha-[11C]methyl-L-tryptophan positron emission tomography. Ann Neurol 1998; 44: 858-866
8. Asano E, Chugani DC, Muzik O et al. Multimodality imaging for improved detection of epileptogenic foci in tuberous sclerosis complex. Neurology 2000; 54: 1976-1984
9. Fedi M, Reutens DC, Andermann F et al. Alpha-[11C]-Methyl-L-tryptophan PET identifies the epileptogenic tuber and correlates with interictal spike frequency. Epilepsy Res 2003; 52: 203-213
10. Kagawa K, Chugani DC, Asano E et al. Epilepsy surgery outcome in children with tuberous sclerosis complex evaluated with alpha-[11C]methyl-L-tryptophan positron emission tomography (PET). J Child Neurol 2005; 20: 429-438
11. Juhasz C, Chugani DC, Muzik O et al. Alpha-methyl-L-tryptophan PET detects epileptogenic cortex in children with intractable epilepsy. Neurology 2003; 60: 960-968
12. Juhász C, Chugani DC, Muzik O et al. In vivo uptake and metabolism of alpha-[11C]methyl-L-tryptophan in human brain tumors. J Cereb Blood Flow Metab 2006; 26: 345-357
13. Fedi M, Reutens D, Okazawa H et al. Localizing value of alpha-methyl-L-tryptophan PET in intractable epilepsy of neocortical origin. Neurology 2001; 57: 1629-1636
14. Natsume J, Kumakura Y, Bernasconi N et al. Alpha-[11C] methyl-L-tryptophan and glucose metabolism in patients with temporal lobe epilepsy. Neurology 2003; 60: 756-761
15. Juhász C, Chugani DC, Padhye UN et al. Evaluation with alpha-[11C]methyl-L-tryptophan positron emission tomography for reoperation after failed epilepsy surgery. Epilepsia 2004; 45: 124-130
16. Savic I, Lindstrom P, Gulyas B et al. Limbic reductions of 5-HT1A receptor binding in human temporal lobe epilepsy. Neurology 2004; 62: 1343-1351
17. Toczek MT, Carson RE, Lang L et al. PET imaging of 5-HT1A receptor binding in patients with temporal lobe epilepsy. Neurology 2003; 60: 749-756
18. Giovacchini G, Toczek MT, Bonwetsch R et al. 5-HT1A receptors are reduced in temporal lobe epilepsy after partial-volume correction. J Nucl Med 2005; 46: 1128-1135
19. Merlet I, Ryvlin P, Costes N et al. Statistical parametric mapping of 5-HT1A receptor binding in temporal lobe epilepsy with hippocampal ictal onset on intracranial EEG. Neuroimage 2004; 22: 886-896
20. Merlet I, Ostrowsky K, Costes N et al. 5-HT1A receptor binding and intracerebral activity in temporal lobe epilepsy: an [18F]MPPF-PET study. Brain 2004; 127: 900-913
21. Elsinga PH, Hendrikse NH, Bart J et al. Positron emission tomography studies on binding of central nervous system drugs and p-glycoprotein function in the rodent brain. Mol Imaging Biol 2005; 7: 37-44
22. Aznavour N, Zimmer L. [18F]MPPF as a tool for the in vivo imaging of 5-HT1A receptors in animal and human brain. Neuropharmacology 2007; 52: 695-707
23. Depaulis A, Vergnes M, Marescaux C. Endogenous control of epilepsy: the nigral inhibitory system. Prog Neurobiol 1994; 42: 33-52
24. Biraben A, Semah F, Ribeiro MJ et al. PET evidence for a role of the basal ganglia in patients with ring chromosome 20 epilepsy. Neurology 2004; 63: 73-77
25. Bouilleret V, Semah F, Biraben A et al. Involvement of the basal ganglia in refractory epilepsy: an 18F-fluoro-L-DOPA PET study using 2 methods of analysis. J Nucl Med 2005; 46: 540-547
26. Werhahn KJ, Landvogt C, Klimpe S et al. Decreased dopamine D2/D3-receptor binding in temporal lobe epilepsy: an [18F]fallypride PET study. Epilepsia 2006; 47: 1392-1396
27. Hammers A, Asselin MC, Brooks DJ et al. Correlation of memory function with binding of [C-11]CNS 5161, a novel putative NMDA ion channel PET ligand [abstract]. Neuroimage 2004; 22(Suppl 2): T54
28. Kumlien E, Hartvig P, Valind S et al. NMDA-receptor activity visualized with (S)-[N-methyl-11C]ketamine and positron emission tomography in patients with medial temporal lobe epilepsy. Epilepsia 1999; 40: 30-37
29. Picard F, Scheffer I. Recently defined genetic epilepsy syndromes. In: Roger J et al. (eds): Epileptic Syndromes in Infancy, Childhood and Adolescence, 4th edition. Montrouge: John Libbey Eurotext 2005: 519-535
30. Nyback H, Halldin C, Ahlin A et al. PET studies of the uptake of (S)- and (R)-11C-nicotine in the human brain: Difficulties in vizualizing specific receptor binding in vivo. Psychopharmacol 1994; 115: 31-36
31. Dollé F, Dolci L, Valette H et al. Synthesis and nicotinic acetylcholine receptor in vivo binding properties of 2-fluoro-3-[2(S)-2-azetidinylmethoxy]pyridine: a new positron emission tomography ligand for nicotinic receptors. J Med Chem 1999; 42: 2251-2259
32. Gallezot JD, Bottlaender M, Gregoire MC et al. In vivo imaging of human cerebral nicotinic acetylcholine receptors with 2-18F-fluoro-A-85380 and PET. J Nucl Med 2005; 46: 240-247
33. Picard F, Bruel D, Servent D et al. Alteration of the in vivo nicotinic receptor density in ADNFLE patients, a PET study. Brain 2006; 129: 2047-2060
34. Bauer A, Langen KJ, Bidmon H et al. 18F-CPFPX PET identifies changes in cerebral A1 adenosine receptor density caused by glioma invasion. J Nucl Med 2005; 46: 450-454
35. Simmons ML, Chavkin C. Endogenous opioid regulation of hippocampal function. Int Rev Neurobiology 1996; 39: 145-198
36. Neumaier JF, Chavkin C. Release of endogenous opioid peptides displaces [3H]diprenorphine binding in rat hippocampal slices. Brain Res 1989; 493: 292-302
37. Hammers A, Asselin MC, Hinz R et al. Upregulation of opioid receptor binding following spontaneous epileptic seizures. Brain 2007 (in press)
38. Bartenstein PA, Duncan JS, Prevett MC et al. Investigation of the opioid system in absence seizures with positron emission tomography. J Neurol Neurosurg Psychiatry 1993; 56: 1295-1302
39. Koepp MJ, Richardson MP, Brooks DJ, Duncan JS. Focal cortical release of endogenous opioids during reading induced seizures. Lancet 1998; 352: 952-955

Address for correspondence:
PD Dr. Fabienne Picard
Department of Neurology HUG
24 rue Micheli-du-Crest
CH 1211 Genève
Tel. 0041 22 372 33 11 bip. 6 853 410
Fax 0041 22 372 82 99
Fabienne.Picard1@hcuge.ch

Utilization of Preoperative Imaging for Epilepsy Surgery

Shahan Momjian[1], Serge Vulliémoz[2], Laurent Spinelli[2], and Claudio Pollo[3]
[1]Department of Neurosurgery, [2]Department of Neurology, HUG, Geneva, [3]Department of Neurosurgery, CHUV, Lausanne

Summary

Recent advances in imaging techniques (MRI), electrical source imaging and image processing algorithms (co-registration) have increased the success rate of preoperative localization of epileptogenic zones. This information can be transferred into image-guidance systems (neuronavigation) and utilized intraoperatively during epilepsy surgical procedures. More precise implantation of subdural or depth electrodes can be achieved for invasive monitoring. Improved tailored resections or disconnections can be performed. Intraoperative MR or digital photography can also be used to control the precise extent of tailored procedures. Used alone or in combination, these technological tools should improve the confidence and safety of epilepsy surgery, particularly in cases of non-lesional epilepsy. However, the permanent dialogue between the epileptologist and the neurosurgeon, possibly during the surgery itself, as well as a better comprehension of epileptogenic diseases, remain a key factor in the success of epilepsy surgery

Epileptologie 2007; 24: 73 – 77

Key words: Epilepsy surgery, image-guided surgery, brain mapping

Utilisation de l'imagerie préopératoire pour la chirurgie de l'épilepsie

Les progrès récents réalisés en technique d'imagerie (IRM), l'imagerie de localisation de sources et les algorithmes d'analyse d'image (co-registration) ont augmenté le taux de succès de la localisation préopératoire des zones épileptogènes. Ces informations peuvent être transférées dans des systèmes de guidage par l'image (neuronavigation) et utilisées en salle d'opération durant les procédures de chirurgie de l'épilepsie. Il en résulte l'implantation plus précise d'électrodes sous-durales ou profondes pour le monitoring invasif et des résections ou déconnexions plus ciblées. L'IRM ou la photographie digitale peropératoires peuvent être utilisées pour contrôler l'extension d'une résection ciblée. Utilisés seuls ou de manière combinée, ces outils technologiques devraient améliorer la qualité et la sûreté de la chirurgie de l'épilepsie, particulièrement dans les cas de chirurgie non lésionnelle. Toutefois, le dialogue permanent entre l'épileptologue et le chirurgien, aussi durant la chirurgie, de même qu'une meilleure compréhension des maladies épileptogènes restent un facteur clé contribuant au succès de la chirurgie de l'épilepsie.

Mots clés : Chirurgie de L'épilepsie, neuronavigation, cartographie cérébrale

Präoperative Bildgebung bei Epilepsiechirurgie

Kürzliche Fortschritte in der MRI-Bildgebungstechnik, des „electrical source imaging“ und bei Algorithmen der Bildverarbeitung (Ko-Registrierung) haben die Erfolgsrate bei der präoperativen Lokalisation von epileptogenen Zonen erhöht. Diese Information kann in Bildgebungs-gesteuerte Verfahren (Neuronavigation) übertragen und intraoperativ während epilepsiechirurgischer Eingriffe verwendet werden. Damit erreicht man eine genauere Implantation von subduralen oder Tiefenelektroden für das invasive Monitoring und eine verbesserte Kontrolle von massgeschneiderten Resektionen oder Durchtrennungen. Auch die digitale Bildgebung oder ein Intraoperatives MRI dient der Kontrolle des genauen Ausmasses massgeschneiderter Eingriffe. Diese technologischen Verfahren, allein oder in Kombination angewandt, sollten das Vertrauen in die und die Sicherheit der Epilepsiechirurgie verbessern, insbesondere bei nicht-läsionellen Zellen. Der permanente Dialog zwischen Epileptologen und Neurochirurgen, der auch während des Eingriffs selbst möglich ist, bleibt ebenso wie ein besseres Verständnis der epileptologenen Erkrankungen ein Schlüsselfaktor für den Erfolg epilepsiechirurgischer Eingriffe.

Schlüsselwörter: Epilepsiechirurgie, Neuronavigation, Kartographie des Gehirns

Introduction

Success of epilepsy surgery relies on a precise determination and localization of the epileptogenic zone (EZ). While mesial temporal lobe epilepsies are treated successfully when hippocampal sclerosis is present, non-lesional and/or extra-temporal epilepsies are still challenging and still need invasive tools like subdural grids or depth electrodes to achieve accurate localization of EZ in some cases. With the recent advances in anatomical (MRI) and functional imaging (SPECT, PET, fMRI)

coupled with electroencephalography and powerful signal processing tools (electrical source imaging), an increasing number of lesions and/or brain regions with epileptogenic activity are becoming localizable with more accuracy. The information obtained during the pre-operative evaluation should be fully and reliably transferred and utilized in the operative theatre in order to increase the precision of surgical resective or disconnective procedures while minimizing the risks of neurological deficits. Image-guided surgery has had a rapid development in the previous years and proved to be a useful adjunct in the neurosurgical practice, especially for the surgery on small and deep-seated lesions in eloquent regions. We present here our experience in the development and utilization of the preoperative multimodal imaging as well as the recent technical advances in image-guidance that allow the precise and tailored resection or disconnection of a predetermined epileptic focus.

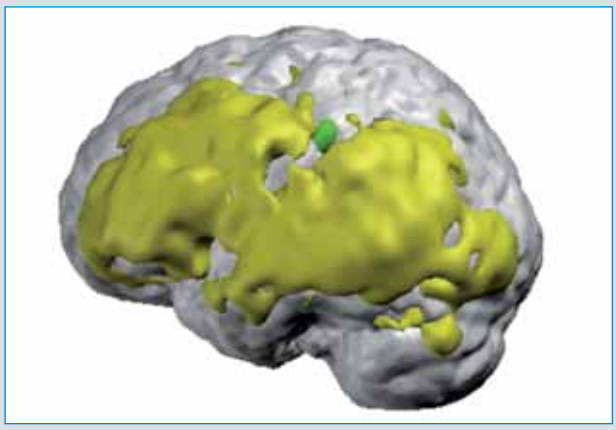

Figure 1: Co-registration of PET, subtraction ictal SPECT (SISCOM) and MRI: 50 year-old patient with partial motor seizures. The MRI revealed a discrete left parietal abnomality suggestive of dysplasia. PET (yellow) and SISCOM (green) co-registered with the MRI showed a focal interictal hypometabolism and ictal hyperperfusion that was concordant with the MRI abnormality.

Multimodal imaging and image co-registration

Multimodal imaging is essential during the presurgical evaluation of epileptic patients as it provides not only information on the localization and precise extent of epileptogenic malformations or lesions, but also information on normal and epileptogenic brain function, especially in non-lesional cases. Besides the standard use of CT, SPECT and PET images, recent advances in magnetic resonance imaging (high-field MRI) has certainly contributed to improve the resolution of anatomic (T1-, T2-weighted, FLAIR sequences) images, leading to a dramatic decrease of the so-called cryptogenic (or non-lesional) cases of focal epilepsy (figures). The use of high-field MRI has lead to the localization of brain functional regions with higher accuracy (fMRI) as well as the development of new applications, like the assessment of memory or the localization of abnormal epileptogenic brain function when coupled with EEG (EEG triggered fMRI). The exploration of diffusion properties of intracellular water by diffusion tensor imaging (DTI) has provided access to exquisite information on normal and possibly aberrant fiber tract localization and direction (see the paper by Vulliémoz et al. in this issue).

Parallel development of signal processing tools has lead to the emergence of electrical source imaging, which allows to consider the spatial and temporal localization of epileptic foci from the distribution of scalp EEG recordings through inverse solutions algorithms.

Powerful and reliable co-registration algorithms are needed to integrate complementary preoperative or intraoperative (when images are treated by image-guided systems) information provided by multimodal imaging [1]. Co-registration is essential for accurate spatial assessment of EZ and eloquent brain areas either by non-invasive multimodal imaging **(Figure 1)** or by subdural or depth electrodes when invasive monitoring is required **(Figures 2 and 3)**. The respective position of such electrodes is obtained from post-implantation CT or MR images; such "virtual electrodes" are co-registered with the pre-implantation MR images. Spatial mapping of EZ and eloquent brain areas can be carefully carried out from these implanted electrodes **(Figure 4)**. The combined 3D volume can also be transferred and rendered on image-guided systems for tailoring resection/disconnection of EZ [2, 3].

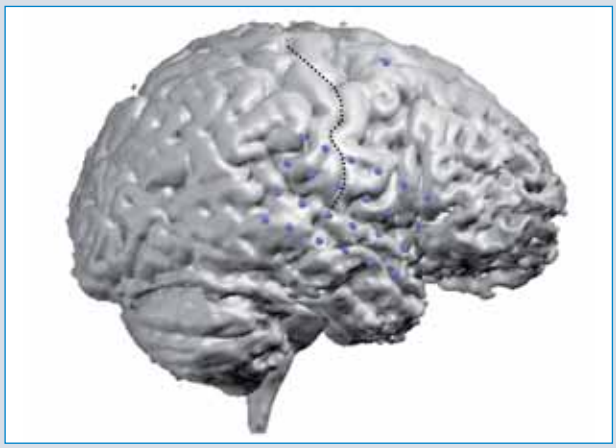

Figure 2: Co-registration of a CT-scan after implantation of a subdural grid (blue dots) and the preoperative 3D MRI.

Image-guided surgery (neuronavigation)

The term "neuronavigation" refers to the frameless image-guidance methods that allow the real time localization, during surgery, of the position of the instruments in relation to the preoperative imaging. Such techniques are widely used for the surgery on small or deep-seated lesions in order to follow a most direct and

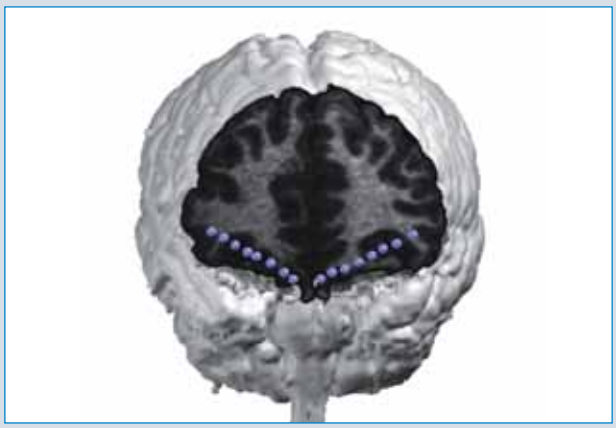

Figure 3: Co-registration of a CT-scan after implantation of a depth electrode (blue dots) in the orbitofrontal regions and the preoperative 3D MRI.

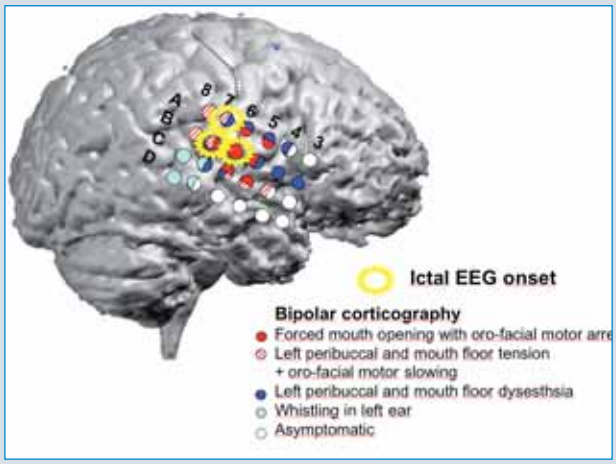

Figure 4: **Co-registration of electrodes, EEG, corticography and MRI: The precise location of the intracranial electrodes is assessed by CT scan, co-registered to MRI. The dots indicate the position of the electrode contacts. The EEG telemetry allows recording of the ictal onset zone (yellow). Bipolar stimulation of the intracranial contacts allows mapping of the eloquent cortex (color-coded for motor and sensory) for optimal surgical planning.**

less harmful trajectory to reach the desired target. Regarding epilepsy surgery, integration of multimodal imaging is crucial for guidance of subdural grids and/or depth electrodes placement to achieve precise localization of EZ and for mapping the eloquent brain areas during invasive recordings. The accuracy of depth electrodes placement with neuronavigation appears sufficient and the absence of a stereotactic frame allows the placement of subdural electrodes at the same operation [4, 5]. Multi-modality image-guided systems are also useful regarding surgical planning of therapeutic procedures, including the choice of center/extent of craniotomies and guidance of superficial as well as deep tailored resections/disconnections, rendering procedures minimally invasive. This is particularly true in cases of non lesional epilepsy, multiple lesions/EZ or if an EZ is located in an eloquent brain area, in order to optimize the extent of EZ resection [3, 6, 7] while minimizing the risks of neurological damage and the need for re-resection at least in temporal lobe epilepsy surgery [8].

During selective amygdalo-hippocampectomy, neuronavigation is very useful to precisely define the place and extent of craniotomy, find the opening site of limen insulae and guide the white matter trajectory to enter the anterior portion of the temporal horn of the ventricle **(Figure 5)**, limiting the risk of postoperative visual field deficit and limiting the extent of the necessary opening of the sylvian fissure or the transcortical approach [9]. Taking some precautions on account of brain collapse, neuronavigation can also serve to measure the length of the hippocampal resection, in order to tailor or standardize the hippocampectomy [10]. Moreover, when temporal lobectomy is associated with amygdalo-hippocampectomy, neuronavigation helps to tailor the posterior extent of the temporal resection. When periinsular hemispherotomy is considered, neuronavigation is very useful to find the lateral ventricle, reduce the risk of entering the contralateral hemisphere during the callosotomy and guide the approach for disconnecting the fimbria/fornix from the posterior aspect of the corpus callosum.

Figure 5: Image-guidance system showing the localization of the temporal horn of the ventricle (left) and the corresponding intraoperative view of the opened ventricle (right).

Although a precise per-operative localization of the target is achievable at the beginning of surgery, neuronavigation is subject to errors due to the shift and distortion of the brain as surgery progresses through the combined effect of cerebral resection and gravity. A study by Wurm et al. concluded that the surgical navigation was useful for tailoring the craniotomy and the cortectomy but was less reliable for the verification of the resection boundaries in the white matter. It was also useful to report the electric focus on the anatomic structures [11]. The utilization of per-operative neuronavigation may also have the potential of reducing the complication rate. However, the safer maximization of the resection allowed by neuronavigation does not replace completely the utility of electrocorticography. Thus, the combination of neuronavigation and electrocorticography appears to be an efficient solution of obtaining a precise lesionectomy as well as insuring a sufficient resection of the epilectogenic tissue in order to achieve a better seizure outcome [12].

Per-operative MRI

Per-operative MRI is another recent advance in image-guided surgery. It allows the repeated verification of the position of a lesion, the exclusion of the persistence of a residue of the lesion and, overall, the direct visualization of the brain in its current status and position. The image is present and brain shift is therefore not a concern. For epilepsy surgery, per-operative MRI can be an interesting adjunct to evaluate and maximize the extent of resection of the epileptic focus **(Figure 6)**. As the extent of resection of the temporo-mesial structures correlates with outcome, per-operative MRI has been used during anterior temporal lobectomies and selective amygdalo-hippocampectomies to verify the extent of resection, revealing that an unresected residue of amygdala or hippocampus was often left by the surgeon [13]. The per-operative identification and resection of such potentially epileptogenic residual tissue is obviously of great interest to optimize seizure control after a single surgery.

In fact, in epilepsy, the lesion is often not visible on T1-weighted and hardly visible of T2-weighted and FLAIR images, limiting the interest of the current low-field per-operative MRI systems. However, the co-registration of the pre-operative high-field T2 and FLAIR images with the T1 images and the utilization of the fused images during surgery along with a neuro-navigation system is an effective solution to accurately target the epileptic focus in diagnostic and resective epilepsy surgery [15].

Digital photography

A simple digital picture of the exposed cortex during epilepsy surgery can be of great help in planning a resective or disconnective surgery [16]. If per-operative mapping (somato-sensory evoked potentials and/or direct cortical stimulation) and electro-corticography are performed during the surgery, the epileptologist can report the identified eloquent areas as well as the

Figure 6: Intraoperative MRI coupled with image-guidance system (left) and acquired image showing the extent of a lesion resection (right)

However, an extensive resection implies an increased risk of new neurological deficits. The combination of functional neuronavigation with per-operative MRI appears therefore as an elegant solution to obtain an up-to-date combined anatomical and functional information for guidance; the position of the eloquent cerebral regions are displayed in superimposition in the operative field, thereby minimizing the risk of encroaching on the functional brain regions [14]. This combined approach has been used in epilepsy surgery with low-field and high-field MRI systems but the latter proved clearly superior in epilepsy surgery by its better image quality and more advanced imaging possibilities [14].

primary and secondary epileptogenic zones on the picture and thus in relation with the cortical surface landmarks **(Figure 7)**. A global neurosurgical map is thus created, allowing the epileptologist to plan a tailored combination of cortical resections and subpial transsections, and aiding and orienting the neurosurgeon who, at any time as the surgery progresses, can refer to this original and undistorted map [16]. Such pictures can also be taken at the time of subdural strips and grids implantation for invasive presurgical work-up, where a more complex map, including language and cognitive functions, will be created during the pre-operative investigations **(see Figures 2 and 4)**. The digital picture is then sufficient to precisely localize the subdu-

Lebensfreude schenken

Der Legatratgeber der Epilepsie-Liga «Geschenktes Leben» enthält nützliche Informationen über die korrekte Abfassung eines Testaments, über die Tätigkeit der Epilepsie-Liga und über die Situation von Betroffenen in der Gesellschaft. Sie ist sehr ansprechend gestaltet und eignet sich zur Auflage oder zum Weitergeben an Personen, die sich damit befassen, ihre persönlichen Errungenschaften zu ordnen und in sinnvoller Weise weiterzugeben. Als nicht subventionierte Organisation ist die Epilepsie-Liga auf die Unterstützung von Gönnern angewiesen. Wir sind Ihnen sehr dankbar, wenn Sie als Mitglied die Broschüre «Geschenktes Leben» weiterreichen an Menschen, welche sich mit der Thematik befassen möchten und von den nützlichen Tipps profitieren könnten.

Neu ist die Legatbroschüre auch auf Französisch und Italienisch erhältlich.



Eisai

zonegran®

zonisamid

Lebensqualität durch Wirksamkeit*

ZONEGRAN® (Zonisamid). **I:** Zonegran ist indiziert als Zusatztherapie für die Behandlung erwachsener Patienten mit partiellen epileptischen Anfällen mit oder ohne sekundärer Generalisierung. **D:** Dosierungen von 300–500 mg/Tag haben sich als wirksam erwiesen, aber einige Patienten können bereits auf geringere Dosierungen ansprechen. Zonegran kann nach der Titrationsphase ein- oder zweimal täglich angewendet werden. Die empfohlene anfängliche Tagesdosis in der Titrationsphase beträgt 50 mg, aufgeteilt in zwei Einzeldosen. Nach einer Woche kann die Dosis auf 100 mg täglich erhöht werden, danach kann die Dosis in wöchentlichen Abständen in Schritten von bis zu 100 mg erhöht werden. **KI:** Überempfindlichkeit gegenüber Zonisamid, gegenüber einem der sonstigen Bestandteile oder gegenüber Sulfonamiden. Mittelschwere bis schwere Nieren- und/oder Leberinsuffizienz. Schwangerschaft: Kategorie C. **VM:** Die Behandlung von Patienten mit eingeschränkter Nierenfunktion sollte mit Vorsicht erfolgen. In Übereinstimmung mit der gegenwärtigen klinischen Praxis muss ein Absetzen von Zonegran bei Patienten mit Epilepsie mit einer schrittweisen Reduktion der Dosis erfolgen, um die Wahrscheinlichkeit vermehrter Anfallsaktivität zu verringern. Zonegran enthält eine Sulfonamidgruppe. Nebenwirkungen, die mit Arzneimitteln, welche eine Sulfonamidgruppe enthalten, im Zusammenhang gebracht wurden, umfassen: Hautausschlag, allergische Reaktion und hämatologische Störungen. Zonegran ist bei Patienten, die gleichzeitig Carboanhydraseinhibitoren wie Topiramat erhalten, mit Vorsicht anzuwenden. **UW:** Die häufigsten Nebenwirkungen in kontrollierten Studien mit Zonegran als Zusatztherapie waren Schläfrigkeit, Schwindel und Anorexie. **IA:** Zonisamid wird teilweise über CYP3A4 (reduktive Spaltung) sowie über N-acetyl-Transferase und Konjugation mit Glucuronsäure metabolisiert. Daher können Substanzen, die diese Enzyme induzieren oder inhibieren können, die Pharmakokinetik von Zonisamid beeinflussen. **Liste B.** Weitere Informationen entnehmen Sie bitte dem Arzneimittel-Kompendium der Schweiz.

* Marmarou A, Pellock JM. Zonisamide: physician and patient experiences. Epilepsy Research 2005;64(1–2):63–69.

Eisai Pharma AG, Schaffhauserstrasse 611, CH-8052 Zürich
Tel. +41 44 306 12 12, Fax +41 44 306 12 80, www.eisai.ch

hhc
human health care

E003300011-10/2006; www.pils.ch

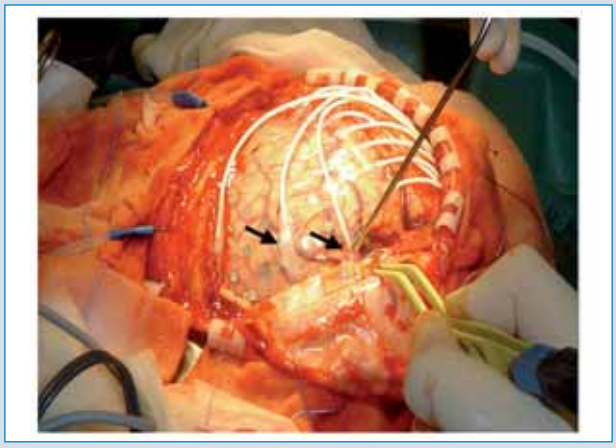

Figure 7: 2 year-old boy with symptomatic partial status epilepticus in the context of an extensive left posterior dysplasia. Per-operative view of a subdural grid of 8x8 contacts on the parieto-occipital cortex. The black arrows indicate additional interhemispheric subdural strips of 8 contacts.

ral strips and grids contacts in order to manually report their position onto a 3D rendered view of the cortical surface obtained from the pre-implantation MR [17]. This new 3D volume, combining precise anatomy and electrodes position, can now serve as a template onto which the results of the electrophysiological evaluation can be transferred to each electrode location; this integrated dataset can finally be fed into a neuronavigation system to display, during the surgery, the electrophysiological information in relation with the cortical surface [17].

Conclusion

Multimodal imaging, image co-registration and the use of image-guidance techniques have increased the confidence and safety of epilepsy surgery, particularly in cases of non-lesional epilepsy. The recent insights in anatomical and functional imaging gleaned during the preoperative evaluation as well as the significant developments of signal (EEG) and image (co-registration algorithms) processing tools have provided information of higher accuracy regarding the localization of epileptogenic zones and the mapping of functional brain areas. This information can easily be displayed on image-guided systems in the operative theatre and, coupled with intraoperative electrophysiological monitoring, appears to be helpful to tailor the surgery and hence improve the outcome while minimizing neurological deficits. However, despite these advances, the permanent dialogue between the epileptologist and the neurosurgeon, possibly during the surgery itself, as well as a better comprehension of epileptogenic diseases, remain a key factor in the success of epilepsy surgery.

References

1. *Cizek J, Herholz K, Vollmar S et al. Fast and robust registration of PET and MR images of human brain. Neuroimage 2004; 22: 434-442*
2. *Morris K, O'Brien TJ, Cook MJ et al. A computer-generated stereotactic "Virtual Subdural Grid" to guide resective epilepsy surgery. AJNR Am J Neuroradiol 2004; 25: 77-83*
3. *Murphy MA, O'Brien TJ, Morris K, Cook MJ. Multimodality image-guided surgery for the treatment of medically refractory epilepsy. J Neurosurg 2004; 100: 452-462*
4. *Mehta AD, Labar D, Dean A et al. Frameless stereotactic placement of depth electrodes in epilepsy surgery. J Neurosurg 2005; 102: 1040-1045*
5. *Murphy MA, O'Brien TJ, Cook MJ. Insertion of depth electrodes with or without subdural grids using frameless stereotactic guidance systems-technique and outcome. Br J Neurosurg 2002; 16: 119-125*
6. *Holowka SA, Otsubo H, Iida K et al. Three-dimensionally reconstructed magnetic source imaging and neuronavigation in pediatric epilepsy: technical note. Neurosurgery 2004; 55: 1226*
7. *Stefan H, Nimsky C, Scheler G et al. Periventricular nodular heterotopia: A challenge for epilepsy surgery. Seizure 2007; 16: 81-86*
8. *Oertel J, Gaab MR, Runge U et al. Neuronavigation and complication rate in epilepsy surgery. Neurosurg Rev 2004; 27: 214-217*
9. *Wurm G, Wies W, Schnizer M et al. Advanced surgical approach for selective amygdalohippocampectomy through neuronavigation. Neurosurgery 2000; 46: 1377-1382*
10. *Van Roost D, Schaller C, Meyer B, Schramm J. Can neuronavigation contribute to standardization of selective amygdalohippocampectomy? Stereotact Funct Neurosurg 1997; 69(1-4 Pt 2): 239-242*
11. *Wurm G, Ringler H, Knogler F, Schnizer M. Evaluation of neuronavigation in lesional and non-lesional epilepsy surgery. Comput Aided Surg 2003; 8: 204-214*
12. *Cho DY, Lee WY, Lee HC et al. Application of neuronavigator coupled with an operative microscope land electrocorticography in epilepsy surgery. Surg Neurol 2005; 64: 411-417*
13. *Kaibara T, Myles ST, Lee MA, Sutherland GR. Optimizing epilepsy surgery with intraoperative MR imaging. Epilepsia 2002; 43: 425-429*
14. *Nimsky C, Ganslandt O, Fahlbusch R. Functional neuronavigation land intraoperative MRI. Adv Tech Stand Neurosurg 2004; 29: 229-263*
15. *Mahvash M, Konig R, Urbach H et al. FLAIR-/T1-/T2-co-registration for image-guided diagnostic and resective epilepsy surgery. Neurosurgery 2006; 58(1 Suppl): ONS69-75*
16. *Rutka JT, Otsubo H, Kitano S et al. Utility of digital camera-derived intraoperative images in the planning of epilepsy surgery for children. Neurosurgery 1999; 45: 1186-1191*
17. *Wellmer J, von Oertzen J, Schaller C et al. Digital photography and 3D MRI-based multimodal imaging for individualized planning of resective neocortical epilepsy surgery. Epilepsia 2002; 43: 1543-1550*

Address for correspondence:
Dr Shahan Momjian
Service de Neurochirurgie
Hôpitaux Universitaires de Genève
Rue Micheli-du-Crest, 24
CH 1211 Genève 14
Tel. 0041 22 372 3426
Fax 0041 22 372 8220
Shahan.Momjian@hcuge.de

The Role of Amygdala in Emotional and Social Functions: Implications for Temporal Lobe Epilepsy*

Chiara Cristinzio[1,2] and Patrik Vuilleumier[1,2]
[1]Laboratory for Behavioural Neurology & Imaging of Cognition, Department of Neuroscience & Clinic of Neurology, University of Geneva
[2]Swiss Center for Affective Sciences, University of Geneva

Summary

Temporal lobe epilepsy is among the most frequent causes of chronic and drug-resistant seizure disorders. It is typically associated with lesions involving critical limbic structures within the anterior medial temporal lobe, such as the amygdala and hippocampus. While the role of the hippocampus and adjacent cortical regions in memory function is now well established, the role of the amygdala and related brain circuits is still poorly known. The amygdala is a complex neural structure implicated in several aspects of emotional and social behaviour, but the varieties and the consequences of amygdala dysfunction in patients with temporal lobe epilepsy remain unclear, and insufficiently examined in standard neuropsychological assessments. Here we review data from recent research in humans indicating that amygdala lesions may impair selective domains of affect and cognition, all related to the appraisal of emotional and social significance of sensory events. We describe neurophysiological and behavioural evidence to illustrate how the amygdala may contribute to a wide range of affective functions, including recognition of facial expressions, perception of gaze direction, modulation of attention and memory, perception of musical emotions, theory of mind, plus mood and psychiatric disorders. We argue that a more systematic assessment of affective functions mediated by the amygdala and related circuits might provide useful information about temporal lobe pathology and neuropsychological outcome after surgery.

Epileptologie 2007; 24: 78 – 89

Key words: Facial expression recognition, temporal lobe epilepsy, eye gaze, perception, emotional memory

Le rôle de l'amygdale dans les fonctions émotionnelles et sociales : conclusions pour l'épilepsie du lobe temporal

L'épilepsie du lobe temporal est une des causes les plus fréquentes de maladies chroniques et réfractaires aux traitements se révélant par des crises. Elle est typiquement associée à des lésions de structures limbiques critiques au sein du lobe temporal antérieur médial telles que l'amygdale ou l'hippocampe. Tandis que le rôle de l'hippocampe et des régions corticales adjacentes dans le fonctionnement de la mémoire a fait l'objet d'études étendues, celui de l'amygdale et des régions du cerveau y liées reste encore largement inconnu. L'amygdale est une structure neurale implexe qui participe à de nombreux aspects du comportement émotionnel et social. Cependant, nous ne possédons pas une vision très claire des différentes dysfonctions possibles de l'amygdale et de leurs conséquences pour les patients atteints d'une épilepsie du lobe temporal et elles sont insuffisamment saisies lors d'examens neuropsychologiques standard. Nous rapportons ici les résultats d'études récentes sur l'homme suggérant que les lésions de l'amygdale pourraient affecter des zones déterminées liées à l'affect et à la cognition, affects et perceptions qui seraient tous associés à l'appréciation d'impressions sensorielles importantes pour l'interaction émotionnelle et sociale. Nous décrivons des signes neurophysiologiques et comportementaux pour montrer en quoi l'amygdale peut jouer un rôle dans un vaste éventail de fonctions affectives, y compris la reconnaissance d'expressions faciales, la perception d'orientations du regard, les altérations de l'attention et de la mémoire, la perception de sentiments musicaux, la capacité de se mettre en pensée à la place d'autres personnes (theory of mind), les humeurs et les troubles psychiatriques. Nous estimons qu'une étude plus systématique des fonctions affectives de l'amygdale et de ses zones d'influence pourrait fournir des informations importantes sur la pathologie du lobe temporal et sur les conséquences neuropsychologiques d'un traitement chirurgical de l'épilepsie.

Mots clés : reconnaissance d'expressions faciales, orientation du regard, perception, mémoire émotionale

*** Acknowledgements**
This work was supported by a grant of the SNF (No 105311-108187) to David Sander and Patrik Vuilleumier, and by the Swiss National Center for Affective Sciences. We thank David Sander, Gilles Pourtois, and Margitta Seeck for their collaboration and insightful discussions during this research.

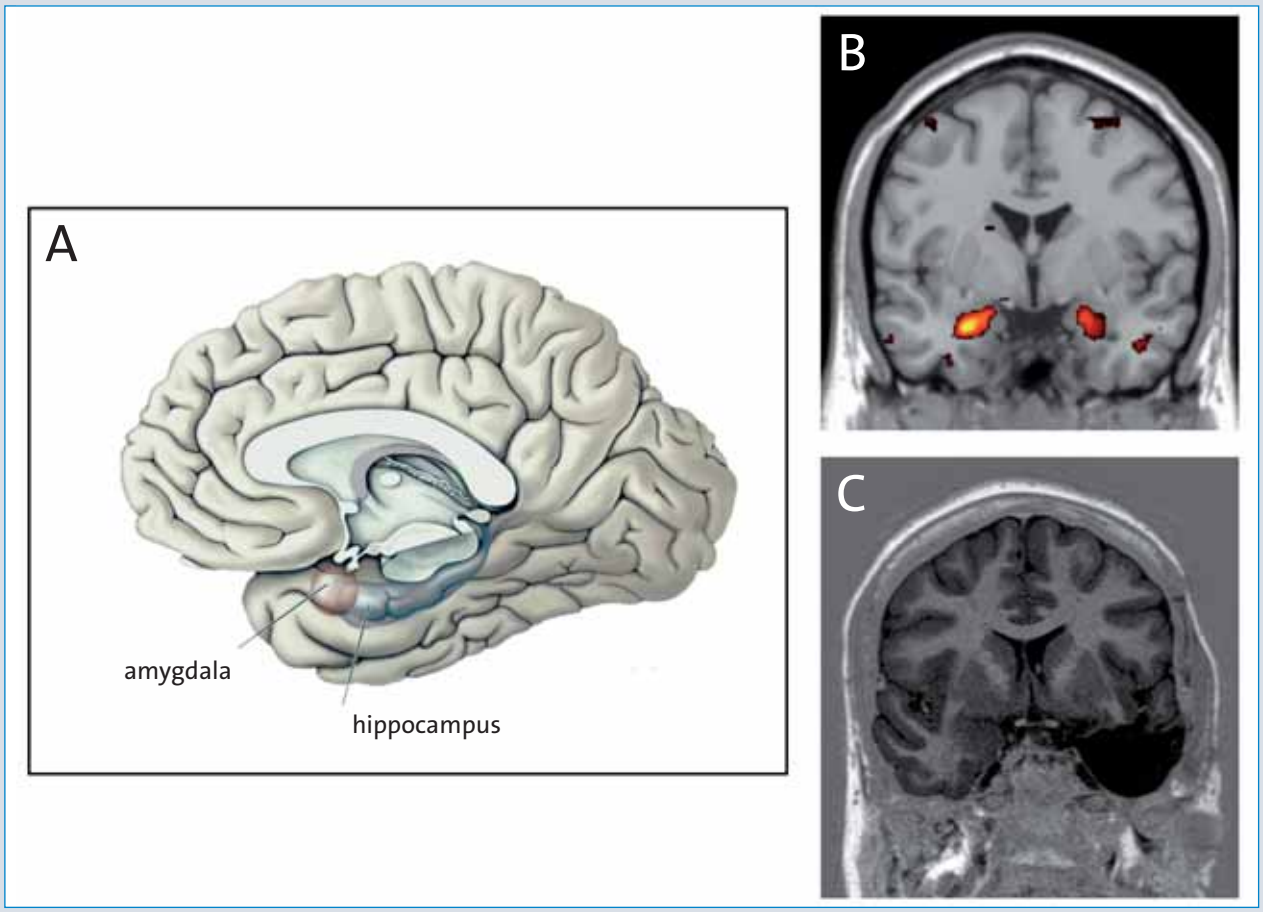

Figure 1: (A) Illustration of the anatomy of the medial temporal lobe and location of the amygdala. (B) Activation of amygdala in a healthy subject to fearful relative to neutral face expression. (C) Example of unilateral temporal lobectomy in a patient with refractory epilepsy.

Die Rolle der Amygdala bei emotionalen und sozialen Funktionen: Folgerungen für die Temporallappenepilepsie

Die Temporallappenepilepsie ist eine der häufigsten Ursachen von chronischen und therapieresistenten Anfallskrankheiten. Typischerweise ist sie verknüpft mit Läsionen von kritischen limbischen Strukturen innerhalb des anterioren medialen Temporallappens wie der Amygdala und des Hippokampus. Während die Rolle des Hippokampus und der anliegenden kortikalen Regionen für die Gedächtnisfunktionen heute gut erforscht ist, ist diejenige der Amygdala und der mit ihr in Verbindung stehenden Hirnregionen immer noch weitgehend unbekannt. Die Amygdala ist eine implexe neurale Struktur, die an vielen Aspekten des emotionalen und sozialen Verhaltens beteiligt ist. Die verschiedenen Möglichkeiten von Amygdaladysfunktionen und deren Konsequenzen bei Patienten mit Temporallappenepilepsie sind aber unklar und werden bei neuropsychologischen Standarduntersuchungen unzureichend erfasst. Hier berichten wir über Resultate von kürzlichen Untersuchungen beim Menschen, welche darauf hinweisen, dass Amygdala-Läsionen bestimmte Zonen für Affekte und Kognition beeinträchtigen können, wobei diese Affekte und Wahrnehmungen alle mit der Beurteilung von emotionalen und sozial bedeutsamen Sinneseindrücken verbunden sind. Wir beschreiben neurophysiologische und Verhaltens-Zeichen, um zu zeigen, wie die Amygdala bei einer weiten Reihe von affektiven Funktionen inkl. Wiedererkennen von Gesichtsausdrücken, Wahrnehmung von Blickrichtungen, Veränderungen der Aufmerksamkeit und des Gedächtnisses, Wahrnehmung von musikalischen Gefühlen, die Fähigkeit, sich in das Denken anderer Menschen hineinzuversetzen (theory of mind), Stimmungen und psychiatrischen Störungen eine Rolle spielen kann. Wir meinen, dass eine systematischere Untersuchung von affektiven Funktionen der Amygdala und ihrer Einflussbereiche wichtige Informationen über die Pathologie des Temporallappens und über die neuropsychologischen Folgen einer Epilepsieoperation liefern könnten.

Schlüsselwörter: Wiedererkennen des Gesichtsausdrucks, Temporallappenepilepsie, Blickrichtung, Wahrnehmung, emotionales Gedächtnis

Introduction

The epilepsies are a complex group of disorders characterized by repeated seizures due to paroxysmal changes in electrical brain activity. According to the International Classification of Epilepsies, four main localization-related types of epilepsy can be distinguished: temporal lobe epilepsies, frontal lobe epilepsies, parietal lobe epilepsies, and occipital lobe epilepsies [1]. Temporal lobe epilepsy (TLE) is the most frequent type of focal epilepsy, and the form associated with hippocampal sclerosis is the most prevalent. Aetiology can be genetic, with frequent onset during childhood, or secondary to brain lesion, with variable onset in adult age. Mesial temporal epilepsy is characterized by focal discharges, often with partial complex seizures, associated with an epileptogenic lesion in anterior medial temporal lobe (typically hippocampal sclerosis), and a strong potential for drug resistance [2].

The anterior temporal lobe is composed of several important neuronal structures, including the amygdala, hippocampus, and surrounding cortex **(Figure 1)**, all intimately connected with the limbic system [3]. Although sclerosis of the hippocampus is clearly established in patients with TLE, similar damage to the amygdala is also frequent. Just as hippocampus lesions, amygdala damage in TLE may be either unilateral or bilateral, but it can occur independent of hippocampus lesion [4]. Thus, a recent MRI study clearly demonstrated that significant amygdala damage may sometimes be found even when no evidence of hippocampal sclerosis or atrophy is detected [4]. However, in the majority of patients, amygdala sclerosis appears together with hippocampal damage, and both lesion sites may therefore contribute to the clinical manifestations.

The amygdala is a complex neural structure, composed of many subdivisions with different cytoarchitectonic and connectional characteristics, which plays a major role in emotional and social processes. Such a role in the affective domain has been supported by a large amount of neurobiology research in animals as well as functional neuroimaging in healthy humans [5]. However, neuropsychological deficits due to amygdala damage are still poorly known, despite several studies that reported selective impairments in emotional and social functions in patients suffering from focal lesions or destruction of the amygdala. Because these studies were frequently conducted in rare cases with rare structural lesions, still little is known about the nature and prevalence of neuropsychological consequences of amygdala damage in TLE. In epilepsy patients, amygdala damage may result from idiopathic sclerosis; but also from various tumoral or pseudo-tumoral diseases arising in the temporal lobe; from progressive calcification associated with Urbach-Wiethe syndrome; or from surgical removal or lobectomy to cure pharmacoresistant seizures **(Figure 1)**. Yet, deficits in emotional and social processes have rarely been investigated in a systematic manner. Most of the neuropsychological research and clinical assessment in TLE has traditionally focused on memory function, associated with hippocampus and temporal neocortex. However, as we review here, amygdala lesions can cause a wide range of distinctive manifestations in emotion and social cognition. We believe that a more systematic exploration of such manifestations might be warranted to improve both the management of TLE and the understanding of human amygdala functions.

Seizure affecting the amygdala and interconnected regions (such as anterior temporal cortex, ventromedial cortex, or insula) may also produce acute disturbances in emotional experience and behaviour, such as ictal fear, grimacing, or screaming [6, 7]. However, in the present review we will not address this issue, but rather focus on the selective neuropsychological deficits associated with amygdala lesions, which may arise either prior or after surgery for epilepsy, and concern a wide range of emotional and social processes. Our goal is not to provide an exhaustive review of amygdala functions or TLE manifestations, but to illustrate the importance of medial temporal lobe structures in affective processing, and to emphasize the need for the development of appropriate tests in the neuropsychological assessment of these patients.

The role of the amygdala in emotions

A crucial role of the amygdala in emotional and social processing has long been proposed on the basis of focal lesion studies in primate as well as other animal species. A first classic observation was reported by Klüver and Bucy [8] who found that extensive, bilateral removal of the anterior temporal lobes led to a highly distinctive pattern of severe behavioural changes, characterized by a loss of emotional reactivity and lack of fear responses (tameness), as well as hypersexuality, orality, hypermetamorphosis, and visual agnosia. Subsequent work by Weiskrantz [9] revealed that the behavioural and emotional abnormalities associated with the Klüver-Bucy syndrome could be produced by lesions of the amygdala region alone. This finding has then been replicated many times in monkeys [10, 11] following complete destruction of the amygdala and its connections in both hemispheres.

However, it is now thought that the full symptoms of Klüver-Bucy syndrome, including some aspects of hypo-emotionality, may reflect the extent of the lesions to adjacent structures in the rhinal and polar temporal cortices, as well as in the white matter connecting temporal regions with orbitofrontal cortex [12, 13], rather than damage to the amygdala itself. Focal lesions produced by local infusion of cytotoxic agents produce a more selective destruction of amygdala neurons, sparing neighbouring axonal tracts, and thus lead to less dramatic disturbances than amygdala destruction

by surgical removal or aspiration. Moreover, in humans, a complete form of the Klüver-Bucy syndrome is rarely, if ever, observed after damage to the amygdala, unless such damage extends to other limbic regions within temporal, insular, and orbitofrontal areas [14, 15]. This is best exemplified by the famous patient HM who suffered from severe amnesia after bilateral temporal lobectomy, which included both the amygdala and anterior hippocampus. HM is reported to show some signs of emotional indifference but no other striking disorders in affective and social behaviour.

The rarity of Klüver-Bucy syndrome in humans may reflect the fact that other regions in temporal and frontal cortex play a greater role in the control of emotional and social functions, as compared with other primates, such that lesions to one single area within this neural network may not be sufficient to produce similar disorders. Alternatively, amygdala functions may have changed in humans over the course of evolution, perhaps due to the greater complexity and influences of cortical interactions which could have resulted in a somewhat different processing role. Several patients with bilateral amygdala damage have now been reported in the literature and extensively studied in the past two decades, but their deficits are relatively subtle as compared with emotional and social disturbances previously associated with the Klüver-Bucy syndrome. Moreover, the deficits are quite variable across cases [16]. Thus, in humans, the exact role of the amygdala in emotion and social cognition, and the exact deficits caused by selective amygdala lesions, still remain unresolved. Nevertheless, neuropsychological studies of the rare patients have clearly established the existence of selective impairments in a variety of affective and social domains, as we will review in details below. Taken together, these studies clearly indicate that the human amygdala play a major role in assigning affective values and recognizing emotional meaning of environmental stimuli, including faces, voices, or other events. Accordingly, patients with amygdala dysfunction show deficits of various degrees in processing and learning the affective values of stimuli, particularly those associated with a negative or aversive content (see below).

A major role of the amygdala in aversive or threat-related processing is further suggested by studies of fear-conditioning in animals [17]. A large body of work in neurophysiology and molecular biology has now clearly established that the amygdala is involved in pavlovian associative learning situations, where an innocuous stimulus (e.g. a tone) is paired with a noxious event (e.g. a electric shock): after a few pairings, the initially neutral stimulus (conditioned stimulus, CS+) will elicit a set of behavioural and physiological responses that are indicative of fear (e.g. freezing, tachycardia, increased blood pressure, sweating, papillary dilatation) even in the absence of the threatening event (unconditioned stimulus, US). Such fear-conditioning has been extensively studied in a variety of animal species, and shown to depend on amygdala integrity, including in humans [5]. Furthermore, different aspects of the acquisition and expression of fear responses have been shown to depend on different subregions within the amygdala, which can be separately disrupted by different types of lesions or neuropharmacological interventions.

In epilepsy patients, amygdala lesions arising due to sclerosis, calcifications, tumoral diseases, or surgery are typically unilateral. As a consequence, any emotional and social deficits after unilateral lesion can potentially be alleviated by the intact amygdala on the opposite side. However, as for memory disturbances, the impact of unilateral damage or surgery might depend on the presence of subclinical anomalies in the other hemisphere, and therefore vary across patients. Moreover, the severity of lesion (e.g. sclerosis) or the extent of surgical resection (cortical and subcortical) may also differ across patients, and thus produce distinct patterns of deficits, rather than a complete loss of amygdala functions. Furthermore, epileptic activity and/or underlying pathology may induce slowly progressive changes in the functional organization of the medial temporal lobe, such that removal of neuronal tissue on the affected side may not produce similar deficits after surgery as would be expected if such removal was made in a healthy brain. Likewise, amygdala dysfunction arising in early childhood, or later during life, is likely to result in distinct degree of neuronal plasticity and reorganization, and perhaps to differentially affect the development of emotional and social functions (see below). Accordingly, the type and severity of emotional deficits associated with amygdala damage in temporal lobe epilepsy will certainly depend not only on the nature and site of the underlying disease but also on the age of onset, its time-course, and duration.

Moreover, some studies have suggested that amygdala function may be influenced by laterality as well as by gender, with slightly different roles in the right vs left hemisphere [18], and different degrees of hemispheric asymmetry in men vs women [19]. These factors may therefore also influence the nature of emotional symptoms caused by right or left amygdala dysfunction.

Finally, it is important to bear in mind that epilepsy patients are usually treated by one or several drugs that can have direct effects on neural activity within the amygdala and other limbic brain regions. Indeed, many anti-epileptic drugs also have psychotropic effects on mood, arousal, and learning. These effects might potentially interact with some emotional processes normally associated with amygdala function, and hence contribute to the pattern of anomalies seen in temporal lobe epilepsy patients. However, the exact interplay between these different factors also remains poorly known.

Anatomy and physiology of the amygdala

A great deal of knowledge has accumulated over the last years concerning the precise anatomical organization of the amygdala, particularly through the study of fear conditioning in mice and rats. However, less is known about the amygdala in primates, although the general structure and function appear remarkably shared across the different species. Comparative studies suggest that the relative size of the amygdala has increased rather than decreased in primates and humans, as compared with smaller animals, especially for the more lateral and basal subnuclei that are strongly connected to cortical brain regions. Thus, much of what is known about amygdala functions in rodents is thought to also apply to primates, but presumably with a much richer repertoire of interactions between amygdala and neocortex in humans.

Anatomically, the amygdala is not a homogenous structure. It contains more than 15 different nuclei that are interconnected together to form different processing circuits, each with distinct specialized functions [20, 21]. It is therefore often preferable to refer to this structure as the "amygdaloid complex", particularly because it is often difficult to distinguish between different subnuclei with conventional imaging techniques (including MRI or fMRI). These nuclei can be schematically grouped into a few major functional units. The lateral nucleus receives sensory inputs from neocortical areas in all modalities, and thus constitutes the main site of convergence for afferent information about the association between stimuli during fear-conditioning. However, olfactory inputs enter the amygdala by a different route, via corticomedial nuclei and periamygdaloid cortex. The lateral nucleus then projects to all other nuclei, in particular the basal, accessory basal, and central nuclei. The central nucleus provides the main output system projecting to various brain areas that are involved in the behavioural expression of emotional responses (e.g. fear), such as the hypothalamus (for sympathetic autonomic responses and stress hormone release), brainstem (for freezing or startle), cholinergic nuclei in basal forebrain (for arousal and attention), etc. The basal nucleus receives information from both the lateral nucleus and other brain regions such as orbitofrontal cortex and hippocampus, and in turn projects to the central nucleus, as well as to several cortical regions and hippocampus. This pattern of connectivity suggests that the basal nucleus may serve to integrate contextual information with incoming sensory information in order to modulate the emotional responses orchestrated by central nucleus and other target regions [22]. For example, studies of fear conditioning have shown that inputs from the hippocampus to the amygdala are involved in the association of fear responses with a specific place or context [23]; whereas inputs from ventromedial frontal areas play a crucial role in the inhibition of fear responses during the extinction of conditioning [24]. Furthermore, neural processing within amygdala circuits can also be finely controlled by various other modulatory afferents, including dopamine, hormones, or neuropeptides such as oxytocine and orexin.

This complex functional architecture testifies that the amygdala complex occupies a key position at the interface between the appraisal of external environmental events and adjustment of internal motivational processes. This privileged position makes it capable of eliciting and learning adaptive responses to various stimuli with intrinsic or acquired affective values, including social cues, as we will describe in more details in the following sections of this review. However, in humans, relatively little is known about the role of different subregions of amygdala in different aspects of emotional behaviour. Recent functional brain imaging studies [25, 26] converge with neurophysiology data in monkeys to point to the same general principles of organization. Nevertheless, it is conceivable that distinct patterns of emotional or social disorders might be associated with different types of lesion or dysfunction within amygdala circuits. Elucidating these differences is clearly a challenge for future research.

Recognition of facial emotional expressions

A large body of neuropsychological and neuroimaging studies has demonstrated an implication of the amygdala in the recognition of facial expression of emotions (for reviews see [27, 28]). In particular, many observations have supported the hypothesis of a specialisation of amygdala responsiveness to negative emotions, especially fear, but also anger and sadness.

The most famous case reported in the literature is that of SM, a 40-year-old woman who has complete bilateral amygdala destruction resulting from Urbach-Wiethe disease [29]. Her rare pathology has allowed a detailed study of the role of amygdala across a range of face processing tasks. Overall, she shows a disproportionate impairment in recognizing fear in facial expressions, and only a much milder impairment in recognizing the intensity of related emotions such as surprise and anger [29]. She is also impaired at making judgements of other subtle aspects of facial appearance that have particular threat or social meaning, such as perceived trustworthiness.

Likewise, in patients with temporal epilepsy, several recent studies have now also reported significant deficits in the recognition of facial emotions, presumably caused by amygdala pathology. Such deficits have been observed in patients with mesial sclerosis lesions [30, 31] or after anterior lobectomy for surgical treatment [32]. Some reports have emphasized more frequent deficits with right than left hemisphere disease, and with an early age at epilepsy onset, consistent with a right-hemisphere dominance in emotion and face processing.

This selective loss for fear recognition is paralleled with a disruption of fear conditioning in some cases with unilateral temporal lobe damage [33]. Remarkably, however, these patients may still be able to produce appropriate fear expressions on their own face when verbally instructed to do so, even though they fail to recognize the same expression presented visually in pictures or movies. According to some authors, patients with bilateral temporal lobe lesions might show more extensive deficits, affecting not only the recognition of fear, but also disgust, anger, sadness, and even happiness in faces (and perhaps in other modalities, e.g. voices) [34] – unlike the selective deficit for fear in patient SM who has bilateral lesions restricted to the amygdala. These findings suggest that some other cortical areas within the temporal pole, more extensively damaged after epilepsy surgery, might also contribute to expression recognition deficits. In addition, some patients with amygdala damage due to Urbach-Wiethe disease do not show deficits for a single emotion category (e.g. fear), but make more confusions between categories and report "blends" of emotion more often than normal controls do [35].

Selective impairments in the visual recognition of fearful expressions may arise without any corresponding deficits in the subjective experience of fear and anxiety in everyday life. For instance, Anderson and Phelps [36] investigated self-evaluation of emotion states in amygdala-damaged patients and healthy control subjects. They observed that patients described their emotional life not differently than controls, and concluded that the amygdala is not necessarily implicated in the generation of affective states. But different results were reported by Tranel and colleagues [37]. They investigated personal feelings of emotion in SM (the same patient with bilateral amygdala destruction as described before; see [29]). These authors observed that when SM reports events of her life, the content of her reports misses negative emotions or subjective threat experiences: even when she talks about negative events or illnesses, no negative emotional state is verbally conveyed, making her appear as "brave" and "unusually courageous" in the face of her medical disease for other naive observers. Thus, in this case, the deficit in recognizing negative facial emotions was accompanied by a parallel defect in negative experiential aspects of emotional life.

Finally, recent observations in patient SM suggest that her deficit in recognizing fearful expressions might result at least in part from an abnormal scanning of faces, with a lack of exploration of the eye region in faces, where the critical "diagnostic" features of fear expression are present. Thus, when instructed to look at the eyes in faces, SM can significantly improve her recognition of fearful expressions. This finding points to an important role of eye information in driving amygdala responses, and of active visual exploration for accurate recognition of expressions.

Eye gaze perception

While facial expressions of emotion are an important source of information in normal communicative and social life, concomitant information conveyed by eye gaze is also crucial to appropriate interpretation and interaction between individuals. Several studies have emphasized an implication of the amygdala in processing both facial emotion and eye gaze. It has been reported that eye cues are sufficient to produce a threat superiority [38] in healthy subjects. Direction of eye gaze also informs about the emotional state and intention of other individuals.

In the context of some expressions of emotion, the direction of gaze can modulate the interpretation of emotional state perceived from the other. Thus, Adams et al. [39] reported that perception of anger expression is enhanced for faces with straight/direct eye-gaze, whereas perception of fear expression is enhanced in faces with averted/deviated gaze. Recently, Sander et al. (in press) also investigate the perceived intensity of emotion in faces when gaze was direct or averted. They used dynamic faces expressing anger, fear, or happiness. They observed that angry faces with direct gaze were perceived as expressing more intense anger than with averted gaze. Inversely, fearful faces with averted gaze were perceived as expressing more intense fear than with direct gaze. These results support appraisal theories of emotion [40] according to which the interaction between both facial expression and gaze direction can modulate the personal relevance of stimuli, and hence the resulting emotion. However, two fMRI studies investigated whether such effects were mediated by amygdala and reported contradictory results. A first study [41] confirmed this interaction between gaze direction and expression, with greater amygdala activation to fearful faces with averted gaze and to angry faces with straight gaze. But conversely, a second study [42] found that angry faces with averted gaze and fearful faces with straight gaze elicited stronger left amygdala responses, as compared with angry faces with direct gaze and fearful faces with averted gaze, which was attributed to the fact that threat signals were more ambiguous in the former than the later situation. Other imaging results suggest that the amygdala may be particularly sensitive to the perception of eye-gaze contact, a facial cue with particular affective relevance in interpersonal interactions [43, 44]. Neuropsychological findings in a patient with a large temporal lobe lesion including the amygdala also indicate a deficit in discriminating between different eye gaze direction in faces [45]. However, to our knowledge, no study has yet investigated whether such tasks might reveal deficits in temporal lobe epilepsy.

Gaze direction can also provide important signals to orient attention in space. Seeing a face with gaze deviated can induce a reflexive shift in attention towards the gazed-at location [46, 47]. A recent study has investiga-

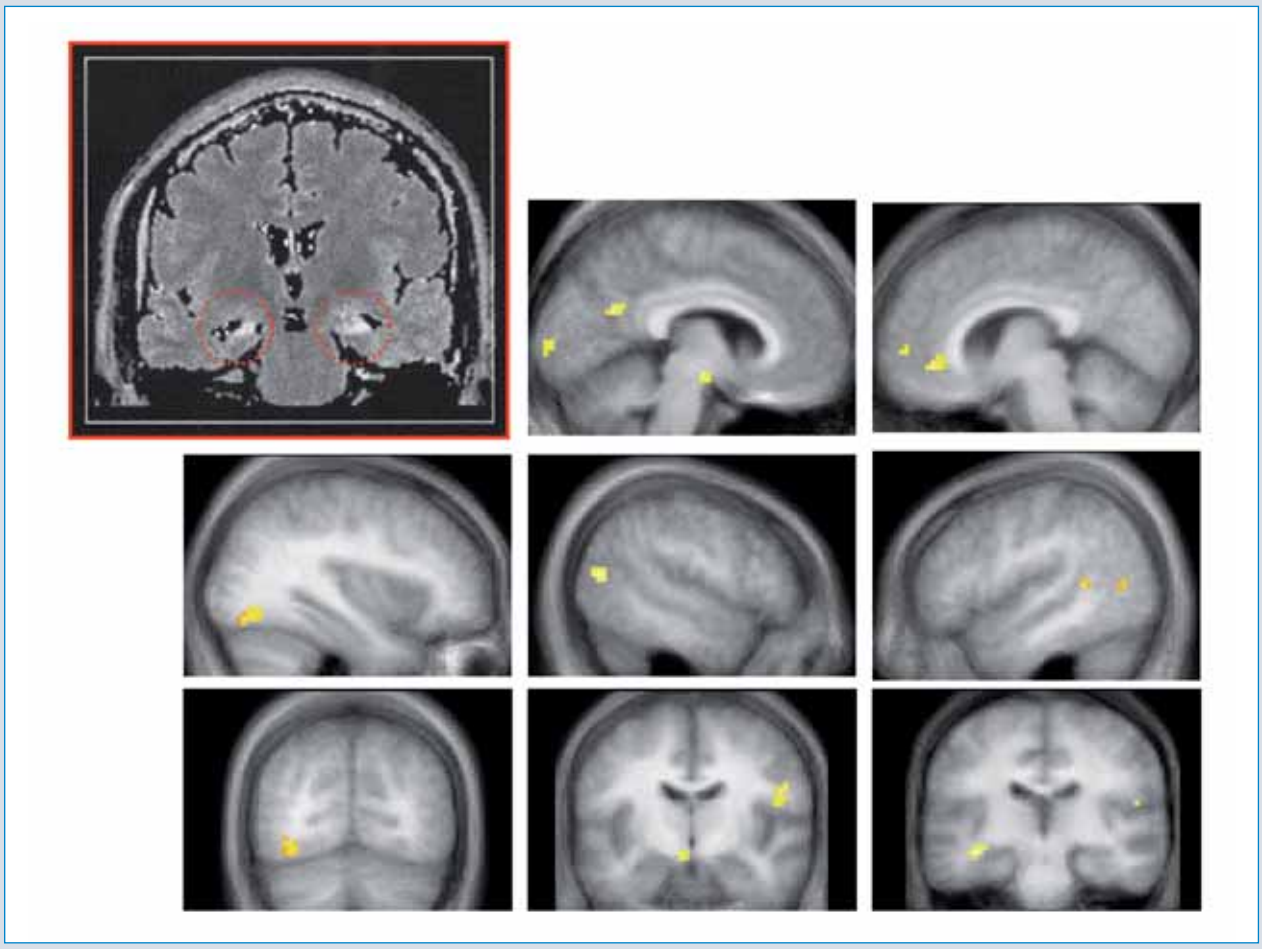

Figure 2: Consequences of amygdala lesion on neural activity in distant cortical areas. The upper left panel shows a coronal brain section on T2-FLAIR MRI, demonstrating bilateral sclerosis in the amygdala-hippocampal region in a patient with temporal lobe epilepsy. All other panels show fMRI activations in brain areas responding less to fearful face expression in patients with amygdala sclerosis, relative to patients with hippocampal sclerosis only. These areas include (from top to bottom, left to right): visual cortex, retrosplenial cortex, anterior cingulate, fusiform gyrus, bilateral posterior superior temporal sulcus, hypothalamus, somatosensory cortex, and peri-hippocampal regions. (Adapted from Vuilleumier et al., 2003).

ted these effects in patients with amygdala damage subsequent to lobectomy for epilepsy surgery, and found a selective deficit in attentional orienting by perceived gaze direction. In this study, attention was manipulated in a simple visual detection task by using two kinds of stimuli to indicate the position of an upcoming target: a photograph of a face with gaze averted either rightward or leftward; and a schematic arrow pointing either rightward or leftward (all presented centrally on a computer screen). Results revealed that healthy subjects show a congruency effect (i.e. faster reaction times) when the target appears in the position indicated by gaze as well by the arrow. By contrast, patients with amygdala lesions showed a specific deficit in orienting attention to the direction indicated by gaze, but normal orienting when direction was indicated by the arrow. Taken together, these findings indicate that some anomalies in the perception of, and reaction to, eye gaze direction in faces may provide a useful measure of amygdala integrity.

Emotional influences on perception and attention

The amygdala and related limbic areas are not only responsible for appraising the affective value of external stimuli or events, but also critically involved in orchestrating adaptive responses to emotionally relevant information, such as modulating perceptual analyis and attention. Anatomical studies have shown strong bidirectional connections between amygdala and sensory cortical regions, with important feedback projections from the amygdala to sensory areas which might serve to modulate perceptual processing taking place in these regions [22]. Such modulatory influences might be responsible for the enhanced activation of sensory areas in response to emotional stimuli, as compared with neutral stimuli, a typical finding in many functional brain imaging studies in humans [48, 49] that may facilitate detection and subsequent memory for emotional stimuli [50].

Damage to the amygdala in temporal lobe epilepsy can therefore also impair this modulatory feedback of emotional processes on cortical sensory function and perception. Such a deficit was demonstrated in a recent fMRI study of medial temporal lobe sclerosis that compared patients in whom sclerotic lesions involved the hippocampus alone, but not the amygdala, with patients in whom sclerosis involved both the hippocampus and the amygdala [51]. During this fMRI study, patients had to perform a same/different judgment task on pictures of faces or houses, while faces could have either a neutral or fearful expression. Severity of medial temporal lobe sclerosis was determined independently by the intensity of T2 signal on FLAIR MRI scans. Results from the fMRI task showed normal activation in fusiform cortex when the task required face judgments, and normal activation in parahippocampal cortex when the task required house judgments, just like expected from healthy subjects. By contrast, the enhancement of fusiform activation to fearful vs neutral faces was seen in patients with sclerosis affecting the hippocampus alone, but not in those with sclerosis affecting the amygdala in addition to hippocampus **(Figure 2)**. This difference was found even though the two groups of patients did not differ otherwise, had the same clinical epilepsy history and drug treatment, and performed at the same level on standard cognitive tasks. Moreover, amygdala lesions had a predominant impact on visual activation in the same (ipsilateral) hemisphere, such that the greater the sclerosis in left amygdala, the weaker the emotional response to fearful face expressions in left fusiform cortex; and conversely, the greater the sclerosis in right amygdala, the weaker the response to fearful expressions in right fusiform.

In addition, this fMRI study [51] also showed that amygdala lesion (right or left) altered the normal pattern of activations to fearful face expressions in a variety of other intact brain regions, suggesting that activity in these regions may normally be influenced by amygdala processing, but be impaired as a consequence of amygdala sclerosis. Regions showing such a loss of emotional effect due to amygdala lesion included the rostral anterior cingulate cortex (rACC), retrosplenial cortex, superior temporal sulcus (STS), secondary somatosensory cortex (SII), and hypothalamus **(Figure 2)**. All these regions have previously been associated with some aspects of affective or social processing. For instance, rACC is involved in emotion regulation and depression [52]; STS is involved in theory of mind and eye gaze perception [53], whereas SII is implicated in somatic markers and facial mimicry during extinction recognition [54]. These fMRI results therefore indicate that abnormal amygdala function due to sclerosis and epilepsy may alter a large cortico-subcortical network of regions normally engaged by emotional face expression and social cognition. However, the exact behavioural correlates of such distant consequences of temporal lobe sclerosis still remain unknown.

It is generally thought that a likely function of the increased activation of sensory areas in response to emotional stimuli [48, 55] is to enhance perceptual analysis, and perhaps subsequent memory traces, for emotionally salient relative to neutral stimuli [50]. In support of this, many studies in healthy subjects have shown an advantage for detecting and/or orienting attention towards emotional stimuli, in conditions where neutral stimuli are typically difficult to detect (e.g. visual search, attentional blink). Remarkably, such facilitation is abolished in patients with amygdala lesion or anterior temporal lobectomy [56]. This surprising finding that amygdala disease can impair visual perception in detection tasks underscores the major role of amygdala in modulating cortical visual pathways, and the important interactions between emotion and attention processes.

Emotional memory

Beyond modulating perceptual analysis, the amygdala has also been shown to be critical for emotional memory, by enhancing the storage (and perhaps retrieval) of affectively salient events. Thus, recall is typically better for emotional relative to neutral material. Several studies have found deficits of emotional memory in epilepsy patients with temporal lobectomy and amygdala damage.

In a recent work [34], lobectomy patients were initially presented with a series of sentences containing neutral and emotional target words, and then tested one hour later on a recognition task where these target words were presented using a forced choice paradigm. Results showed that memory for emotional items was impaired after bilateral temporal lobe damage, while the performance of unilateral patients was comparable to that of healthy controls. Emotional memory therefore appears to be more adversely affected when lesions to the amygdala are bilateral. Another study [57] on verbal emotional memory reported a loss of the normal enhancement for emotional aspects of a story in patients with unilateral amygdala and hippocampus lesions, relative to controls. Recent work in lobectomy patients suggests that such emotional memory deficits may concern the gist more than the details of emotional events [58]. In the latter study, epilepsy patients with unilateral lobectomy were first shown neutral target pictures in the context of either a neutral or an emotional story (determined by the content of other pictures); and then they were tested on the next day by asking them to recall these target stimuli, in response to a fixed set of questions about the gist and details of each story. Results showed a specific impairment in emotional memory associated with unilateral damage to medial temporal lobe including the amygdala.

However, in contrast with previous findings, Phelps

et al. [59] reported a study where amygdala-damaged patients did not show any significant deficit on some emotional memory tasks. This study investigated emotional memory in patients with unilateral damage to the medial temporal lobe including both the hippocampus and amygdala. The authors examined memory for emotional words and memory for neutral words embedded in emotional sentences. They found that all groups showed superior recall for positive and negative words in comparison to neutral words; and positive words were recalled significantly more often than negative words. However, no difference was found between unilateral damage patients and healthy controls. The authors concluded that unilateral temporal lobectomy may preserve a normal pattern of performance when recalling affective words. Yet, such effects might partly be mediated by semantic associations rather than by purely emotional influences. Therefore, although some results are still partly contradictory and controversial, it now seems clearly established that the amygdala is crucially involved in processing emotional memories. But more work remains to be done to better characterize the nature of emotional effects on memory, and the possible hemispheric asymmetries for different types of information.

Emotion in music perception

A more recent focus of research is the role of amygdala in the perception of emotion in music. Gosselin et al. [60] have explored the ability to recognize the emotional character of different musical excerpts in a series of patients with unilateral left or right medial temporal lesion, including amygdala, after surgery for epilepsy. Because the amygdala involvement in recognizing fear in faces is well known, these authors were particularly interested in the perception of threat in music. They used musical excerpts composed to induce fear, peacefulness, happiness and sadness; and then asked patients to judge how much of each labelled emotion (threat, peacefulness, happiness and sadness) was present in the music. They found that unilateral lobectomy patients showed a specific deficit in recognition of "scary" music, and this impairment was more pronounced in right hemisphere-damaged patients. It is important to notice that the amygdala was completely removed in all patients, but the lesion involved several other regions, so it is difficult to know if the deficit was due to amygdala damage alone or to some disconnection with other brain structure.

To ascertain the specific contribution of amygdala in recognition of scary music, the same experimental design was administered to patient SM, who has selective bilateral amygdala atrophy due to Urbach-Wiethe disease. This patient has been studied in detail and her selective lesion has already established the role of amygdala in the perception of fear in facial expressions (see above) [29, 61]. In the music paradigm, Gosselin et al. [62] confirmed that her deficit in the recognition of fear extended to musical stimuli. Recognition of joyful music was not impaired. This result emphasizes the specificity of amygdala function in the identification of emotion from music.

Theory of mind

An important aspect of social cognition is the ability to make inferences about others' mental states, an ability that is necessary to interpret people's behaviour, beliefs and intentions. This important aspect of social cognition is named "theory of mind" (ToM) [63, 64], and its reliance on amygdala function is still partly unresolved.

Many tasks have been designed to evaluate the ToM. A classic task is the detection of "faux-pas", i.e., socially inappropriate actions. For instance, a "faux-pas" occurs when a person involuntary makes a remark that he should not have made and that was perceived as hurtful, or insulting. Many studies have demonstrated that this ability, acquired during early childhood, is impaired in some developmental disorders such as autism [64]. Recently, some authors have proposed an implication of amygdala function in ToM, and tested this hypothesis in epileptic patient with lesion involving the amygdala, using various tasks such as the detection of "faux-pas".

Shaw and coworkers [65] compared the effects of early and late developmental damage to the amygdala on ToM abilities. They divided epileptic patients in two groups: "early" and "late" damage. The first included patient who had amygdala dysfunction since the age of their first seizure; the second group consisted of patients in whom amygdala damage occurred at the time of surgical resection, but who had a normal amygdala function before operation. Theory of mind abilities were examined by a "faux-pas" task and other tests. The authors found that only patients with amygdala lesion occurring during the first two decades of life showed deficits in complex abilities of reasoning about the mental states of others. In contrast, subjects with acquired lesions of the amygdala showed no significant impairment in ToM tasks, as compared with a control group of patients.

Different results were provided by a study of Stone et al. [66]. The latter researchers investigated the social abilities of patients with acquired bilateral amygdala lesion due to focal brain injuries, using both the recognition of "faux-pas" and another classic task, the test of "reading the mind in the eyes". This latter task was created by Baron-Cohen et al. [67] to study autistic subjects and consists of photographs showing only the eye region of 25 different faces, from which the participant is asked to decide what the depicted person is feeling or thinking (i.e. envy, seduction, etc.). Stone et al. [66] observed that amygdala-damaged patients per-

EPILEPSIE

Depakine® Chronosphere®

Sphärische Granula mit verlängerter Freisetzung

Der Leibwächter
Ihrer epileptischen Patienten
ihr ganzes Leben lang

50 mg | 100 mg | 250 mg | 500 mg | 750 mg | 1000 mg

Depakine® Chronosphere®. Granulat mit verlängerter Freisetzung, in Sachets. **Zusammensetzung:** acidum valproicum + natrii valproas, entsprechend folgender Menge an Natriumvalproat: Sachets à 50 mg, 100 mg, 250 mg, 500 mg, 750 mg und 1000 mg. **Indikationen:** generalisierte Formen der primären Epilepsie: Petit-Mal/Absenzen, massive bilaterale Myoklonien, Grand-Mal mit oder ohne Myoklonien, photosensible Epilepsie. Sekundäre, generalisierte Epilepsien, vor allem beim West- und beim Lennox-Gastaut-Syndrom. Epileptische Äquivalente mit einfacher oder komplexer Symptomatologie. Epilepsien mit sekundärer Generalisierung. Mischformen. Behandlung manischer Episoden bei Patienten mit bipolaren manisch-depressiven Störungen. Eine günstige Wirkung bei der Prävention manischer Phasen ist nicht belegt. **Dosierung:** Epilepsie: mittlere Tagesdosen bei Monotherapie in einer einzigen Einnahme: 25 mg/kg bei Neugeborenen und bei Kindern, 20–25 mg/kg bei Jugendlichen, 20 mg/kg bei Erwachsenen und 15–20 mg/kg bei älteren Patienten. Bipolare Störungen: Anfangsdosis ist 1000 mg täglich; Erhaltungsdosis liegt zwischen 1000 mg und 2000 mg täglich. **Kontraindikationen:** Akute oder chronische Hepatitis. Schwere Hepatitis in der Familienanamnese, vor allem medikamentöse. Bekannte Natriumvalproat-Überempfindlichkeit. Porphyrie. **Warnhinweise und Vorsichtsmassnahmen:** es wird empfohlen, eine biologische Kontrolle der Leberfunktionen sowie eine hämatologische Untersuchung durchzuführen. Da es ein Risiko schwerwiegender Pankreatitiden gibt, ist eine rasche medizinische Untersuchung bei Patienten, bei denen akute abdominale Schmerzen auftreten, notwendig. Anpassung der Dosierung bei Patienten mit Niereninsuffizienz. **Schwangerschaft, Stillzeit:** Wegen des Risikos für den Fötus müssen die Vorteile einer Behandlung und das eingegangene Risiko gegeneinander abgewogen werden. Das Arzneimittel kann pharmakologische Effekte auf den Säugling bewirken. Das Abstillen wird empfohlen. **Unerwünschte Wirkungen:** Hepatopathien, isolierte Hyperammonämie, Pankreatitiden. Hämatologische Wirkungen: häufig Thrombozytopenie. Wirkungen auf das zentrale Nervensystem: Somnolenz, Hyperaktivität oder Irritabilität. Appetitsteigerung und Gewichtszunahme. Magen-Darm-Störungen: Übelkeit, Magenschmerzen, Diarrhöe. **Interaktionen:** Interaktionen in Verbindung mit der Hemmwirkung von Valproinsäure auf Cytochrome P450 CYP 2C9 und CYP 3A (vor allem mit Neuroleptika, MAO-Hemmer, Antidepressiva und Benzodiazepine, Phenobarbital, Primidon, Phenytoin, Carbamazepin, Lamotrigin, Zidovudin). **Packungen:** Packungen zu 30 Sachets® für alle Dosierungen (B). **Zulassungsinhaberin:** sanofi-aventis (schweiz) ag, 1217 Meyrin. Ausführliche Informationen entnehmen Sie bitte dem Arzneimittel-Kompendium der Schweiz. CH - VPA 06.12.01

sanofi aventis
Das Wichtigste ist die Gesundheit

Orfiril® long
Valproat

Modernste Galenik für Valproat weltweit

4 Dosierungsstärken

Minipacks

Folgende Vorteile sprechen für die Verschreibung von Orfiril® long:

- Die Einnahme von Orfiril® long kann unabhängig von den Mahlzeiten erfolgen.
- Die Orfiril® long Minipacks enthalten wie die Orfiril® long Kapseln kleine retardierte Minitabletten, die sich eingestreut in Flüssigkeit oder weiche Speisen einfach schlucken lassen, selbst bei Schluckschwierigkeiten.
- Orfiril® long kann auch als Einmalgabe verabreicht werden.
- Orfiril® long ist kassenzulässig und spart bis zu 80% Kosten.
- Orfiril® long entspricht den Richtlinien der Europäischen Arzneimittelbehörde (EMEA).

Arzneimittelinformation*
Wirkstoff: Natriumvalproat. Dosierung: mittlere Tagesdosis: 20-30mg/kg KG. Indikationen: Petit-Mal/Absenzen; massive bilaterale Myoklonien; Grand-Mal mit oder ohne Myoklonien; photosensible Epilepsie; sekundäre, generalisierte Epilepsien, vor allem beim West- und beim Lennox-Gastaut-Syndrom; epileptische Äquivalente mit einfacher oder komplexer Symptomatologie (psychosensorielle und psychomotorische Formen); Epilepsien mit sekundärer Generalisierung; Mischformen (generalisierte und äquivalente); manische Episoden bei Patienten mit bipolaren manisch-depressiven Störungen. Unerwünschte Wirkungen: Hepathopathien in seltenen Fällen mit tödlichem Ausgang, besondere Vorsicht bei Säuglingen und Kleinkindern; Hyperammonämie; Pankreatitiden; Blutbildveränderungen; Gerinnungsstörungen; Somnolenz; Haltetremor; Enzephalopathie bei Langzeitkombination mit anderen Antiepileptika; Gewichtszunahme; Übelkeit; Dys- und Amenorrhoe; veränderte Geschmacksempfindung; Amblyopie; Tinnitus; Gehörverlust; Haarausfall; Fanconi-Syndrom; Vaskulitis; Hautreaktionen; Lyell-Syndrom; Stevens-Johnson-Syndrom; polymorphes Erythem. Interaktionen: Acetylsalicylsäure, Carbamezepin, Cimetidin, Erythromycin, Felbamat, Lamotrigin, Mefloquin, Neuropsychotropika, Phenobarbital, Phenytoin, Primidon, Warfarin. Kontraindikationen: Überempfindlichkeit auf valproinsäurehaltige Arzneimittel; Leber- und Pankreasfunktionsstörungen; hämorrhagische Diathese; Anwendung bei Kleinkindern bei gleichzeitiger Behandlung mit mehreren Antiepileptika. Abgabekategorie: B. Vertrieb: Desitin Pharma GmbH, 4410 Liestal. *Ausführliche Angaben siehe Arzneimittelkompendium der Schweiz.

DESITIN
SUCCESS IN CNS

Desitin Pharma GmbH
Gestadeckplatz 2 | 4410 Liestal
Tel. 061 926 60 10 | Fax 061 926 60 15
e-Mail: info@desitin.ch | www.desitin.ch

formed worse than control subjects in both of these tasks probing theory of mind. These results therefore suggest that theory of mind can be impaired by amygdala lesion even if the lesion occurs in adult age. Similarly, Schacher et al. [68] have investigated the ability to detect „faux-pas“ in patients with mesial temporal lobe epilepsy compared to patients suffering from epilepsy originating outside of the mesial temporal lobe. They found that only patients with mesial temporal epilepsy (tested either preoperatively or postoperatively) showed an impairment in the recognition of “faux-pas“, but not those with extra-mesiotemporal epilepsy. No correlation was found with the age of seizure onset. Taken together, these data corroborate the idea that, in humans, the amygdala plays a crucial role in a wide range of complex social abilities, in addition to just fear perception.

Mood and psychiatric disorders

Besides deficits in processing stimuli or events with emotional significance, as reviewed above, temporal lobe epilepsy is frequently associated with mood or psychiatric disorders. The risk of psychiatric comorbidity is 20-40 % in TLE patients, and it is greater in those with a form of drug-resistant epilepsy [69]. Affective disorders, such as depression and anxiety, are the most common disturbances with a prevalence as high as 50 % in patients with drug-resistant epilepsy [70]. Clinical symptoms are often different from the classic endogenous forms of depression, and this may cause some difficulty for diagnosis. The causal relationship between epilepsy and depression is not really clear. Many researchers have proposed that depression is a consequence or a correlate of the chronic illness, but it was shown that in some patients the affective disorder may appear before the onset of epilepsy. Moreover, in many cases, epileptic patients with depression present a family history for depression or other psychiatric disorders. As some abnormalities in the size and function of the amygdala are commonly observed in depression, similar anomalies might also be present in patients at risk of depression. In keeping with this, Richardson et al. [71] reported bilateral increases in amygdala volume for temporal epileptic patients with self-reported depressive symptoms.

A particular form of psychosis can also be associated with temporal lobe epilepsy. This has been recognized since the early 1950s, when the term psychosis of epilepsy (POE) was introduced to define a sample of psychiatric symptoms related to seizure disorder. However, POE can arise in different situations with different clinical characteristics. Psychotic symptoms can appear during a seizure (ictal), with a high prevalence of confusion and hallucination; or following seizures (postictal), with variable delays [72]. Finally, other psychotic signs can alternate with seizures (interictal), characterized by hallucinations, delusions, aggression, and disorganized behaviour. The relation to some dysfunction within the limbic system is still poorly known, but anomalies in both amygdala and prefrontal projections have long been suspected in schizophrenia [73] and may also play an important role in POE.

A few studies have evaluated the effect of surgical intervention on psychiatric disorders in epileptic patients. Devinsky et al. [74] tested a large sample of patients with temporal or extratemporal epilepsy before and after surgery, using self-reported and structural interview to evaluate various psychiatric disorders. The observed prevalence of depression was approximately 25% in their population before surgical intervention. At 3, 12, and 24 months of postoperative follow-up, there was a significant reduction of depression symptoms. Similarly, other longitudinal studies [75, 76] observed an improvement of depression after surgery in patients with temporal epilepsy who presented clinically relevant affective disorders before surgery. By contrast, other authors have noted the emergence of mood disturbances after surgery. Kanemoto et al. [77] tested a sample of patients before and after temporal lobectomy including amygdala and hippocampus. They observed that patients with a history of psychiatric disease before surgery also present a higher risk of manifesting new mood deficits after surgery, relative to those with no previous history of psychiatric disease. Future studies may usefully employ new neuroimaging measures, both prior and after surgery, in order to monitor changes in brain activity that may correlate or predict subsequent changes in mood states in these patients.

Conclusion

While the importance of medial temporal lobe structures has long been established for the hippocampus and memory function, the role of the amygdala and of its dense projections to widespread brain areas is still largely underappreciated in temporal lobe epilepsy. Damage to the amygdala may cause a wide range of deficits in the appraisal of emotional and social significance of sensory events, although these deficits are often variable and still poorly understood. These deficits may include the recognition of facial expressions, perception of gaze direction, attention, memory, musical emotions, theory of mind, as well as mood and other neuropsychiatric disorders. Some of these deficits might result from the loss of distant modulatory inputs from the amygdala on other intact regions, as can now be demonstrated by functional neuroimaging methods. We believe that a more systematic assessment of the rich repertoire of affective functions mediated by the amygdala might provide useful information about temporal lobe pathology and

neuropsychological outcome after surgery in TLE patients. In the future, new tests probing emotional and social processing should be highly desirable for clinical applications in these patients, to improve clinical management and to shed new lights on amygdala functions in humans.

References

1. *Jokeit H, Schacher M. Neuropsychological aspects of type of epilepsy and etiological factors in adults. Epilepsy Behav 2004; 5(Suppl 1): S14-20*
2. *Elger CE, Helmstaedter C, Kurthen M. Chronic epilepsy and cognition. Lancet neurology 2004; 3: 663-672*
3. *Van Hoesen GW. Anatomy of the medial temporal lobe. Magn Reson Imaging 1995; 13: 1047-1055*
4. *Cendes F, Leproux F, Melanson D et al. MRI of amygdala and hippocampus in temporal lobe epilepsy. Journal of computer assisted tomography 1993; 17: 206-210*
5. *Phelps EA, LeDoux JE. Contributions of the amygdala to emotion processing: from animal models to human behavior. Neuron 2005; 48: 175-187*
6. *Cendes F, Andermann F, Gloor P et al. Relationship between atrophy of the amygdala and ictal fear in temporal lobe epilepsy. Brain 1994; 117: 739-746*
7. *Lanteaume L, Khalfa S, Regis J et al. Emotion induction after direct intracerebral stimulations of human amygdala. Cereb Cortex 2006; doi: 10.1093/cercor/bhl041*
8. *Klüver H, Bucy PC. Preliminary analysis of functions of the temporal lobes in monkeys. Archives of Neurology and Psychiatry 1939; 42: 979-1000*
9. *Weiskrantz L. Behavioral changes associated with ablation of the amygdaloid complex in monkeys. J Comp Physiol Psychol 1956; 49: 381-391*
10. *Horel JA, Keating EG. Recovery from a partial Kluver-Bucy syndrome in the monkey produced by disconnection. J Comp Physiol Psychol 1972; 79: 105-114*
11. *Aggleton JP, Passingham RE. Syndrome produced by lesions of the amygdala in monkeys (Macaca mulatta). J Comp Physiol Psychol 1981; 95: 961-977*
12. *Kling AS, Tachiki K, Lloyd R. Neurochemical correlates of the Kluver-Bucy syndrome by in vivo microdialysis in monkey. Behav Brain Res 1993; 56: 161-170*
13. *Meunier M, Hadfield W, Bachevalier J, Murray EA. Effects of rhinal cortex lesions combined with hippocampectomy on visual recognition memory in rhesus monkeys. J Neurophysiol 1996; 75: 1190-1205*
14. *Marlowe WB, Mancall EL, Thomas JJ. Complete Kluver-Bucy syndrome in man. Cortex 1975; 11: 53-59*
15. *Kapur N, Barker S, Burrows EH et al. Herpes simplex encephalitis: long term magnetic resonance imaging and neuropsychological profile. J Neurol Neurosurg Psychiatry 1994; 57: 1334-1342*
16. *Adolphs R. Social cognition and the human brain. Trends Cogn Sci 1999; 3: 469-479*
17. *LeDoux JE. Emotion circuits in the brain. Annu Rev Neurosci 2000; 23: 155-184*
18. *Baas D, Aleman A, Kahn RS. Lateralization of amygdala activation: a systematic review of functional neuroimaging studies. Brain Res Brain Res Rev 2004; 45: 96-103*
19. *Cahill L, Uncapher M, Kilpatrick L et al. Sex-related hemispheric lateralization of amygdala function in emotionally influenced memory: an FMRI investigation. Learn Mem 2004; 11: 261-266*
20. *Pitkanen A, Savander V, LeDoux JE. Organization of intra-amygdaloid circuitries in the rat: an emerging framework for understanding functions of the amygdala. Trends Neurosci 1997; 20: 517-523*
21. *Amaral DG. The primate amygdala and the neurobiology of social behavior: implications for understanding social anxiety. Biol Psychiatry 2002; 51: 11-17*
22. *Amaral DG, Behniea H, Kelly JL. Topographic organization of projections from the amygdala to the visual cortex in the macaque monkey. Neuroscience 2003; 118: 1099-1120*
23. *Phillips RG, LeDoux JE. Differential contribution of amygdala and hippocampus to cued and contextual fear conditioning. Behav Neurosci 1992; 106: 274-285*
24. *Quirk GJ, Beer JS. Prefrontal involvement in the regulation of emotion: convergence of rat and human studies. Curr Opin Neurobiol 2006; 16: 723-727*
25. *Morris JS, Buchel C, Dolan RJ. Parallel neural responses in amygdala subregions and sensory cortex during implicit fear conditioning. Neuroimage 2001; 13: 1044-1052*
26. *Ball T, Rahm B, Eickhoff SB et al. Response properties of human amygdala subregions: evidence based on functional MRI combined with probabilistic anatomical maps. PLoS ONE 2007; 2: e307 doi 10.1371/journal.pone.0000307*
27. *Adolphs R. Neural systems for recognizing emotion. Curr Opin Neurobiol 2002; 12: 169-177*
28. *Vuilleumier P, Armony J, Dolan R. Reciprocal links between emotion and attenton. In: Frackowiak R et al. (eds): Human Brain Function, 2nd ed. San Diego: Academic Press, 2003: 419-444*
29. *Adolphs R, Tranel D, Damasio H, Damasio A. Impaired recognition of emotion in facial expressions following bilateral damage to the human amygdala. Nature 1994; 372: 669-672*
30. *Fowler HL, Baker GA, Tipples J et al. Recognition of emotion with temporal lobe epilepsy and asymmetrical amygdala damage. Epilepsy Behav 2006; 9: 164-172*
31. *Meletti S, Benuzzi F, Rubboli G et al. Impaired facial emotion recognition in early-onset right mesial temporal lobe epilepsy. Neurology 2003; 60: 426-431*
32. *Anderson AK, Phelps EA. Expression without recognition: contributions of the human amygdala to emotional communication. Psychol Sci 2000; 11: 106-111*
33. *LaBar KS, LeDoux JE, Spencer DD, Phelps EA. Impaired fear conditioning following unilateral temporal lobectomy in humans. J Neurosci 1995; 15: 6846-6855*
34. *Brierley B, Medford N, Shaw P, David AS. Emotional memory and perception in temporal lobectomy patients with amygdala damage. Journal of neurology, neurosurgery, and psychiatry 2004; 75: 593-599*
35. *Siebert M, Markowitsch HJ, Bartel P. Amygdala, affect and cognition: evidence from 10 patients with Urbach-Wiethe disease. Brain 2003; 126: 2627-2637*
36. *Anderson AK, Phelps EA. Is the human amygdala critical for the subjective experience of emotion? Evidence of intact dispositional affect in patients with amygdala lesions. Journal of cognitive neuroscience 2002; 14: 709-720*
37. *Tranel D, Gullickson G, Koch M, Adolphs R. Altered experience of emotion following bilateral amygdala damage. Cognitive neuropsychiatry 2006; 11: 219-232*
38. *Fox E, Damjanovic L. The eyes are sufficient to produce a threat superiority effect. Emotion 2006; 6: 534-539*
39. *Adams RB, Jr., Kleck RE. Perceived gaze direction and the processing of*

facial displays of emotion. Psychol Sci 2003; 14: 644-647

40. *Scherem KR, Schorr A, Johnstone T. Appraisal processes in emotion: Theory, methods, research. New York: Oxford University Press, 2001*
41. *Sato W, Yoshikawa S, Kochiyama T, Matsumura M. The amygdala processes the emotional significance of facial expressions: an fMRI investigation using the interaction between expression and face direction. Neuroimage 2004; 22: 1006-1013*
42. *Adams RB, Jr., Gordon HL, Baird AA et al. Effects of gaze on amygdala sensitivity to anger and fear faces. Science 2003; 300: 1536*
43. *Kawashima R, Sugiura M, Kato T et al. The human amygdala plays an important role in gaze monitoring: a PET study. Brain 1999; 122: 779-783*
44. *George N, Driver J, Dolan RJ. Seen gaze-direction modulates fusiform activity and its coupling with other brain areas during face processing. Neuroimage 2001; 13: 1102-1112*
45. *Young AW, Aggleton JP, Hellawell DJ et al. Face processing impairments after amygdalotomy. Brain 1995; 118 (Pt 1): 15-24*
46. *Friesen CK, Kingstone A. The eyes have it! Reflexive orienting is triggered by nonpredictive gaze. Psychonomic bulletin & review 1998;5:490-495*
47. *Vuilleumier P. Perceived gaze direction in faces and spatial attention: a study in patients with parietal damage and unilateral neglect. Neuropsychologia 2002; 40: 1013-1026*
48. *Vuilleumier P, Armony JL, Driver J, Dolan RJ. Effects of attention and emotion on face processing in the human brain: an event-related fMRI study. Neuron 2001; 30: 829-841*
49. *Sabatinelli D, Bradley MM, Fitzsimmons JR, Lang PJ. Parallel amygdala and inferotemporal activation reflect emotional intensity and fear relevance. Neuroimage 2005; 24: 1265-1270*
50. *Vuilleumier P. How brains beware: neural mechanisms of emotional attention. Trends Cogn Sci 2005; 9: 585-594*
51. *Vuilleumier P, Richardson MP, Armony JL et al. Distant influences of amygdala lesion on visual cortical activation during emotional face processing. Nat Neurosci 2004; 7: 1271-1278*
52. *Seminowicz DA, Mayberg HS, McIntosh AR et al. Limbic-frontal circuitry in major depression: a path modeling metanalysis. Neuroimage 2004; 22: 409-418*
53. *Allison T, Puce A, McCarthy G. Social perception from visual cues: role of the STS region. Trends Cogn Sci 2000; 4: 267-278*
54. *Adolphs R, Damasio H, Tranel D, Damasio AR. Cortical systems for the recognition of emotion in facial expressions. J Neurosci 1996; 16: 7678-7687*
55. *Grandjean D, Sander D, Pourtois G et al. The voices of wrath: brain responses to angry prosody in meaningless speech. Nat Neurosci 2005; 8: 145-146*
56. *Anderson AK, Phelps EA. Lesions of the human amygdala impair enhanced perception of emotionally salient events. Nature 2001; 411: 305-309*
57. *Edith Frank J, Tomaz C. Lateralized impairment of the emotional enhancement of verbal memory in patients with amygdala-hippocampus lesion. Brain and cognition 2003; 52: 223-230*
58. *Adolphs R, Tranel D, Buchanan TW. Amygdala damage impairs emotional memory for gist but not details of complex stimuli. Nature neuroscience 2005; 8: 512-518*
59. *Phelps EA, LaBar KS, Spencer DD. Memory for emotional words following unilateral temporal lobectomy. Brain and cognition 1997; 35: 85-109*
60. *Gosselin N, Peretz I, Noulhiane M et al. Impaired recognition of scary music following unilateral temporal lobe excision. Brain 2005; 128: 628-640*
61. *Adolphs R, Tranel D, Damasio H, Damasio AR. Fear and the human amygdala. J Neurosci 1995; 15: 5879-5891*
62. *Gosselin N, Peretz I, Johnsen E, Adolphs R. Amygdala damage impairs emotion recognition from music. Neuropsychologia 2007; 45: 236-244*
63. *Baron-Cohen S, Ring HA, Bullmore ET et al. The amygdala theory of autism. Neuroscience and biobehavioral reviews 2000; 24: 355-364*
64. *Baron-Cohen S, Leslie AM, Frith U. Does the autistic child have a "theory of mind"? Cognition 1985; 21: 37-46*
65. *Shaw P, Lawrence EJ, Radbourne C et al. The impact of early and late damage to the human amygdala on 'theory of mind' reasoning. Brain 2004; 127: 1535-1548*
66. *Stone VE, Baron-Cohen S, Calder A et al. Acquired theory of mind impairments in individuals with bilateral amygdala lesions. Neuropsychologia 2003; 41: 209-220*
67. *Baron-Cohen S, Jolliffe T, Mortimore C, Robertson M. Another advanced test of theory of mind: evidence from very high functioning adults with autism or asperger syndrome. Journal of child psychology and psychiatry, and allied disciplines 1997; 38: 813-822*
68. *Schacher M, Winkler R, Grunwald T et al. Mesial temporal lobe epilepsy impairs advanced social cognition. Epilepsia 2006; 47: 2141-2146*
69. *Devinsky O. Psychiatric comorbidity in patients with epilepsy: implications for diagnosis and treatment. Epilepsy Behav 2003; 4(Suppl 4): S2-10*
70. *Schmitz B. Depression and mania in patients with epilepsy. Epilepsia 2005; 46(Suppl 4): 45-49*
71. *Richardson EJ, Griffith HR, Martin RC et al. Structural and functional neuroimaging correlates of depression in temporal lobe epilepsy. Epilepsy Behav 2007*
72. *Kanemoto K, Kawasaki J, Kawai I. Postictal psychosis: a comparison with acute interictal and chronic psychoses. Epilepsia 1996; 37: 551-556*
73. *Aleman A, Kahn RS. Strange feelings: do amygdala abnormalities dysregulate the emotional brain in schizophrenia? Prog Neurobiol 2005; 77: 283-298*
74. *Devinsky O, Barr WB, Vickrey BG et al. Changes in depression and anxiety after resective surgery for epilepsy. Neurology 2005; 65: 1744-1749*
75. *Pintor L, Bailles E, Fernandez-Egea E et al. Psychiatric disorders in temporal lobe epilepsy patients over the first year after surgical treatment. Seizure 2007; 16: 218-225*
76. *Inoue Y, Mihara T. Psychiatric disorders before and after surgery for epilepsy. Epilepsia 2001; 42(Suppl 6): 13-18*
77. *Kanemoto K, Kawasaki J, Mori E. Postictal psychosis as a risk factor for mood disorders after temporal lobe surgery. Journal of neurology, neurosurgery, and psychiatry 1998; 65: 587-589*

Address for correspondence:
Dr. Chiara Cristinzio
Lab NIC, Dept of Neurosciences & Clinic of Neurology
Centre Médical Universitaire (CMU)
1 rue Michel Servet
CH 1211 Geneva
Tel. 0041 22 3795 382
Fax 0041 22 3795 402
chiara.cristinzio@pse.unige.ch or

Clinical Neuroimaging in Epileptic Patients with Autoscopic Hallucinations and Out-of-Body Experiences

Olaf Blanke [1,2] and V Castillo[2]
[1]Laboratory of Cognitive Neuroscience, Brain Mind Institute, Ecole Polytechnique Fédérale de Lausanne (Swiss Federal Institute of Technology), Lausanne
[2]Department of Neurology, University Hospital, Geneva

Summary

Autoscopic phenomena are complex illusory perceptions of one's body during which human subjects experience a second own body or double in their environment. Although doubles may also be felt or heard autoscopic phenomena most commonly refer to visual doubles, and consist of autoscopic hallucinations, out-of-body experiences, and heautoscopy.

Recently, many neurological reports have focussed on only one type of autoscopic phenomena: out-of-body experiences. Here we review neurological data on autoscopic hallucinations and present a case during complex partial seizures due to neurocysticercosis.

Epileptologie 2007; 24: 90 – 95

Key words: Neurology, self, body, neuroimaging, epilepsy

Klinische Bildgebungsverfahren bei Epilepsiepatienten mit autoskopischen Halluzinationen und ausserkörperlichen Erfahrungen

Autoskopische Erfahrungen sind komplexe Illusionen, die den eigenen Körper betreffen und sich durch die Wahrnehmung eines zweiten eigenen Körpers oder Doppelgängers, der im extrapersonalen Raum wahrgenommen wird, definieren. Autoskopische Erfahrungen beziehen sich meistens auf visuelle Doppelgänger, obwohl der Doppelgänger auch nur gefühlt oder gehört werden kann. Es gibt drei unterschiedliche Formen von visuellen autoskopischen Erfahrungen: autoskopische Halluzinationen, ausserkörperliche Erfahrungen und Heautoskopie. In der letzten Zeit sind einige detaillierte neurologische Berichte über Patienten mit ausserkörperlichen Erfahrungen veröffentlicht worden. Hier stellen wir deshalb eine Übersicht über neurologische Patienten mit autoskopischen Halluzinationen vor, sowie die detaillierte Beschreibung einer Patientin, die unter autoskopischen Halluzinationen aufgrund komplex-partieller epileptischer Anfälle bei Neurozystizerkose litt.

Schlüsselwörter: Neurologie, Selbst, Körper, Bildgebung, Epilepsie

Les techniques de l'imagerie clinique pour les patients épileptiques avec hallucinations autoscopiques et expériences extracorporelles

Les expériences autoscopiques sont des illusions complexes qui concernent le propre corps d'une personne et qui se définissent par la perception d'un deuxième corps propre ou d'un double qui est ressenti dans l'espace extrapersonnel. Les expériences autoscopiques se rapportent généralement à des doubles visuels, mais ce double peut aussi être seulement ressenti ou entendu. Il existe trois formes distinctes d'expériences visuelles autoscopiques : les hallucinations autoscopiques, les expériences extracorporelles et l'héautoscopie. Quelques rapports neurologiques détaillés sur des personnes ayant connu des expériences extracorporelles ont été publiés ces derniers temps. C'est pourquoi nous présentons ici une synopsis de patients neurologiques avec des hallucinations autoscopiques, ainsi que la description détaillée d'une patiente qui souffrait d'hallucinations autoscopiques lors de crises complexes partielles associées à une neurocysticercose.

Mots-clés : Neurologie, perception du soi, corps, imagerie, épilepsie

Introduction

Autoscopic phenomena are complex illusory perceptions of one's body during which human subjects experience a second own body or double in their environment. Autoscopic phenomena most commonly refer to visual doubles [1], although doubles may also be felt or heard [2 - 4]. Autoscopic phenomena and doubles have fascinated mankind from time immemorial. Three main visual forms of autoscopic phenomena have been described that can be separated based on phenomenological and anatomical criteria [5]: out-of-body experience, autoscopic hallucination, and heautoscopy [6, 7, 1]. During an out-of-body experience people feel

that their "self", or center of awareness, is located outside of the physical body and somewhat elevated. It is from this elevated extracorporal location that the subjects experience seeing their body and the world [8, 7, 1]. The subjects' reported perceptions are organized in such a way as to be consistent with this elevated visuo-spatial perspective. The following example from Lunn

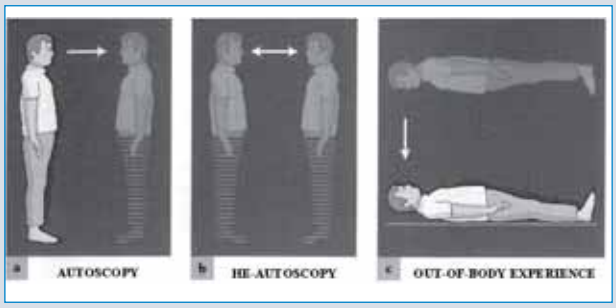

Figure 1: Phenomenology of autoscopic phenomena. In this figure the phenomenology of autoscopic hallucinations (left), heautoscopy (middle) and out-of-body experiences (right) is represented schematically. The experienced position and posture of the patient is indicated by a full body and the hallucinated position of the "disembodied" body (OBE) or double's body (AH, HAS) as a transparent body. The finding that autoscopic hallucinations and heautoscopy were mainly reported from a sitting/standing position and out-of-body experiences in a supine position is integrated into the figure. The experienced visuo-spatial perspective during the autoscopic phenomenon is indicated by the arrow pointing away from the location in space from which the patient has the impression to see from (autoscopic hallucination: from the physical body; out-of-body experiences: from a disembodied body or location; heautoscopy: alternating or simultaneous fashion between physical and autoscopic body; modified from Blanke [1].

([9], case 1) illustrates what individuals commonly experience during an out-of-body experience: "Suddenly it was as if he saw himself in the bed in front of him [...] as if he were floating in space below the ceiling in the corner facing the bed from where he could observe his own body in the bed. [. . .] he saw his own completely immobile body in the bed." An out-of-body experience can thus be defined as the presence of the following three phenomenological elements: the feeling of being outside one's physical body (disembodiment); the presence of a distanced and elevated visuo-spatial perspective; and the seeing of one's own body (autoscopy) from this elevated perspective. These three aspects are shown graphically in **Figure 1**.

During an autoscopic hallucination people experience seeing a double of themselves in extrapersonal space without the experience of leaving one's body (no disembodiment). As compared to out-of-body experiences, individuals with autoscopic hallucination experience to see the world from their habitual visuo-spatial perspective and experience their "self", or center of awareness inside their physical body **(Figure 1)**. The following example of an autoscopic hallucination is taken from Kölmel ([10], case 6). "[. . .] the patient suddenly noticed a seated figure on the left. "It wasn't hard to realize that it was I myself who was sitting there. I looked younger and fresher than I do now. My double smiled at me in a friendly way". The third form of autoscopic phenomena is heautoscopy, which is an intermediate form between autoscopic hallucination and out-of-body experience. These individuals also have the experience of seeing a double of themselves in extrapersonal space. However, it is difficult for the subject to decide whether he is disembodied or not and whether the self is localized within the physical body or in the illusory body that is seen [1]. In addition, the subjects often report to see, in an alternating or simultaneous fashion, from different visuo-spatial perspectives (physical body, double's body) as reported by patient 2B in Blanke et al. ([1], see **Figure 1**). "[The patient] has the immediate impression as if she were seeing herself from behind herself. She felt as if she were "standing at the foot of my bed and looking down at myself." Yet, [. . .], the patient also has the impression to "see" from her physical [or bodily] visuo-spatial perspective, which looked at the wall immediately in front of her. Asked at which of these two positions she thinks herself to be, she answered that "I am at both positions at the same time".

With respect to their etiology, autoscopic phenomena have been reported in various generalized and focal diseases of the central nervous system. Generalized neurological etiologies include cerebral infections such as meningitis and encephalitis, intoxications, as well as generalized epilepsies [1]. Autoscopic phenomena following focal brain damage also emerge from a large variety of etiologies including most often focal epilepsy [8], traumatic brain damage [11], and migraine [12], vascular brain damage [10], neoplasia [11], dysembryoblastic neuroepithelial tumor [1] and arteriovenous malformation [8]. Regarding their underlying anatomy, autoscopic phenomena of focal origin primarily implicate posterior brain regions and with respect to lobar anatomy most studies found the temporal, parietal, or occipital lobe to be involved [13, 11, 9, 8, 1]. Some of these authors have either suggested a predominance of temporal lobe involvement [8, 6], a predominance of parietal lobe involvement [14, 13], or no brain localization at all [15]. Menninger-Lerchenthal [14] speculated on different anatomical substrates for the different autoscopic phenomena, suggesting that autoscopic hallucinations originate at the junction of the parietal and occipital lobe (junction of Brodmann's areas 39, 40, and 19), heautoscopy from the angular and supramarginal gyrus (Brodmann's areas 40 and 41), and out-of-body experiences from the superior parietal lobule (Brodmann's area 7). These anatomical dissociations have been partly confirmed by Blanke et al. [1] showing that autoscopic phenomena might be related to damage to the temporo-parietal junction although no

lesion analysis was carried out for each of the three forms of autoscopic phenomena. With regard to predominant hemispheric involvement the reported data are quite divergent as well. Some authors found no hemispheric predominance for autoscopic phenomena [13, 8, 16], while others have suggested a right hemispheric predominance for autoscopic phenomena [14, 6, 5]. Despite the description of over 100 cases in the neurological literature [17] and despite their relevance to neurological and neurobiological models of self and self consciousness [18] only few cases with sufficient clinical detail have been reported. Only more recently, autoscopic phenomena have received greater interest from neurologists [8, 2, 5, 7, 19, 1, 17]. This is surprising when looking at the large number of studies investigating illusory own body perceptions that are restricted to certain body parts such as phantom limbs [20, 21]. In addition, these studies on phantom limbs have led to the neuroscientific investigation and description of some of the underlying neurocognitive mechanisms for illusory own body perceptions enhancing not only our understanding of phantom limbs, but also improving our models of corporeal awareness, bodily processing and self consciousness for the affected body parts [21, 20, 22]. This is not yet the case for autoscopic phenomena and detailed knowledge about their underlying neurological mechanisms remains sparse, especially as recent research has largely focussed on the neurology of out-of-body experiences. Here, we present the case of a patient who suffered from autoscopic hallucinations during complex partial seizures due to neurocysticercosis. We will discuss our findings especially with respect to the etiology, neuroanatomy and associated neurological symptoms of autoscopic hallucinations. These findings will also be discussed and compared to the neurology of out-of-body experiences as well as figural visual hallucinations and experiential phenomena that may be difficult to distinguish from autoscopic hallucinations.

Case report

This 27 year-old female, right handed, patient, citizen of Cap Verde, was admitted to the hospital for complex partial seizures with secondary generalization. Complex partial seizures were diagnosed 4 years ago and the patient had been seizure free under anti-epileptic treatment (phenobarbital 100 mg daily). Due to irregular medication during her vacation in Geneva (Mai/June 2003) she presented several complex partial seizures (see description below) that were twice followed by secondary generalization. The neurological examination during the post-ictal period at the emergency room revealed only somnolence and preserved oral comprehension and expression and simple task execution without any focal deficits. Follow-up examinations were also normal including general physical and neurological examination, haematological examination, blood chemical analyses, and screening of the serum for toxic substances. Blood analysis did not reveal eosinophilia. Radiographs of the chest were also normal. Lumbar puncture was performed and analysis of the cerebro-spinal fluid was normal. Magnetic resonance imaging (MRI) of the brain demonstrated bilateral multiple small parenchymal cystic lesions compatible of neurocysticercosis. Stages of cysts were variable and included all stages from vesicular cysts (with scolex), to colloidal cysts and nodules [23]. Lesions were generally hypointense in T1 and hyperintense in T2. Many cysts were enhanced by Gadolinium. All lesions had a diameter < 1 cm. Cysts were also found at the subcortical level (thalamus and central grey matter) as well as the corpus callosum. A CT scan revealed several degenerated, calcified cysts. There were a large number of cysts in right mesial occipital cortex **(Figure 2C)** extending to right mesial occipito-parietal cortex. These occipital and occipito-parietal cysts were surrounded by a prominent perilesional edema suggestive of active cysts. Standard EEG was normal. Complex partial seizures due to neurocysticercosis were diagnosed based on neuroradiological findings and treatment with Prazyquantel and corticoid therapy (15 mg/d for 20 days) initiated. Phenobarbital (100 mg/d) was restarted as an anti-epileptic treatment as the patient planned to return to Cap Verde where no other medications were easily accessible. A search for systemic cysticerci in blood and cerebrospinal fluid (western blot) was negative. We followed the patient for six months. No further seizures were noted in this period. For about 1 year prior to the investigations reported here the patient suffered from the following visual hallucinations. In the central visual field or in the right parafoveal region she sees bright and colored lights consisting of many little stars that flickered (~1-2 Hz) within a circle of ~20 cm diameter at a distance of 2 meters. There were many different colors, but mainly yellow. These visual hallucinations were replaced progressively by a small image of herself that she saw in the central visual field, superimposed on the bright lights. The image was described as two-dimensional, showing her entire body in front-view. The image was fully dressed wearing the clothes that the patient was wearing at the moment. The image was not blurred, quite detailed and not transparent. The image did not move and the face was always motionless and expressionless (eyes and mouth were closed). This occurred with a frequency between 1x/week to 1x/month over the last year. The duration of these autoscopic hallucinations was variable and could last from several seconds up to ~2 minutes. The image did not speak nor were there any auditory hallucinations. There was no sensation of disembodiment, change in visuo-spatial perspective, or affinity with the autoscopic image (as is the case in out-of-body experiences and heautoscopy). There were no associated vestibular hallucinations of falling, flying,

elevation, rotation (but she mentioned the feeling as if she were falling towards the right without actually having fallen down). The patient did not notice any other illusory own body perceptions. She did not notice any mirror reversal between her body and the image nor any shared movements between her body and the image (as described by Zamboni et al. [24]. During the first occurrences of these visual manifestations she was afraid, but anxiety vanished during later autoscopic hallucinations.

Discussion

Based on the clinical symptoms and history as well as the results of the neuroradiological examinations we argue that the present patient suffered from autoscopic hallucinations due to complex partial seizures due to neurocysticercosis. To the best of our knowledge no previous case of autoscopic hallucinations due to neurocysticercosis has been reported although neurocysticercosis, caused by the infection of the central nervous system by the larval stage of the tape-worm Taenia solium, is the most common parasitic disease of the human central nervous system and is worldwide the most common cause of symptomatic epilepsy [23, 25]. Complex partial seizures leading to autoscopic hallucinations disappeared under anti-parasitic and anti-epileptic treatment. As epileptic seizures are the most frequent cause of autoscopic hallucinations [17], we suggest that autoscopic hallucinations might actually be quite common in regions with endemic neurocysticercosis especially if epileptogenic cysts are localized in occipital or occipito-parietal cortex as in the present patient. Autoscopic hallucinations are generally described as pseudo-hallucinations and patients report seeing a static image of their body in the central visual field without disembodiment or changes in their visuo-spatial perspective. Further classical findings about the seen double were present in our case. The double was seen in front-view, expressionless [26, 1 (case 6), 24], and was performing no actions or movements ([26, 1 (case 6)]; for exceptions see Zambioni et al. [24] and Bhaskaran et al. [27]). There also was no affinity or thought communication between patient and hallucinated double and this was also absent in all previous cases of autoscopic hallucinations [17]. The present observation is corroborating very early case descriptions of autoscopic hallucinations that have been called visual or "specular" hallucinations ([28, 29]; see also Brugger et al. [2], Blanke and Mohr [17] as well as 7 more recent case reports in whom CT or MRI data were available [10, 27, 1, 26, 24]). In these latter cases, the double was localized either in the central visual field [1 (case 6), 24] or in the contralesional visual field [10, 27, 26], associated with lateralized or central elementary visual hallucinations. These data suggest that autoscopic hallucinations in our patient were due to interference with visual mechanisms in occipital cortex. Accordingly, no vestibular hallucinations of falling, flying, elevation, or of rotation were mentioned by our patient as well as no auditory hallucinations or body schema disturbances. This is compatible with previous reports and allows to distinguish autoscopic hallucinations from out-of-body experiences of neurological origin who are frequently associated with all latter three symptoms [17]. Although we could not objectify heminanopia or visual field loss in the present case, we speculate that a more fine-grained quantitative visual field analysis, especially in the ictal or postictal phase, might have revealed such a deficit [2]. As in the present case, autoscopic hallucinations are almost never associated with sensori-motor deficits [17] allowing to exclude interference with more anterior structures in fronto-parietal cortex (especially as many neurocysticercosis lesions were also found in this region in the present patient). Presence of elementary visual hallucinations and an occipital origin in autoscopic hallucinations was also found by Blanke and Mohr [17] who analyzed 20 neurological cases with autoscopic hallucinations due to focal brain damage (occipital involvement was found in 60% of cases with autoscopic hallucinations, but only in 20% of cases with out-of-body experiences). In the 7 aforementioned cases of autoscopic hallucinations that were confirmed by CT

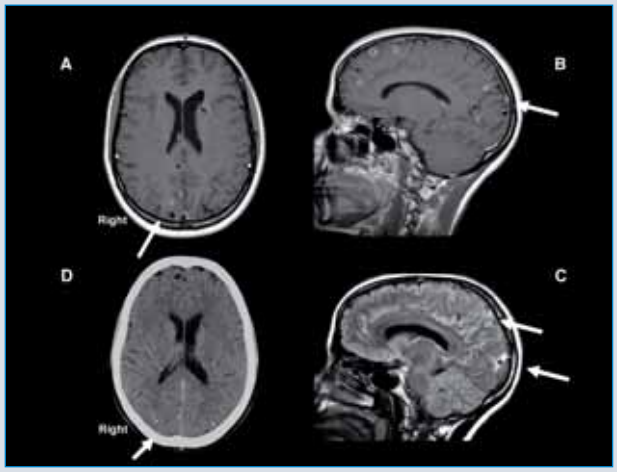

Figure 2: Neurocysticercosis. Multiple small parenchymal cystic lesions compatible of neurocysticercosis are shown. Stages of cysts were variable and included all stages from vesicular cysts (with scolex), to colloidal cysts and nodules (Figures 2A, B). A CT scan showed several calcified cysts ((Figure 2D). There were a large number of cysts in right mesial occipital cortex extending to right mesial occipito-parietal cortex (Figures 2B, C). These occipital and occipito-parietal cysts were surrounded by a prominent perilesional edema (Figure 2C) suggestive of active cysts.

and MRI [10 (case 6), 27, 1 (case 6), 26 (cases 1,2,3), 24], occipital lobe involvement was found in all cases **(Figures 3A-G)**, parietal lobe involvement in 71% and temporal only in 14% pointing to interference with occi-

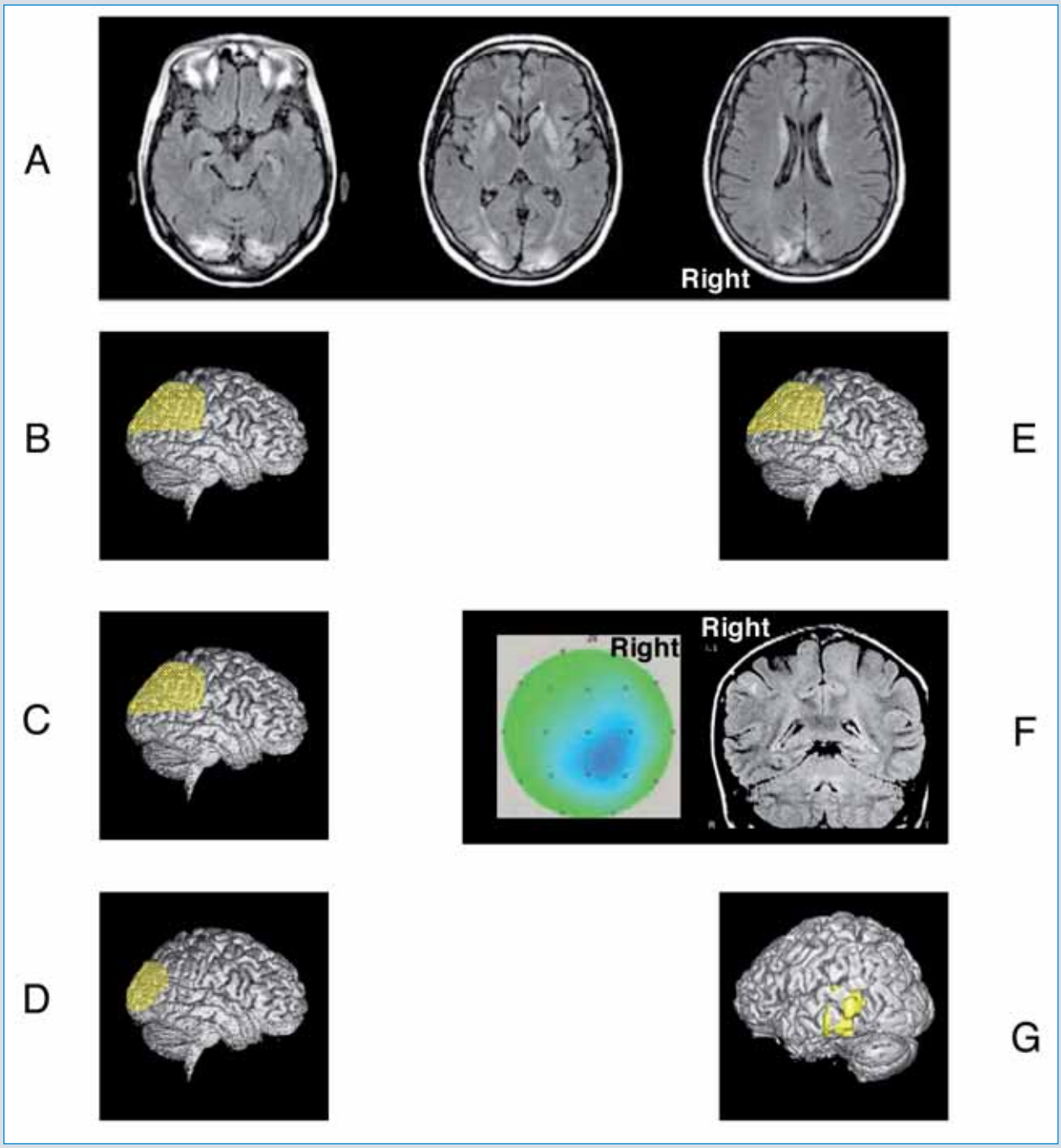

Figure 3: Lesion location in 7 previous cases with autoscopic hallucinations. Figure 3A shows a MRI-defined bi-occipital lesion extending to the right parieto-occipital cortex as reported by Zamboni et al. [24], reproduced with permission. Lesion location (indicated in yellow) of patients described by Maillard et al. [26] (case 2, Figure 3B), Maillard et al. [26] (case 3, Figure 3C), Bhaskaran et al. [27] (Figure 3D), and Kölmel et al. [10] (Figure 3E) is estimated on a lateral cortical view for all patients. Note the predominance of parieto-occipital and occipital lesions. The MRI-defined right temporoparieto-occipital lesion reported by Maillard et al. [26] (case 1, Figure 3F) is shown with topographic distribution of interictal epileptic activity over the right parieto-occipital region. Figure 3G shows lesion location of the patient reported by Blanke et al. [1] (case 6) in temporo-occipital cortex.

pito-parietal mechanisms in autoscopic hallucinations **(Figure 4A)**. The occipital and parieto-occipital origin in the present patient was confirmed by MRI and CT revealing large and active lesions in this region **(Figure 2)**. Moreover, this parieto-occipital lesion location in autoscopic hallucinations is distinct from that observed in out-of-body experiences that have been linked to right temporo-parietal cortex **(Figure 4B)**. The fact that most previous studies have analyzed the lesion location for all three forms of autoscopic phenomena together (including cases with heautoscopy) might thus explain why some authors reported no lobar or hemispheric

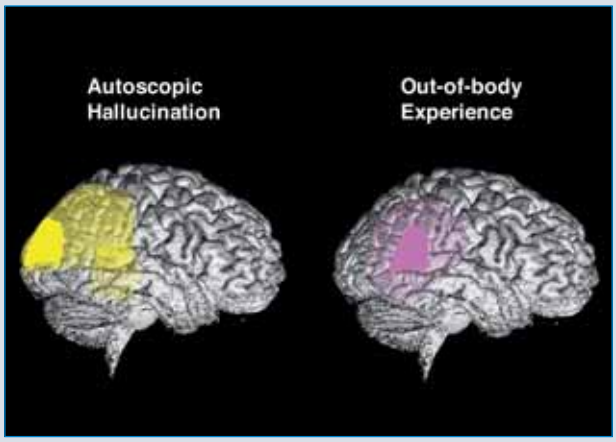

Figure 4: Mean lesion location in cases with autoscopic hallucinations and out-of-body experiences. The lesions of the seven patients of figure 3 and the present patient with autoscopic hallucinations (light yellow) have been drawn onto the same lateral brain showing that lesion overlap (dark yellow area) centers in parieto-occipital cortex. The same approach for patients with out-of-body experiences (see Blanke and Mohr, [17]) revealed the center of lesion overlap at the temporo-parietal junction (pink area) with maximal lesion overlap at the dark pink area.

predominance [16, 8, 13]. That patients with autoscopic hallucinations have significantly more often involvement of the occipital lobe is also concordant with the association with visual hallucinations and hemianopia and the frequently observed bright coloring of the double that contrasted with the colorless, pale, and misty appearance of the double in heautoscopy or out-of-body experiences [5].

Autoscopic hallucinations need to be distinguished from experiential phenomena and figural hallucinations. Experiential phenomena are defined as dreamlike scenic hallucinations that combine elements of complex visual and/or auditory perception and memory [30 - 33]. During experiential phenomena patients experience to see or hear a complex scene with many different objects and persons often related to previous life events [30, 33] and caused by epileptic discharge or electrical stimulation of the lateral temporal cortex and/or medial temporal structures. Figural hallucinations refer to non-scenic visual hallucinations of single or multiple people, not including the own body, and have been described after damage to extrastriate temporo-occipital cortex. In conclusion, patients suffering from autoscopic hallucinations typically experience to see a static and expressionless image of themselves without any sensation of disembodiment or altered visuo-spatial perspective. This image is localized either in the central visual field or lateralized to the side of visual field deficits and associated with bright and colourful elementary visual hallucinations due to damage to occipital or parieto-occipital cortex. Recently reported neurological cases of autoscopic hallucinations were due to epilepsy, stroke, hematoma, and tumor. Autoscopic hallucinations are easily distinguishable from out-of-body experiences during which an image of one's body is seen in the central visual field, but associated with a strong sensation of disembodiment and from an elevated, non-body centered visuo-spatial perspective. Moreover, patients with out-of-body experiences do not suffer from visual, but frequent vestibular hallucinations of flying, floating, and falling and are due to damage in right temporo-parietal cortex due to similar neurological etiologies.

References

1. *Blanke O, Landis T, Spinelli L, Seeck M. Out-of-body experience and autocopy of neurological origin. Brain 2004; 127: 243-258*
2. *Brugger P, Regard M, Landis T. Unilaterally felt « presences »: The neuropsychiatry of one's invisible Doppelgänger. Neuropsychiatr Neuropsychol Beh Neurol 1996; 9: 114-122*
3. *Blanke O, Ortigue S, Coeytaux A et al. Hearing of a presence. NeuroCase 2003; 9: 329-339*
4. *Arzy S, Seeck M, Ortigue S et al. Induction of an illusory shadow person. Nature 2006; 443: 287*
5. *Brugger P, Regard M, Landis T. Illusory reduplication of one's own body: phenomenology and classification of autoscopic phenomena. Cogn Neuropsychiatr 1997; 2: 19-38*
6. *Grüsser OJ, Landis T. The splitting of "I" and "me": heautoscopy and related phenomena. In: Cronly-Dillon JR (ed) : Visual Agnosias and Other Disturbances of Visual Perception and Cognition. Amsterdam: MacMillan, 1991: 297-303*
7. *Brugger P. Reflective mirrors: perspective taking in autoscopic phenomena. Cogn Neuropsychiatr 2002; 7: 179-194*
8. *Devinsky O, Feldmann E, Burrowes K, Bromfield E. Autoscopic phenomena with seizures. Archives Neurology 1989; 46: 1080-1088*
9. *Lunn V. Autoscopic phenomena. Acta Psychiatrica Scandinavia 1970; 46(Suppl 219): 118-125*
10. *Kölmel HW. Complex visual hallucinations in the hemianopic field. J Neurol Neurosurg Psychiatry 1985: 48: 29-38*
11. *Todd J, Dewhurst K. The double: its psycho-pathology and psychophysiology. J Nerv Ment Dis 1955; 122: 47-55*
12. *Lippman CW. Hallucination of physical duality in migraine. J Nerv Ment Dis 1953; 117: 345-350*
13. *Hécaen H, Ajuriaguerra J. L'Héautoscopie. En: Méconnaissances et hallucinations corporelles. Paris: Masson, 1952: 310-343*
14. *Menninger-Lerchenthal E. Das Truggebilde der eigenen Gestalt. Berlin: Karger, 1935*
15. *Lhermitte J. Les phenomènes héautoscopiques, les hallucinations spéculaires et autoscopiques. En : L'image de notre corps. Paris: L'Harmattan, 1939: 170-227*
16. *Dening TR, Berrios GE. Autoscopic phenomena. Brit J Psychiatr 1994; 165: 808-817*
17. *Blanke O, Mohr C. Out-of-body experience, heautoscopy, and autoscopic hallucinations of neurological origin. Implications for neurocognitive mechanisms of corporeal awareness and self-consciousness. Brain Res Reviews 2005; 50: 184-199*
18. *Metzinger T. Being No One. Cambridge: MIT Press, 2003*
19. *Blanke O, Ortigue S, Landis T, Seeck M. Stimulating illusory own-bodyperceptions. Nature 2002; 419: 269-270*

20. *Ramachandran VS, Hirstein W. The perception of phantom limbs. Brain 1998; 121: 1603-1630*
21. *Halligan PW. Phantom limbs: The body in mind. Cogn Neuropsychiatr 2002; 7: 251-268*
22. *Tsakiris M, Hesse MD, Boy C et al. Neural signatures of body ownership: a sensory network for bodily self-consciousness. Cer Cortex (in press)*
23. *DeGiorgio CM, Medina MT, Duron R et al. Neurocysticercosis. Epilepsy Currents 2004; 4: 107-111*
24. *Zambioni G, Budredi C, Nichelli P. "Seeing oneself": a case of autoscopy. Neurocase 2005; 11: 212-215*
25. *Wallin MT, Kurtzke JF. Neurocysticercosis in the United States. Neurology 2004; 64: 1559-1564*
26. *Maillard L, Vignal JP, Anxionnat R et al. Semiologic value of ictal autoscopy. Epilepsia 2004; 45: 391-394*
27. *Bhaskaran R, Kumar A, Nayar PC. Autoscopy in the hemianopic field. J Neurol Neurosurg Psychiatry 1990; 53: 1016-1017*
28. *Féré C. Note sur les hallucinations autoscopiques ou spéculaires et sur les hallucinations altruistes. Comptes Rendues Hebdomedaires des Séances et Mémoirs de la Société de Biologie 1891; 3: 451-453*
29. *Naudascher MG. Trois cas d'hallucinations spéculaires. Ann Médico-Psychol 1910; 68: 284-296*
30. *Penfield W. The role of the temporal lobe in certain psychical phenomena. J Ment Sci 1955; 101: 451-465*
31. *Gloor P, Olivier A, Quesney LF et al. The role of the limbic system in experiential phenomena of temporal lobe epilepsy. Ann Neurol 1982; 12: 129-144*
32. *Blanke O, Landis T, Seeck M. Electrical cortical stimulation of the human prefrontal cortex evokes complex visual hallucinations. Epilepsy & Behavior 2000; 1: 356-361*
33. *Vignal J-P, Maillard L, McGonigal A, Chauvel P. The dreamy state: hallucinations of autobiographical memory by temporal lobe stimulations and seizures. Brain 2006; 130: 88-99*
34. *Lukianowicz N. Autoscopic phenomena. Arch Neurol Psychiatr 1958; 80: 199-220*

Address for correspondence:
Prof. Olaf Blanke
Laboratory of Cognitive Neuroscience
Brain-Mind Institute
Ecole Polytechnique Fédérale de Lausanne (EPFL)
CH 1015 Lausanne
Tel. 0041 21 6939621
Fax 0041 21 6939625
olaf.blanke@epfl.ch

Epilepsie-Liga

forscht – hilft – informiert

Neuer Versicherungsratgeber

Der neue Versicherungsratgeber „Epilepsie und Versicherungen“, herausgegeben von der Epilepsie-Liga, enthält nützliche Informationen über den Umgang mit Versicherungen im Zusammenhang mit einer epileptischen Erkrankung. Die Autorin Evalotta Samuelsson ist Rechtsanwältin und hat reiche Erfahrung in Sozial-, Privat- und Haftpflichtversicherungsfragen. Der Aufbau der Broschüre in zehn Kapitel ist übersichtlich, Lesende finden rasch Informationen zu Hilflosigkeit und Pflegebedürftigkeit von Kindern, zu Ergänzungsleistungen, zu AHV-Renten oder Leistungen bei lang dauernder Erwerbsunfähigkeit. Der Anhang des Ratgebers enthält wichtige Adressen für Betroffene und die sie begleitenden Fachpersonen. „Epilepsie und Versicherungen“ erscheint in Deutsch, Französisch und Italienisch und ist erhältlich bei der Epilepsie-Liga.

Bestellgutschein

- Ich melde mich als **Einzelmitglied** an und bezahle jährlich mindestens 50 Franken. Schicken Sie mir bitte die Mitgliedschaftsunterlagen.
- Wir werden **Kollektivmitglied** und bezahlen mindestens 100 Franken pro Jahr. Bitte senden Sie uns die Mitgliedschaftsunterlagen.
- Ihre Arbeit überzeugt mich. Ich möchte der Liga etwas spenden und bitte um ..... **Einzahlungsschein(e)**.
- Ich wünsche die Zustellung einer Liste Ihres **Informationsmaterials**.
- Bitte schicken Sie mir Ihren Ratgeber für **Legate und Testamente**.
- Ich habe **Fragen** zum Thema Epilepsie. Bitte nehmen Sie Kontakt auf mit mir.
- Ihre **Fachzeitschrift „Epileptologie“** interessiert mich. Bitte senden Sie mir ein Probeexemplar.
- Ich möchte den Newsletter **„Epilepsie“** für Freunde und GönnerInnen erhalten.
- Bitte schicken Sie mir ..... Flyer **„Epilepsie und Autofahren“**. ■ deutsch ■ französisch ■ italienisch
- Bitte schicken Sie mir die Broschüre **„Epilepsie und Versicherungen“** ■ deutsch ■ französisch ■ italienisch

Die aktualisierten Richtlinien zur Fahrtauglichkeit sind als separater Flyer erhältlich. Bitte bestellen Sie mit untenstehender Karte die gewünschte Anzahl und kreuzen Sie die gewünschte Sprache an.

Absender

Name

Beruf | Funktion

Strasse | Nr.

PLZ | Ort

Telefon

Fax

eMail

Bitte diese Seite abtrennen,
in einen Umschlag stecken und
frankiert senden an:

Schweizerische Liga gegen Epilepsie

Geschäftsstelle
Seefeldstrasse 84
Postfach 1084
CH 8034 Zürich

Ausschreibung – Forschungsförderung

Förderung der wissenschaftlichen Forschung im Bereich der Epilepsie (vorwiegend Starthilfen) durch die Schweizerische Liga gegen Epilepsie (Epilepsie-Liga)

Die Epilepsie-Liga unterstützt wissenschaftliche Projekte im Bereich der Epileptologie im Gesamtbetrag von

CHF 20'000.—

pro Jahr. Insbesondere soll die Erforschung von Ursachen und Behandlungen der Epilepsie gefördert werden.

Stipendien für Aus- oder Weiterbildung oder Auslandaufenthalte werden nicht ausgerichtet. Hingegen können Reise- und Aufenthaltskosten (ohne Salär) für Kurzaufenthalte (maximal einige Wochen) finanziert werden, sofern sie dem Erlernen von Methoden dienen, welche im Rahmen eines unterstützten Projektes in der Schweiz eingesetzt werden.

Falls der Antragsteller/die Antragstellerin bereits anderswo Anträge für Unterstützung gestellt hat, ist offen zu legen, bei wem und mit welchem Ergebnis.

Termin für die Einreichung von Gesuchen: 31. März 2008

Formulare und Wegleitung für Gesuchstellende können angefordert werden bei:

Schweizerische Liga gegen Epilepsie
Seefeldstrasse 84
Postfach 1084
8034 Zürich
Tel. 043 488 67 77
Fax 043 488 67 78
info@epi.ch

Vorschau Epileptologie 3 | 2007

Soziale Kognition und Aufmerksamkeit

Emotion und soziale Kognition aus epileptologischer Sicht
Prof. Dr. Bettina Schmitz / Berlin

Neuroscience of human social cognition and emotion
Prof. Dr. Patrik Vuilleumier / Genf

Theory of Mind Defizite bei Patienten mit mesialer Temporallappenepilepsie
MA Rebecca Winkler / Zürich

Zur Bedeutung von Defiziten in Emotion und sozialer Kognition für die soziale Integration
MA Rupprecht Thorbecke / Bielefeld

Zur Epidemiologie von Aufmerksamkeitsstörungen bei Menschen mit Epilepsie
MA Martin Brunner und PD Dr. Hennric Jokeit / Zürich

Soziale Aspekte von Epilepsie in der Romanliteratur
Prof. Dr. Michael Andermatt / Zürich

Ausschreibung – Promotionspreis

Die Schweizerische Liga gegen Epilepsie (Epilepsie-Liga) vergibt jährlich einen Preis in Höhe von

CHF 2'500.—

für die beste Dissertation auf dem Gebiet der Epileptologie.

Bewerbungen sind aus allen Fachbereichen und Berufsgruppen möglich und erwünscht, sowohl aus Grundlagen- als auch klinischen Fächern. Eine Altersbeschränkung erfolgt nicht.

Das Preisrichterkollegium setzt sich aus drei Vorstandsmitgliedern der Epilepsie-Liga zusammen, das bei Bedarf zusätzlich externe Gutachter hinzuziehen kann. Es trifft seine Entscheidung in geheimer Wahl.

Falls der Antragsteller/die Antragstellerin bereits anderswo Anträge für Unterstützung gestellt hat, ist offen zu legen, bei wem und mit welchem Ergebnis.

Die Preisverleihung erfolgt jeweils im darauf folgenden Jahr anlässlich der Jahrestagung oder Mitgliederversammlung der Epilepsie-Liga.

Bewerbungen sind **bis zum 31.12.07** an die **Geschäftsstelle der Epilepsie-Liga** (Seefeldstrasse 84, Postfach 1084, 8034 Zürich) einzureichen und müssen beinhalten: drei Exemplare der abgeschlossenen und beim Dekanat eingereichten Dissertation, drei Exemplare einer Stellungnahme des Doktorvaters (dabei kann es sich auch um das entsprechende Gutachten für die Dissertation handeln).

Nekrolog Rudolf Max Hess

Professor Rudolf Max Hess wurde am 4.9.1913 in Zürich geboren. Sein Vater, Walter Rudolf Hess, ein weltweit bekannter Physiologe, erhielt 1949 den Nobelpreis.

Ruedi Hess wuchs in Zürich auf. Nach der Primarschule besuchte er das Kant. Realgymnasium in Zürich, das er 1932 mit der Maturitätsprüfung abschloss.

Anschliessend studierte er Medizin in Lausanne, Zürich und Kiel: Zwei Semester naturwissenschaftliche Fächer mit dem 1. Propaedeuticum (1933) in Lausanne, drei Semester anatomisch-physiologische Fächer mit dem 2. Propaedeuticum (1935) in Zürich. Dann folgte ein klinisches Semester in Kiel (1936). Der Rest des klinischen Studiums wurde wieder in Zürich absolviert und im Frühjahr 1938 mit der Eidg. Medizinischen Fachprüfung abgeschlossen.

Die Weiterbildung erfolgte zunächst in Physiologie: Vom 1.9.38 – 31.12.39 war Ruedi Hess Assistent am Physiologischen Institut Zürich (Prof. W.R. Hess). Er promovierte im Jahre 1939. Seine Dissertation, eine bemerkenswerte Experimentalarbeit, befasste sich mit der Lokalisation des Atemzentrums.

Nach weiterer Ausbildung in Innerer Medizin in Lausanne (1940 - März 1942 bei Prof. Michaud) und Psychiatrie in Bern (April 1942 - Mai 1945 bei Prof. Klaesi) – vielfach unterbrochen von Aktivdienst-Perioden – trat Ruedi Hess am 17.5.1945 eine Assistentenstelle bei Hugo Krayenbühl in Zürich an. Nach eigenen Worten erwarb er von Krayenbühl, dem Begründer der Neurochirurgie in der Schweiz, nicht nur profunde neurologische Kenntnisse sondern auch Berufsethik.

Als neurologischer Assistent an der damals noch in der Aussenstation Hegibach untergebrachten neurochirurgischen Abteilung des Kantonsspitals Zürich entschloss sich Ruedi Hess Ende 1946 für die Spezialisierung auf dem Gebiet der Elektroenzephalographie. Er hatte Glück: Prof. Krayenbühl, der an der Einführung dieser neuen und in der Schweiz damals noch völlig unbekannten diagnostischen Methode sehr interessiert war, schickte ihn 1947 zur Erlernung der Registrierung der Hirnströme nach London, wo Prof. Ruedi Hess über 5/4 Jahre am National Hospital for Nervous Diseases, Queen Square, in der Neurological Research Unit (Dr. E. A. Carmichael) und anschliessend (im Mai 1948) am EEG-Center des Burden Neurological Institute in Bristol, bei Gray Walter, verbrachte. Mit seinen englischen Lehrern verband Ruedi Hess zeitlebens eine tiefe respektvolle Freundschaft. Dem nüchternen Geist der englischen Wissenschaft fühlte sich Ruedi Hess stets verpflichtet.

1948, nach seiner Rückkehr in die Schweiz, begründete und leitete Ruedi Hess die erste EEG-Station der Schweiz am Kantonsspital Zürich. Das EEG mit der Nummer 1 wurde am 8. Okt. 1948 noch in der Aussenstation Hegibach abgeleitet. Nach einigen Monaten als ausserordentlicher Assistent der Neurochirurgischen Klinik wurde er am 1. Oktober 1948 Leitender Arzt der Elektroenzephalographischen Station der Neurochirurgischen und Psychiatrischen Kliniken des Kantonsspital Zürich.

1972 – ich war damals bereits Assistent bei Ruedi Hess – wurde seine EEG Station als „Institut für Elektroencephalographie“ verselbständigt. Ich erinnere mich noch sehr gut, wie Ruedi Hess bei einer kleinen Feier die doppelte Nabelschnur, das heisst die organisatorische Abhängigkeit von den beiden Kliniken, auf einem improvisierten selbstgemalten Backpapier, symbolisch durchschnitt und er anschliessend von dem anwesenden Hugo Krayenbühl als „Neugeborener“ beglückwünscht wurde.

Aber noch sind wir anfangs der Fünfzigerjahre. Damals wiederholte die Schweizer Forschergruppe Akert-Koella-Hess die berühmt gewordenen Stimulationsversuche von Walter Hess an der Katze unter gleichzeitiger Aufzeichnung der kortikalen und subkortikalen Aktivität mit dem EEG (die entsprechende Publikation „Sleep produced by electrical stimulation of the thalamus“ erschien im Jahre 1952 im Am J Phys).

August 1953 trat Ruedi Hess einen – wohl gemerkt – unbezahlten Kongress- und Studienaufenthalt in den U.S.A. und Kanada an. Dieser Aufenthalt führte ihn in die bekanntesten EEG-Laboratorien der USA und war gefolgt von einem halben Jahr Fortbildungsaufenthalt am damals weltberühmten „Montreal Neurological Institute“ (unter Wilder Penfield), wo Ruedi Hess Gelegenheit hatte, neben der experimentellen Tätigkeit die dort hoch entwickelte Methodik der Abklärung und operativen Behandlung medikamentös therapieresistenter Epilepsien kennen zu lernen und dann nach seiner Rückkehr auch in Zürich anzuwenden.

Die Betreuung der nicht-operablen Epilepsie-Kranken wurde neben der Auswertung der EEG zur zweiten Hauptaufgabe. Mit der klinischen Arbeit war immer auch die Suche nach Erklärung der beobachteten Phänomene und die Weitergabe der Erfahrungen in zahlreichen Vorträgen und Publikationen verbunden.

Die Habilitation 1958 war die natürliche Konsequenz. Ruedi Hess habilitierte sich mit seiner Monographie

„Elektroenzephalographische Studien bei Hirntumoren". 1962 erfolgte die Ernennung zum Extraordinarius und 1978 schliesslich zum Ordinarius, doch blieb die akademische Karriere für Ruedi Hess nach eigenen Worten ein Nebenschauplatz.

Als weltweit anerkannte Autorität schrieb Ruedi Hess grundlegende Kapitel in Standardwerken der neurologischen Wissenschaften, was wohl u.a. auch dazu führte, dass Chronisten die Zürcher Schule um Ruedi Hess am Höhepunkt seiner Karriere zu den europäischen Eckpfeilern der Klinischen Elektrophysiologie zählten.

Ruedi Hess engagierte sich – soweit es ihm zeitlich neben den klinischen Verpflichtungen möglich war – sehr in diversen Fachgesellschaften, und seine Arbeit in diesen Gremien, die erstklassige Ausbildung und gute Qualität als Ziel hatte, wurde entsprechend gewürdigt.

Er war Gründungsmitglied und 1948 erster Sekretär der Schweiz. EEG-Gesellschaft, und wurde 1959 - 1963 ihr Präsident. Weitere Engagements:

- 1969 Korrespondierendes Mitglied der Deutschen Sektion der Liga gegen Epilepsie
- 1969 - 1973 Kassier der Internationalen Föderation der EEG-Gesellschaften
- 1973 Ehrenmitglied der Deutschen EEG-Gesellschaft/Deutschen Gesellschaft für Klinische Neurophysiologie
- 1974 Ehrenmitglied der Schweizerischen EEG-Gesellschaft/Schweizerischen Gesellschaft für Klinische Neurophysiologie (SGKN)
- 1976 - 1978 Präsident der Naturforschenden Gesellschaft des Kantons Zürich.
- 1980 Präsident der Schweizerischen Liga gegen Epilepsie (SLgE)
- 1983 Membre d'honneur de la Société d'EEG et Neurophysiologie clinique de Langue Française
- 1984 Ehrenpräsident der Schweizerischen Liga gegen Epilepsie (SLgE)
- 1997 Ehrenpräsident der Schweizerischen Gesellschaft für Klinische Neurophysiologie (ehem. Schweizerische EEG-Gesellschaft)
- 2003 Ehrenmitglied der Schweizerischen Neurologischen Gesellschaft (SNG)
- Zusammen mit Caspers, Kubicki, Petsche, Struppler und Kugler begründete er die Zeitschrift EEG-EMG.

Im familiären Bereich, der wie bei allen Ärzten zu kurz kam, war die Heirat mit Silvia Schmid, Dr. phil. I, 1940, das wichtige Ereignis. Von den 4 Kindern wählten eine Tochter und ein Sohn eine psychologische bzw. psychiatrische Berufsrichtung, der dritte Sohn wurde Neurologe und ist Klinikdirektor an der Universität Bern. Der Jüngste ist an der Universität Zürich Leiter der Abteilung für Computerlinguistik am Institut für Informatik.

Die militärische Laufbahn schloss Ruedi Hess als Sanitäts-Major ab.

Der Rücktritt von der beruflichen Stellung erfolgte 1981 nach 33 Jahren Leitung der EEG-Station und des späteren Instituts für Elektroenzephalographie am Zürcher Kantonsspital bzw. Universitätsspital. Die noch anhaltenden wissenschaftlichen Interessen und Aktivitäten wurden bisweilen durch eine rege Reisetätigkeit unterbrochen.

Ruedi Hess war auf seinem Gebiet die internationale Anerkennung nicht versagt. 1962 erhielt er den Hans Berger-Preis der Deutschen EEG-Gesellschaft, die höchste Auszeichnung auf dem Gebiet der Elektroenzephalographie, 1972 ernannte ihn das International Bureau for Epilepsy zum „Ambassador for Epilepsy". Wegen seiner Verdienste um das Internationale EEG Journal wurde Ruedi Hess 1977 vom damaligen Präsidenten Bill Cobb zum Honorary Consultant ernannt.

Anlässlich der Eröffnung des Internationalen Symposiums über „Methods of Presurgical Evaluation of Epileptic Patients" (12.-15. Sept. 1985), das ich organisieren durfte, hat Henri Gastaut vor 150 Teilnehmern aus 19 Ländern und 5 Kontinenten für Prof. Ruedi Hess die Ehrenansprache gehalten. Zu seinem 70. und dann zum 80. Geburtstag (1993) schalteten alle grossen Zeitungen der Schweiz Glückwunschadressen. Am 5. Sept. 2003 konnte ich meinem verehrten Lehrer zu seinem 90. Geburtstag nochmals ein Symposium widmen. Es spricht für die selbstkritisch-ironische Art, dass sich Ruedi Hess auf der Einladung als Indianerhäuptling mit Federschmuck, Tomahak und Friedenspfeife abbilden liess und auf meine etwas verwunderte Nachfrage meinte, das sei für ihn die höchste Auszeichnung, die er nebst dem Berger-Preis 1962 erhalten habe.

Im Februar 1986 erfolgte die Übersiedlung von der zu gross gewordenen Stadtwohnung in die kleine Alterswohnung auf dem Zollikerberg. Ein tiefer Einschnitt in seinem Leben war 1997 der Tod seiner lieben Ehefrau Silvia nach längerer Krankheit. Seither wohnte er im Zollikerberg alleine, umgeben von einer liebenswerten Nachbarschaft. Bis zum Schluss unternahm er tägliche Spaziergänge und auch noch längere Wanderungen.

Am 10. März 2007 ist Professor Ruedi Hess, der Begründer der Schweizerischen Elektroenzephalographie, nach kurzer schwerer Krankheit verstorben. Ruedi Hess hat in seiner Werkstatt in aller Stille, aber mit scharfsinniger Beobachtung und Beharrlichkeit gearbeitet. Die weltweit anerkannte Autorität beruhte nicht nur auf seinem Erfahrungsschatz, sondern im gleichen Masse auf seinem kritischen Denken gepaart mit schonungsloser Selbstkritik und Ironie. In diesem Sinne war er uns zeitlebens das Vorbild als Arzt, Forscher und Lehrer. Ruedi Hess hat mehr als 60 Schüler aus dem In- und Ausland in sein Spezialgebiet eingeführt.

Namens der Universität Zürich vertreten durch Rektor Prof. Weder, der Medizinischen Fakultät vertreten durch Dekan Prof. Bär, Deiner Schüler und Freunde nehmen wir Abschied. Wir werden Dein Andenken, lieber Ruedi, in dankbarer Erinnerung bewahren.

Prof. Heinz Gregor Wieser, Zürich

Nécrologie Rudolf Max Hess

Le professeur Rudolf Max Hess a vu le jour le 4.9.1913 à Zurich. Son père, Walter Rudolf Hess, un physiologiste de renommée mondiale, a obtenu le Prix Nobel en 1949. Ruedi Hess a vécu son enfance à Zurich. Après la scolarité obligatoire, il est entré au gymnase cantonal de Zurich où il a obtenu sa maturité en 1932. Il a ensuite fait des études de médecine à Lausanne, Zurich et Kiel :

2 semestres de sciences naturelles à Lausanne conclus par un premier propédeutique (1933), 3 semestres d'anatomie et physiologie à Zurich achevés par un 2e propédeutique (1935), puis un semestre clinique à Kiel (1936). Pour le reste des études cliniques, il est retourné à Zurich où il a passé ses examens fédéraux de médecine en 1938.

Pour parfaire sa formation, il s'est d'abord tourné vers la physiologie: du 1.9.38 - 31.12.39, Ruedi Hess a été assistant à l'Institut de physiologie à Zurich (prof. W.R. Hess) où il a passé son doctorat en 1939. Sa thèse, un travail expérimental remarquable, avait pour thème la localisation du centre respiratoire.

Il a ensuite effectué un stage à Lausanne en médecine interne (1940 - mars 1942 chez le prof. Michaud) et un autre en psychiatrie à Berne (avril 1942 - mai 1945 chez le prof. Klaesi) avec de nombreuses interruptions au service actif de la patrie. Le 17.5.1945 enfin, Ruedi Hess est devenu l'assistant de Hugo Krayenbühl à Zurich, le fondateur de la neurochirurgie en Suisse. Krayenbühl dont Ruedi Hess a affirmé qu'il lui avait transmis non seulement une connaissance profonde de la neurologie, mais aussi l'éthique de la profession.

En tant qu'assistant au service de neurologie de l'hôpital cantonal de Zurich abrité à l'époque par la station externe de Hegibach, Ruedi Hess a opté à fin 1946 pour une spécialisation dans le domaine de l'électroencéphalographie. Et heureusement pour lui, le prof. Krayenbühl qui vouait un grand intérêt à cette méthode diagnostique encore totalement inconnue en Suisse à cette époque, l'envoya à Londres en 1947 pour apprendre à enregistrer le tracé électrique cérébral. Le prof. Ruedi Hess y a passé plus de quinze mois, d'abord au National Hospital for Nervous Diseases, Queen Square, dans le Neurological Research Unit (Dr. E. A. Carmichael), puis ensuite (en mai 1948), au centre EEG du Burden Neurological Institute à Bristol, sous la férule de Gray Walter. Les liens d'amitié et de profond respect qu'il a forgés avec ses maîtres anglais durant cette période allaient durer toute une vie. Ruedi Hess a toujours éprouvé une forte affinité avec l'esprit scientifique britannique marqué par une objectivité saine et positive.

En 1948, après son retour en Suisse, Ruedi Hess a créé et dirigé la première station d'EEG de Suisse à l'hôpital cantonal de Zurich. L'EEG portant la matricule 1 a été réalisé le 8 octobre 1948, encore à la station externe de Hegibach. Après quelques mois en tant qu'assistant extraordinaire de la clinique de neurochirurgie, Hess a été nommé médecin responsable de la station d'électro-encéphalographie des cliniques de neurochirurgie et psychiatrie de l'hôpital cantonal de Zurich.

En 1972, époque où j'étais déjà l'assistant de Ruedi Hess, sa station d'EEG s'est émancipée sous la désignation « Institut d'électro-encéphalographie ». Je me souviens parfaitement d'une petite cérémonie au cours de laquelle Ruedi Hess a coupé « un cordon ombilical » peint de ses propres mains sur du papier parchemin pour symboliser la double dépendance organisationnelle des deux cliniques, après quoi Hugo Krayenbühl qui était présent a félicité le « nouveau-né ».

Mais j'anticipe. Retournons aux années cinquante. Le groupe de chercheurs suisses Akert-Koella-Hess répète alors les déjà célèbres essais de stimulation de Walter Hess sur le chat avec enregistrement simultané par EEG de l'activité corticale et subcorticale (la publication correspondante "Sleep produced by electrical stimulation of the thalamus" a paru en 1952 dans Am J Phys).

En août 1953, Ruedi Hess est parti aux Etats-Unis et au Canada pour un séjour – non payé ! – de congrès et d'études. Ce séjour l'a conduit dans les laboratoires d'EEG les plus renommés des Etats-Unis et il a enchaîné un séjour de formation de six mois dans le „Montreal Neurological Institute“ (sous Wilder Penfield) mondialement connu à l'époque. A côté de son activité expérimentale, Ruedi Hess a eu l'occasion d'y faire la connaissance de la méthodique déjà très développée de l'investigation et du traitement opératoire d'épilepsies réfractaires aux thérapies médicamenteuses qu'il allait introduire à Zurich après son retour.

L'encadrement des épileptiques non opérables est devenu sa deuxième mission clé à côté de l'évaluation des EEG. Son travail clinique est toujours allé de pair avec la recherche d'explications aux phénomènes observés et la transmission de ses enseignements sous forme de nombreux exposés et publications.

L'agrégation en 1958 en a été la conséquence naturelle et il a soutenu sa thèse dans une monographie intitulée "Elektroenzephalographische Studien bei Hirntumoren". En 1962, il a été nommé professeur extraordi-

naire et en 1978 enfin, sa carrière académique a culminé avec le titre de professeur titulaire, une carrière dont Ruedi Hess lui-même a cependant confessé qu'elle n'avait pour lui qu'une importance secondaire.

Mondialement reconnu comme faisant autorité dans son domaine, Ruedi Hess a écrit des chapitres fondamentaux dans des ouvrages de référence sur les sciences neurologiques, contribuant ainsi à faire entrer ce que les chroniqueurs appelaient l'école de Zurich autour de Ruedi Hess à l'olympe de l'électrophysiologie clinique européenne.

Dans la mesure où ses obligations cliniques lui en laissaient le temps, Ruedi Hess s'est engagé dans des organisations d'experts très diverses et son travail dans ces organismes au service d'une formation de pointe et de la bonne qualité a été dûment apprécié.

Il a notamment été membre fondateur et premier secrétaire en 1948 de la Société suisse d'EEG dont il a assumé la présidence de 1959 à 1963. Autres engagements :

- 1969 Membre correspondant de la section allemande de la Ligue contre l'Epilepsie
- 1969 - 1973 Trésorier de la Fédération internationale des sociétés d'EEG
- 1973 Membre d'honneur de la Société allemande d'EEG / Société allemande de neurophysiologie clinique
- 1974 Membre d'honneur de la Société suisse d'EEG / Société suisse de neurophysiologie clinique (SSNC)
- 1976 - 1978 Président de la Société des sciences naturelles du Canton de Zurich
- 1980 Président de la Ligue Suisse contre l'Epilepsie (LScE)
- 1983 Membre d'honneur de la Société d'EEG et Neurophysiologie clinique de Langue Française
- 1984 Président d'honneur de la Ligue Suisse contre l'Epilepsie (LScE)
- 1997 Président de la Société suisse de neurophysiologie clinique (anciennement Société suisse d'EEG)
- 2003 Membre d'honneur de la Société suisse de neurologie (SSN)

En collaboration avec Caspers, Kubicki, Petsche, Struppler et Kugler, il a fondé la revue EEG-EMG.

Dans sa vie privée, toujours un peu négligée comme celle de tout autre médecin, le jalon le plus important a été son mariage en 1940 avec Silvia Schmid, Dr ès sc. nat. Quatre enfants sont issus de cette union : une fille et un fils ont embrassé une carrière dans la psychologie et la psychiatrie respectivement, le troisième fils est devenu neurologue et dirige la clinique de l'Université de Berne. Le cadet dirige à l'Université de Zurich le département de linguistique de l'ordinateur à l'Institut d'informatique.

Ruedi Hess a achevé sa carrière militaire au rang de major des troupes sanitaires.

Il a quitté la vie active en 1981 après 33 ans à la direction de la station d'EEG de ce qui est devenu plus tard l'Institut d'électroencéphalographie à l'hôpital cantonal de Zurich, puis centre hospitalier universitaire. Toujours captivé par la science, il a poursuivi de nombreuses activités, mais a aussi profité de découvrir le monde au cours de nombreux voyages.

Dans son domaine, Ruedi Hess était une sommité reconnue par ses pairs dans le monde entier. En 1962, le Prix Hans Berger de la Société allemande d'EEG lui a été décerné, la plus haute distinction dans le domaine de l'électroencéphalographie ; en 1972, l'International Bureau for Epilepsy l'a nommé « Ambassador for Epilepsy ». Son activité méritoire pour le Journal international de l'EEG lui a valu le titre d'Honorary Consultant, décerné par le président de l'époque, Bill Cobb.

A l'occasion de l'inauguration du Symposium international sur les « Methods of Presurgical Evaluation of Epileptic Patients » (12-15 sept. 1985) que j'ai eu le privilège d'organiser, Henri Gastaut a prononcé le panégyrique du prof. Ruedi Hess devant 150 participants en provenance de 19 pays et 5 continents. A l'occasion de son 70e, puis de son 80e anniversaire (1993), tous les grands quotidiens suisses ont fait son éloge dans leurs pages. Le 5 septembre 2003, j'ai eu la joie de rendre un nouvel hommage à mon professeur tant admiré en organisant un symposium à l'occasion de son 90e anniversaire. L'événement lui a servi de prétexte pour fournir une nouvelle preuve de son ironie autocritique en se faisant représenter sur l'invitation en tant que chef d'une tribu indienne avec tous ses attributs : plumes, hache de guerre et calumet de la paix. Sentant mon étonnement, il m'a expliqué qu'en dehors du Prix Berger de 1962, c'était la plus haute distinction qui lui avait jamais été décernée.

En février 1986, son appartement en ville étant devenu trop grand, il s'est installé dans une résidence pour personnes du troisième âge sur le Zollikerberg. Le décès de sa chère épouse Silvia en 1997 au terme d'une longue maladie a laissé un grand vide. Depuis, il habitait seul au Zollikerberg, en bonne harmonie avec son voisinage. Jusqu'au bout, il a entrepris des promenades quotidiennes et parfois même des randonnées plus longues.

Le 10 mars 2007, le professeur Ruedi Hess, fondateur de l'encéphalographie suisse, s'est éteint après une courte et grave maladie. Ruedi Hess œuvrait discrètement dans son atelier, mais avec un esprit constamment en éveil et une persévérance exemplaire. Mondialement reconnu, son autorité était fondée non seulement sur son vaste réservoir d'expérience, mais aussi sur sa réflexion critique, toujours teintée d'autocritique et d'une impitoyable ironie à son propre égard. Ces qualités en ont fait pour nous l'incarnation vivante de l'idéal d'un médecin, chercheur et enseignant. Ruedi Hess a initié à sa spécialité plus de 60 disciples venus de Suisse et d'ailleurs.

Au nom de l'Université de Zurich représentée par son recteur, le prof. Weder, de la Faculté de médecine, représentée par son doyen, le prof. Bär, de tes élèves et amis, nous prenons congé de toi, cher Ruedi. Mais nous te porterons toujours dans nos coeurs avec un sentiment d'amitié et de reconnaissance profonde

Heinz Gregor Wieser, Zurich

2007

27.-30.6.2007 | Cleveland, Ohio, USA
The 17th International Epilepsy Symposium: Epilepsy Surgery Techniques and Dissection Exercises
Information: Pierrette Sahlani,
Tel. 001 / 216 / 4445178, Fax 001 / 216 / 4440230,
e-mail: sahlanp@ccf.org,
www.clevelandclinic.org/neuroscience/professionals/cme

8.-12.7.2007 | Singapur, China
27th International Epilepsy Congress
Information: ILAE / IBE Congress Secretariat,
7 Priory Hall, Stillorgan, Dublin 18, Ireland,
Tel: 00353 /1 / 2056720, Fax 00353 / 1 / 2056156,
e-mail: info@epilepsycongress.org,
www.epilepsysingapore2007.org oder
www.epilepsycongress.org

25.-28.8.2007 | Brüssel, Belgien
11th Congress of the European Federation of Neurological Societies (EFNS)
Information: Kenes International, 17 Rue du Cendrier,
PO Box 1726, 1211 Geneva 1, Switzerland,
Tel. 0041 / 22 / 9080488, Fax 0041 / 22 / 7322850,
e-mail: efns2007@kenes.com, www.kenes.com/efns2007

2.-9.9.2007 | Eilat, Israel
2nd Eilat International Education Course: Pharmacological Treatment of Epilepsy
Information: Target Conferences, P.O. Box 29041,
Tel Aviv 61290, Israel,
Tel. 0972 / 3 / 5175150, Fax 0972 / 3 / 5175155,
e-mail: eilatedu@targetconf.com

6.-9.9.2007 | Berlin, Deutschland
1st World Congress on Controversies in Neurology (CONy)
e-mail: cony@comtecmed.com,
www.comtecmed.com/cony

12.-15.9.2007 | Berlin, Deutschland
80. Kongress der Deutschen Gesellschaft für Neurologie (DGN) mit Fortbildungsakademie
Information: AKM Congress Service GmbH, Obere Schanzstr. 18, 79576 Weil am Rhein, Deutschland
Tel. 0049 / 7621 / 98333-0, Fax 0049 / 7621 / 78714,
e-mail: akmweil@akmcongress.com,
www.cme-akm.de

19.-22.9.2007 | Gargnano, Gardasee, Italien
19. Praxisseminar über Epilepsie
Information: Stiftung Michael, Münzkamp 5,
22339 Hamburg, Deutschland,
Tel. 0049 / 40 / 5388540, Fax 0049 / 40 / 5381559,
e-mail: stiftungmichael@t-online.de,
www.stiftungmichael.de

26.-29.9.2007 | Kusadasi, Türkei
7th Congress of the European Paediatric Neurology Society (EPNS)
Information: Flapt Tour, Congress Department,
Tel. 0090 / 312 / 4540000/1503,
Fax 0090 / 312 / 4540024,
e-mail: sehri.yaman@flaptour.com.tr, www.epns2007.org

27.9.2007 | Montreux, Grand Hôtel Excelsior, à 16 heures
Manifestation de formation de la Ligue Suisse contre l'Epilepsie
Information: Secrétariat général, Ligue contre l'Epilepsie, Seefeldstrasse 84, Case postale 1084,
8034 Zurich,
Tél. 0041 / 43 / 4886777, Fax 0041 / 43 / 4886778,
e-mail : info@epi.ch, www.epi.ch

27.9.2007 | Montreux, Grand Hôtel Excelsior, à 18.30 heures
Manifestation publique de la Ligue Suisse contre l'Epilepsie et Epi-Suisse
Information : Secrétariat général, Ligue contre l'Epilepsie, Seefeldstrasse 84, Case postale 1084,
8034 Zurich,
Tél. 0041 / 43 / 4886777, Fax 0041 / 43 / 4886778,
e-mail : info@epi.ch, www.epi.ch

5.10.2007 | Bern, Kultur-Casino
Tag der Epilepsie
Information: Geschäftsstelle Epilepsie-Liga,
Seefeldstrasse 84, Postfach 1084, 8034 Zürich,
Tel. 0041 / 43 / 4886777, Fax 0041 / 43 / 4886778,
e-mail : info@epi.ch, www.epi.ch

12.-14.10.2007 | Recklinghausen, Deutschland
3. Tagung Klinische Neurophysiologie
Information: Thieme.congress in Georg Theime Verlag KG, Rüdigerstr. 14, 70469 Stuttgart, Deutschland,
Tel. 0049 / 711 / 8931320,
Fax 0049 / 711 / 8931370,
e-mail: fortbildung@thieme.de, www.thieme.de/dgkn

8.-9.11.2007 | Genf
23. Tagung der Schweizerischen Kopfwehgesellschaft (SKG) und Jahrestagung Schweizerische Gesellschaft für Neuropädiatrie (SGNP)
Information: IMK Institut für Medizin und Kommunikation AG, Münsterberg 1, 4001 Basel, Tel. 0041 / 61 / 2713551, Fax 0041 / 61 / 2713338, e-mail: mail@imk.ch, www.imk.ch

10.11.2007 | Zürich
Patiententag Epilepsie-Liga und Epi-Suisse
Information: Geschäftsstelle Epilepsie-Liga, Seefeldstrasse 84, Postfach 1084, 8034 Zürich, Tel. 0041 / 43 / 4886777, Fax 0041 / 43 / 4886778, e-mail: info@epi.ch, www.epi.ch

15.11.2007 | Basel
Fachveranstaltung der Schweizerischen Liga gegen Epilepsie
Information: Geschäftsstelle, Epilepsie-Liga, Seefeldstrasse 84, Postfach 1084, 8034 Zürich, Tel. 0041 / 43 / 4886777, Fax 0041 / 43 / 4886778, e-mail: info@epi.ch, www.epi.ch

22.-24.11.2007 | Fribourg
179. Jahrestagung der Schweizerischen Neurologischen Gesellschaft (SNG) und die Jahrestagung der Schweizerischen Gesellschaft für Neurorehabilitation
Information: IMK Institut für Medizin und Kommunikation AG, Münsterberg 1, 4001 Basel, Tel. 0041 / 61 / 2713551, Fax 0041 / 61 / 2713338, e-mail: mail@imk.ch, www.imk.ch

30.11.-4.12.2007 | Philadelphia, Pennsylvania, USA
61th Annual Meeting of the American Epilepsy Society (AES)
Information: Karan Murray, American Epilepsy Society, 638 Prospect Avenue, Hartford, CT 06195-4240, USA, Tel. 001 / 860 / 5867505, Fax 001 / 860 / 5867550, e-mail: info@aesnet.org, www.aesnet.org

2008

6.3.2008 | St. Gallen, Kantonsspital, 18 Uhr
Fachveranstaltung der Schweizerischen Liga gegen Epilepsie
Information: Geschäftsstelle, Epilepsie-Liga, Seefeldstrasse 84, Postfach 1084, 8034 Zürich, Tel. 0041 / 43 / 4886777, Fax 0041 / 43 / 4886778, e-mail: info@epi.ch, www.epi.ch

6.3.2008 | St. Gallen, Kantonsspital, 20.15 Uhr
Publikumsveranstaltung der Schweizerischen Liga gegen Epilepsie mit Epi-Suisse
Information: Geschäftsstelle, Epilepsie-Liga, Seefeldstrasse 84, Postfach 1084, 8034 Zürich, Tel. 0041 / 43 / 4886777, Fax 0041 / 43 / 4886778, e-mail: info@epi.ch, www.epi.ch

5.-12.4.2008 | Chicago, Illinois, USA
60th Annual Meeting of the American Academy of Neurology
Information: American Academy of Neurology, 1080 Montreal Avenue, St. Paul, MN 55116, USA, Tel. 001 / 651 / 6952717, Fax 001 / 651 / 6952791, e-mail: memberservice@aan.com, www.aan.com

1.-4.6.2008 | Würzburg, Deutschland
59. Jahrestagung der Deutschen Gesellschaft für Neurochirurgie (DGNC). Joint Meeting mit der Italienischen Gesellschaft für Neurochirurgie (SINch)
Porstmann Kongresse GmbH, Alte Jakobstr. 77, 10179 Berlin, Deutschland, Tel. 0049 / 30 / 2844990, Fax 0049 / 30 / 28449911, e-mail: dgnc2008@porstmann-kongresse.de, www.dgnc.de/dgnc2008

10.4.2008 | Luzern, Kantonsspital, 16 Uhr
Fachveranstaltung der Schweizerischen Liga gegen Epilepsie
Information: Geschäftsstelle, Epilepsie-Liga, Seefeldstrasse 84, Postfach 1084, 8034 Zürich, Tel. 0041 / 43 / 4886777, Fax 0041 / 43 / 4886778, e-mail: info@epi.ch, www.epi.ch

10.4.2008 | Luzern, Kantonsspital, 16 Uhr
Publikumsveranstaltung der Schweizerischen Liga gegen Epilepsie mit Epi-Suisse
Information: Geschäftsstelle, Epilepsie-Liga, Seefeldstrasse 84, Postfach 1084, 8034 Zürich, Tel. 0041 / 43 / 4886777, Fax 0041 / 43 / 4886778, e-mail: info@epi.ch, www.epi.ch

23.-26.8.2008 | Madrid, Spanien
12th Congress of the European Federation of Neurological Societies (EFNS)
Information: Kenes International, 17 Rue du Cendrier, PO Box 1726, 1211 Geneva, Tel. 0041 / 22 / 9080488, Fax 0041 / 22 / 7322850, e-mail: efns2008@kenes.com, www.kenes.com/efns2008 oder www.efns.org/efns2008

15.-20.9.2008 | Hamburg, Deutschland
81. Kongress der Deutschen Gesellschaft für Neurologie (DGN) mit Fortbildungsakademie
Information: AKM Congress Service GmbH, Obere Schanzstr. 18, 79576 Weil am Rhein, Deutschland. Tel. 0049 / 7621 / 98333-0, Fax 0049 / 7621 / 78714, e-mail: akmweil@akmcongress.com, www.cme-akm.de

21.-25.9.2008 | Berlin, Deutschland
8th European Congress on Epileptology (ECE)
International League Agianst Epilepsy (ILAE) Congress Secretariat, 7 Priory Hall, Stillorgan, Dublin 18, Irleand,
Tel. 0049/ 353 / 1 / 205 6720,
Fax 0049 / 353 / 1 / 205 6156,
e-mail: info@epilepsycongress.org,
www.epilepsycongress.org

5.-9.12.2008 | Seattle, Washington, USA
62th Annual Meeting of the American Epilepsy Society (AES)
Information: Karan Murray, American Epilepsy Society, 638 Prospect Avenue, Hartford, CT 06195-4240, USA,
Tel. 001 / 860 / 5867505,
Fax 001 / 860 / 5867550,
e-mail: info@aesnet.org

Meldungen von Veranstaltungen:
Bitte spätestens vier Monate im Voraus an die Redaktion.

ZEWO
ZERTIFIZIERT CERTIFIÉ CERTIFICATO
VERDIENT VERTRAUEN
MÉRITE CONFIANCE
MERITA FIDUCIA

Impressum

Herausgeber | Administration | Schlussredaktion
Schweizerische Liga gegen Epilepsie
Margret Becker, lic. phil. I
Seefeldstrasse 84, Postfach 1084,
CH-8034 Zürich
Tel. 0041 43 488 67 79
Fax 0041 43 488 67 78
becker@epi.ch

Konzeption | Gestaltung | Reinzeichnung
screenblue mediendesign | Birgit Depping
Schäferkampsallee 39, D-20357 Hamburg
bd@screenblue.de, www.screenblue.de

Belichtung | Druck
J.C.C. Bruns Betriebs GmbH
D-32423 Minden, www.jccbruns.de

Auflage
2.000 Exemplare

Versand
Eingliederungs- und Dauerwerkstätte
des Schweiz. Epilepsie-Zentrums
Bleulerstrasse 80, 8008 Zürich