

*Martinus Hauf, Olivier Scheidegger, Christian Rummel, Ali Rahman and Roland Wiest*

Support Center of Advanced Neuroimaging (SCAN), Institute of Diagnostic and Interventional Neuroradiology, Inselspital, Bern, University Hospital and University of Bern

### Summary

Simultaneous EEG/fMRI recordings offer a unique approach of characterizing epileptic brain activity. The combination of high temporal resolution of EEG recordings and high spatial resolution of fMRI add to enhance the localization of rapidly fluctuating epileptic sources in the brain parenchyma. Scalp EEG/fMRI is a non-invasive, safe and reproducible brain imaging technique and is increasingly implemented in the clinical pre-surgical workup of epilepsy surgery. Formal validation of the clinical value of EEG/fMRI recordings is challenging but current state of research suggests that EEG/fMRI analysis results in a comparable sensitivity compared to PET and SPECT imaging to identify the SOZ. In this review we discuss methodological considerations to identify and interpret epileptic activity in EEG/fMRI recordings, the proposed recent advances and ongoing challenges.

**Epileptologie 2012; 29: 90 – 98**

**Key words:** Epilepsy, EEG/fMRI, presurgical evaluation, hemodynamic response

### Neue Entwicklungen der simultanen EEG/fMRI in der Epilepsie – bereit für die klinische Anwendung?

Simultane EEG/fMRI-Ableitungen bieten eine einzigartige Möglichkeit, um epileptische Hirnaktivität zu charakterisieren. Die Kombination aus der hohen zeitlichen Auflösung der EEG-Aufnahme und die hohe räumliche Auflösung der fMRI hilft die schnell fluktuierenden epileptischen Quellen im Hirnparenchym zu lokalisieren. Skalp-EEG/fMRI ist eine nicht invasive, sichere und reproduzierbare Technik und wird zunehmend im Rahmen der prächirurgischen Abklärung eingesetzt. Die formale Validierung der EEG/fMRI-Untersuchung ist komplex, jedoch suggerieren die vorliegenden Studien, dass EEG/fMRI-Untersuchungen vergleichbar sensitiv sind wie PET- oder SPECT-Untersuchungen um die Anfallsursprungszone zu identifizieren. In diesem Review diskutieren wir methodologische

Überlegungen, wie epileptische Aktivität in der EEG/fMRI-Untersuchung identifiziert und interpretiert werden kann, in jüngerer Zeit entwickelte Lösungsvorschläge und die weiterhin offenen Fragen.

**Schlüsselwörter:** Epilepsie, EEG/fMRT, prächirurgische Diagnostik, hämodynamische Antwort

### Développements récents de l'électroencéphalographie et IRM fonctionnelle simultanées – un outil pour l'évaluation clinique ?

L'acquisition simultanée de l'électroencéphalogramme (EEG) et de l'IRM fonctionnelle (fMRI) offre une possibilité unique de caractériser l'activité épileptique cérébrale. La combinaison de l'EEG, possédant une résolution temporelle élevée, avec la fMRI, caractérisée par une haute résolution spatiale, permet d'obtenir au sein du parenchyme cérébral une localisation plus précise et dynamique de sources épileptiques rapidement fluctuantes. L'EEG/fMRI est une technique non-invasive, sûre et reproductible et tend à être de plus en plus utilisée lors de l'évaluation préchirurgicale des épilepsies pharmaco-résistantes. La validation formelle de l'EEG/fMRI est complexe, mais les données des études à disposition suggèrent que la sensibilité de l'EEG/fMRI pour identifier un foyer épileptique primaire est comparable à celle du PET ou du SPECT. Dans cette revue nous discutons de quelques aspects méthodologiques concernant l'identification et l'interprétation de l'activité épileptique au travers de l'enregistrement EEG/fMRI, des développements récemment proposés et des questions ouvertes à de futures recherches.

#### \*Acknowledgements

The article was supported by the Swiss National Science Foundation grant (320000-108321/1) and (33CM30-124089).

#### Copyright

The copyright for all figures remains with the authors.

**Mots clés :** Epilepsie, électroencéphalographie et IRM fonctionnelle simultanées, évaluation préchirurgicale, réponse hémodynamique

## 1. Introduction

The development of electroencephalogram (EEG) recordings simultaneous to functional MRI (fMRI) in the late 1990 was clinically motivated by the limited power of EEG to localize electrical sources of neuronal activity, in particular in deep brain structures [1]. In epilepsy, EEG/fMRI provides a unique opportunity to investigate simultaneously the fluctuations of the EEG signal representing synaptic activity of cortical pyramidal neurons and the hemodynamic responses (HR) of the blood oxygen level-dependent (BOLD) signal [2]. The combination of high temporal resolution of EEG recordings and high spatial resolution of fMRI add to enhance the localization of rapidly fluctuating epileptic sources in the brain parenchyma. EEG/fMRI has proven to be a noninvasive, safe and reproducible brain imaging technique [3-5]. A framework of methodologic and clinical studies has transformed EEG/fMRI into a powerful tool to investigate the hemodynamic changes associated with spontaneous brain activity in epileptic networks. Currently, simultaneous EEG/fMRI recordings in clinical epileptology are carried out in Switzerland at the Inselspital Bern and Hôpitaux Universitaires de Genève. Both centers focus on the application of EEG/fMRI for presurgical evaluation in focal epilepsies and are working together in the consortium “Imaging large-scale networks in epilepsy” funded by the Swiss National Science Foundation (SNF). In the present review, we will focus on novel developments of simultaneous EEG/

fMRI. First, we review approaches to identify interictal epileptic activity on scalp EEG for later use in fMRI analysis. Second, strategies to interpret the HR to interictal epileptiform discharges (IEDs) are discussed. We review the literature and discuss the current clinical value of EEG/fMRI recordings in epilepsy and the potential of some recent methodological developments.

## 2. Methodological considerations and developments

Safety issues of MR imaging [6, 7] and technical details of acquisition and preprocessing of EEG/MRI have been reviewed previously [8, 9]. **Figure 1** recapitulates issues of EEG artifact generation inside the “hostile environment” of a MR scanner due to pulsed field gradients (EEG signal fluctuations due to time-varying MR imaging gradients) and human pulse activity (ballistocardiogram; EEG signal fluctuations time-locked to cardiac activity via the static magnetic field). It aims to demonstrate the technical challenge to obtain an EEG signal of sufficient quality to identify IEDs. Gradient and pulse artifacts can be removed using the template average artifact subtraction method (AAS) described previously by Allen [10, 3]. While higher field strengths of the MR scanner and gradient systems increase the sensitivity to detect HR to IEDs, they also increase the various types of artifacts on EEG recordings. Therefore, an increasing number of centers use novel approaches, as the recently described temporal independent component analysis (ICA), to identify residual artifacts especially the ballistocardiogram and eye-blinks [11, 12]. The basic idea of combined EEG/fMRI is to identify certain features in the EEG, which are subsequently used

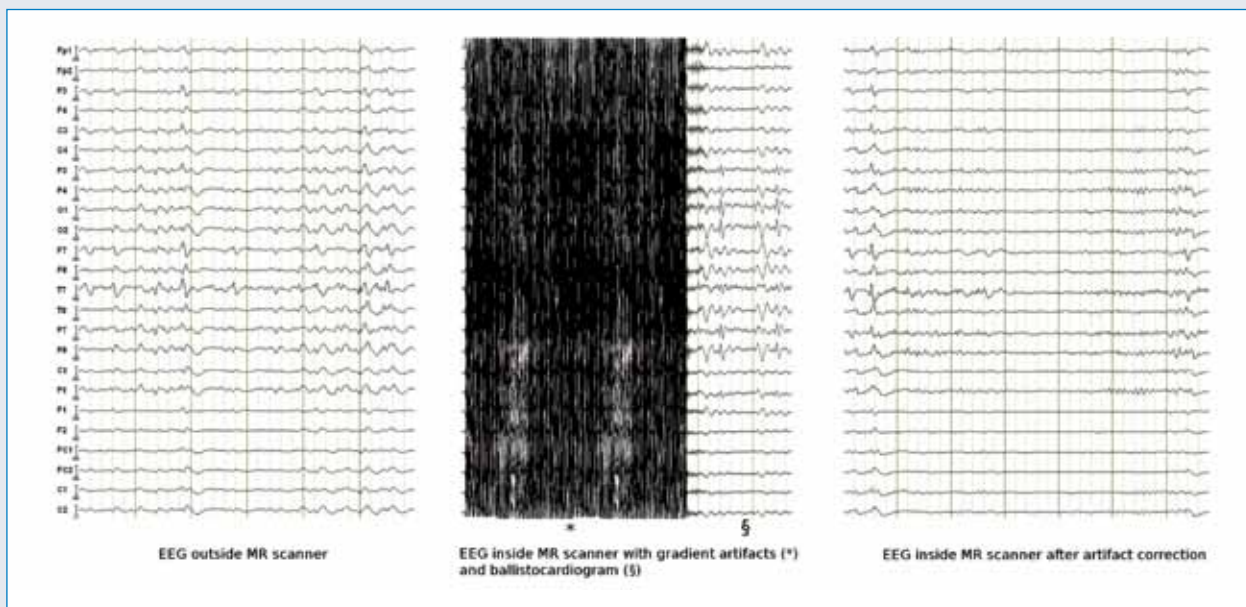


Figure 1

as predictors for the HR response. In epilepsy patients the most prominent feature is the presence of “spikes” on top of the background EEG. Therefore, the first and simplest approach to EEG/fMRI in epilepsy patients was to identify spikes visually, convolve the time series of spike timings with the hemodynamic response function (HRF) and subsequently analyze the spatial distribution of correlation of the BOLD signals with this predictor.

## 2.1 Interictal epileptic activity on surface EEG recordings

Prerequisite for the interpretation of EEG/fMRI is the detection of epileptic brain activity during the recording inside the MR scanner. The current strategies are based on visual or automated analysis of IEDs on the EEG recording after artifact removal [13, 14]. The temporal distribution of these IEDs are then processed as stereotyped “zero-duration” events in an event related model of the fMRI analysis (“spike-based” analysis). As the recording inside the MR scanner is confined to a restricted duration due to patient comfort and safety, there is a relevant portion of 40-70% of EEG/fMRI recordings without or with a limited number of IEDs. In these cases no significant HR can be detected [13, 15]. Importantly, only a fraction of interictal spikes recorded with intracranial electrodes can be identified on simultaneous scalp EEG recordings [16, 17]. Activity that is not detected on scalp EEG may, however, be associated with hemodynamic changes on BOLD fMRI [18]. This methodological issue results in challenges for EEG/fMRI recordings because time periods with interictal epileptic activity not fulfilling the criteria of spikes on visual scalp EEG may erroneously be attributed to the baseline signature of the fMRI signal. This introduces a bias towards false negative analysis results. In the following we discuss different approaches to overcome this limitation of EEG/fMRI recordings at least partly.

### a) ICA-based representation of IEDs

An alternative approach to extract IEDs in EEG/fMRI based on temporal ICA of surface EEG recordings has recently been developed by our group [19]. ICA is a computational method aiming at a separation of multivariate data into components (IC-factors, “sources”) that maximize the statistical independence. When following the ICA approach to IED identification, epileptic brain activity is a suitable representative of such an independent source. A limitation of this assumption is the increasingly recognized network aspect in genesis and propagation of epileptic activity and will be discussed below. In the ICA approach the IC-factor that codes epileptic activity best is manually selected on the basis of the temporal and spatial distribution of a set

of unequivocal IEDs. Contrary to single spike detection identification of IEDs based on IC-factors results in a continuous measure of the epileptic activity and thus provides more detailed and more objective information [20]. A principal advantage of the IC-based approach is the ability to model epileptic activity more physiologically, taking into account variation in amplitude, duration, and shape of IEDs, especially when high-resolution EEG is performed. Integration of individual amplitudes of IEDs in EEG/fMRI analysis has been recently reported to yield BOLD signal correlates that are more confined to the seizure onset zone (SOZ) [21, 19, 22, 23]. A good reliability of the IC-based approach has been reported to identify factors coding for the epileptic activity [24].

### b) Topographic based analysis

A novel approach proposed recently by Groullier et al. [25] is dedicated to EEG/fMRI recordings without visually detectable IEDs during EEG inside the scanner. In addition to the display of scalp EEG signals as a function of time, electrical activity can be represented by scalp voltage topographic maps (EEG maps). These topographic maps reflect the momentary activity of neuronal networks via the summation of post-synaptic cortical potentials over the whole brain. Changes in the activity of focal electrical brain generators influence the topography of these maps [26]. It has been shown that the topographic maps may reflect the electrical generators of focal epileptic activity [27]. These studies indicate that “the occurrence of these epilepsy-specific EEG maps in the resting EEG of individual patients represents an increase in the activity of the epileptic sources and could allow the detection of sub-threshold activity even in the absence of visually identifiable epileptic waveforms on the conventional EEG” [25]. The strength of the presence of these maps in the EEG recorded during functional MRI as a function of time was used as predictor for the hemodynamic changes in the epileptic network.

## 2.2. Hemodynamic changes linked to interictal epileptic activity

Most publications on EEG/fMRI were based on the assumption that IEDs are associated with a standard and predictable hemodynamic response and that hemodynamic changes occur time-locked to epileptic activity. The standard analysis model of fMRI assumes that following each spike or fluctuation of epileptic activity the BOLD signal changes according to a standard hemodynamic response function (HRF), defined and validated in brain activation studies in healthy subjects performing sensory or cognitive tasks [28]. Potential differences between patients, between different brain regions or between repeated individual recordings are

neglected, although HRF variability has been reported sizable [29]. In EEG/fMRI the majority of HR clearly diverging from the standard HRF were observed outside the SOZ in “distant BOLD correlates” and most likely represent effects of propagation [30]. As there is limited evidence of altered neurovascular coupling in the SOZ of epileptic brains, the use of the standard HRF with the delay of response maximum at approximately 6 s after the IED seems appropriate in most EEG/fMRI studies [28, 30, 31]. A second assumption in the analysis of HR is that the metabolic changes visualized on fMRI are representing exclusively epileptic neuronal activity. This might be not true.

### **2.2.1 HR at the SOZ**

The BOLD signal change linked to IEDs is variable, as indicated by various positive or negative BOLD correlates co-localizing to the SOZ in focal epilepsies [32, 13]. Explanations for this observation remain elusive. It is not clear whether the observed negative BOLD correlates reflect the effects of surround inhibition, impaired focal neurovascular coupling, large network influences resulting in a decreased metabolic rate or a vascular theft mechanism [32, 13]. Recently, it has been observed that BOLD changes can occur prior to the detection of interictal spikes detected on EEG [33]. These findings suggest that the metabolic (neuronal or glial) processes underlying spike-associated BOLD signal changes begin before electrical activity can be detected using scalp EEG [33, 34]. This observation has been further investigated by alternative modeling of the HR by temporally shifting the HRF function to the IEDs [35, 36] reporting pre-spike BOLD responses in the majority of investigated cases with focal epilepsy. The extent of BOLD correlates co-localizing with the SOZ in the pre-spike period is more focal and may be more specific than the HR to a simultaneous IEDs predictor or in the post-spike period. Hence, the analysis of HR occurring prior to IEDs on scalp spikes may, beyond potential pathophysiological insights be also of diagnostic relevance. Recent data from an animal study report absence of cortical epileptic activity in a region with HR preceding spikes suggesting an non-epileptic origin the observed hemodynamic phenomenon [37].

### **2.2.2 HR distant to the SOZ**

In the majority of simultaneous EEG/fMRI recordings in epilepsy HR are observed outside the area of the presumed SOZ, denominated „distant” or “remote” HR. The pathophysiology and clinical importance of such HRs have increasingly received attention in the past years. Both IEDs and seizures propagate (i.e. the pathological EEG patterns spread to distant areas) reflecting recruitment of neuronal activity in remote

brain areas [38, 39]. Although propagation of seizure activity may be well-defined, the propagation of epileptic activity occurring during seizure free periods is less well characterized. In focal epilepsies due to malformations of cortical development, distant BOLD correlates have been found in a variable distribution in cortical and subcortical structures [40]. Group analysis in homogeneous patient cohorts with temporal lobe epilepsies has reported a reproducible pattern of “distant” HR along structural pathways [41, 42]. The close overlay of the multi-focal pattern of HR and a cortical atrophy in mesio-temporal lobe epilepsy (MTLE) foster the hypothesis that the “distant” HR are not artifacts but rather represent a functionally and structurally characterized epileptic network involved in genesis and/or propagation of seizures (unpublished data). Distant BOLD correlates have also been characterized during the pre- and post-spike period in idiopathic generalized epilepsy (IGE), with spatial patterns typically resembling resting (or default) state networks of the brain (i.e. attention without specific activity) [43, 44]. Pathophysiological insights on the correlation between vigilance and epileptic activity, as it is clinically frequently observed, may disclose the understanding of large network influences on seizure generation. The spatial dispersion of whole brain HR in the pre- and post-spike period of two patients, suffering from IGE and focal epilepsy of temporal lobe origin, respectively, is further illustrated in two cases as follows:

#### **Illustrative case I**

A) 38 years old male with IGE presenting clinically generalized seizures, ictal and interictal generalized spike/wave pattern and no epileptogenic lesion on structural MRI. During simultaneous EEG/fMRI brief spike/wave discharges of a maximum duration of 3 s with bi-frontal dominance were recorded. Positive HR were found 10 s prior to the IEDs in the midline brainstem structures, evolving to a bilateral positive thalamic HR 8 s prior to the IEDs. Simultaneously to the IEDs and lasting for 10 s, a pattern of negative HR in the mesio-temporal, pontine and association cortices of the frontal, temporal and parietal lobe were delineated. The HR 10 s prior to IEDs in the brain stem corresponds potentially to hemodynamic alteration of the reticular system and may be involved in a modulation of vigilance known to precede IGE discharges. Following this reflection these HR would be of non-epileptic origin. The pattern of positive HR in the thalami and negative HR in the neocortex is considered typical for IGE. B) Scalp EEG recordings showing spike/wave discharges. C) Calculated IC-factor used for prediction of the HR.

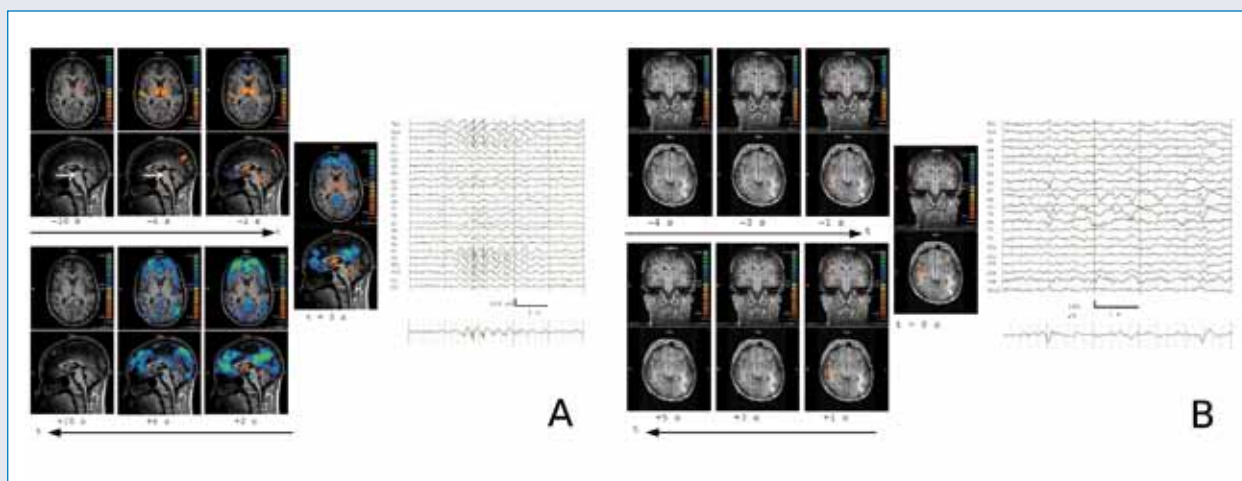


Figure 2: Illustrative Case I

### Illustrative case II

25 years old male with cryptogenic right temporal lobe epilepsy presenting an ictal semiology of acoustical hallucinations and secondary generalization, interictal right temporal spikes and no epileptogenic lesion on structural MRI. Here, already 4 s prior to isolated spikes temporal right on scalp EEG a focal positive HR in the lateral temporal lobe in the vicinity of Heschl's gyrus was present. The HR remained stable and focal for 9 s without clinical symptoms.

## 3. EEG/fMRI as clinical tool for presurgical epilepsy evaluation

### 3.1. Validation studies

Although combined EEG/fMRI studies have been conducted for 15 years up to now, evidence for clinical applications remains limited. Validation of EEG/fMRI as an alternative imaging technique is challenging as it has to be subjected to other available standards, ideally in large homogenous patient groups. Postoperative seizure freedom, in patients where the epileptogenic zone was successfully removed, represents the most clinically relevant form of validation. However, resected areas tend to extend beyond the epileptogenic zone and the SOZ, making it difficult to attribute the specificity of EEG/fMRI. Consequently, intracranial EEG recordings of seizures may be required to confirm inclusion of the SOZ. The limited spatial coverage of invasive EEG recordings is a potential drawback for method to method comparison. Recent studies have investigated the value of EEG/fMRI studies in the presurgical workup. One study aimed to attribute the potential role of EEG-fMRI

for clinical decision making in a cohort of patients who had previously been rejected for poorly localized epileptic focus or presumed multifocality [45]. About 14 percent of patients being initially no candidates for surgery were post hoc stratified for surgery. Another study that incorporated non-lesional frontal lobe epilepsies delineated the SOZ based on the results of simultaneous EEG/fMRI in 2 of 9 patients that subsequently underwent successful resection [46]. The co-localization of the most significant HR within the resected brain region (Peak activation, PA) has been repetitively related to good outcome in a limited number of patients [47, 15]. A recent study, reexamined the influence of the thresholding criterion used to determine HR to IEDs for the estimation of SOZ localization [48]. A newly introduced criterion based on a predefined extent of HR in the brain ("Fixed number of voxel", FAV) resulted in concordant localization of the SOZ to electroclinical data in 8 of 10 patients with good postsurgical outcome. Some limitations of established thresholding criteria as PA or the use of fixed thresholds (FWE) were renewed. (See Illustrative case III). Incorporation of scalp voltage topographic maps in patients without spikes during EEG/fMRI recordings resulted in the identification of HR in 78% of patients which were concordant to intracranial EEG/resected area [25]. Technical improvements of EEG/fMRI are nowadays targeted to incorporate EEG/fMRI in the workup of patients with MTLE by using the IC approach on the EEG [48, 19]. Most of the IEDs in the mesial temporal lobe have no correlate on visual scalp EEG and may thus erroneously be attributed to the baseline signature of the fMRI correlation. It could be demonstrated that epileptic activity extracted by an IC may partially overcome this limitation, thus making EEG/fMRI feasible in MTLE patients.

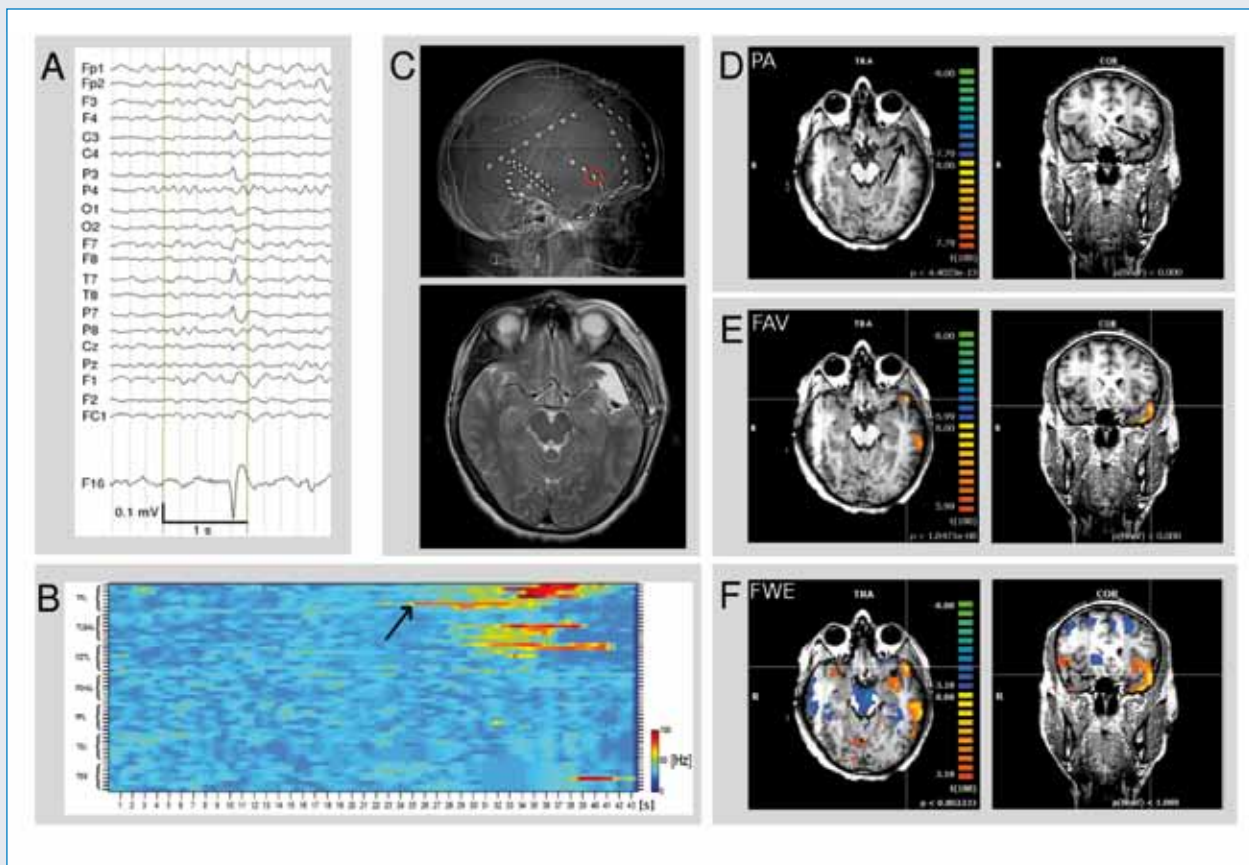


Figure 3: Illustrative Case II

### Illustrative case III

Patient with pharmaco-resistant non-lesional left lateral TLE. A - scalp EEG (average reference montage) and IC factor coding for the interictal spike with left temporal maximum. B - invasive EEG recording displaying high frequency oscillations on electrode TPL\_6 5 sec prior to clinical seizure onset and propagation on EEG. C - location of electrode TPL\_6 on the EEG implantation map (upper row) and postsurgical follow up MRI D (lower row) - Peak activation (PA) was located in the temporo-polar region (arrow). E - FAV criterion with temporo-lateral BOLD clusters in proximity to electrode TPL\_6. The distribution of BOLD clusters were used in the planning of the positioning of invasive EEG electrodes. F - FWE criterion discloses a widespread epileptic network.

### 3.2 Invasive EEG/fMRI

Simultaneous recordings of intracranial EEG and fMRI have been carried out recently following a strict safety protocol [49]. Even though the initial experiences seem encouraging and did not report any adverse effects, safety issues have to be further eluci-

dated. At least as long as the electrodes used for intracranial recordings lack approval for MRI by the manufacturers, the use of intracranial EEG/fMRI requires extremely careful ethical evaluation and the assessment of patients safety. Importantly, despite different waveforms and frequency characteristics, IEDs recorded from intracranial EEG can be modeled using a simple modeling approach similar to the one used for scalp EEG/fMRI. Intracranial EEG/fMRI demonstrated that BOLD signal changes matching the electrode contacts can be detected and hence key functional abnormalities of the epileptic brain can be monitored with this new technical approach [18].

### 3.3 EEG/fMRI during seizures

The vast majority of EEG/fMRI recordings are carried out in the interictal state. However, a large portion of diagnostic and therapeutic decisions are still based on ictal phenomena as seizure semiology or EEG patterns. Performing MRI during epileptic seizures has appreciable challenges and safety considerations. However, several EEG/fMRI studies in the ictal state have been made and were suitable for analysis [50-52, 14, 53]. Hyper-perfusion of the SOZ during seizures is established

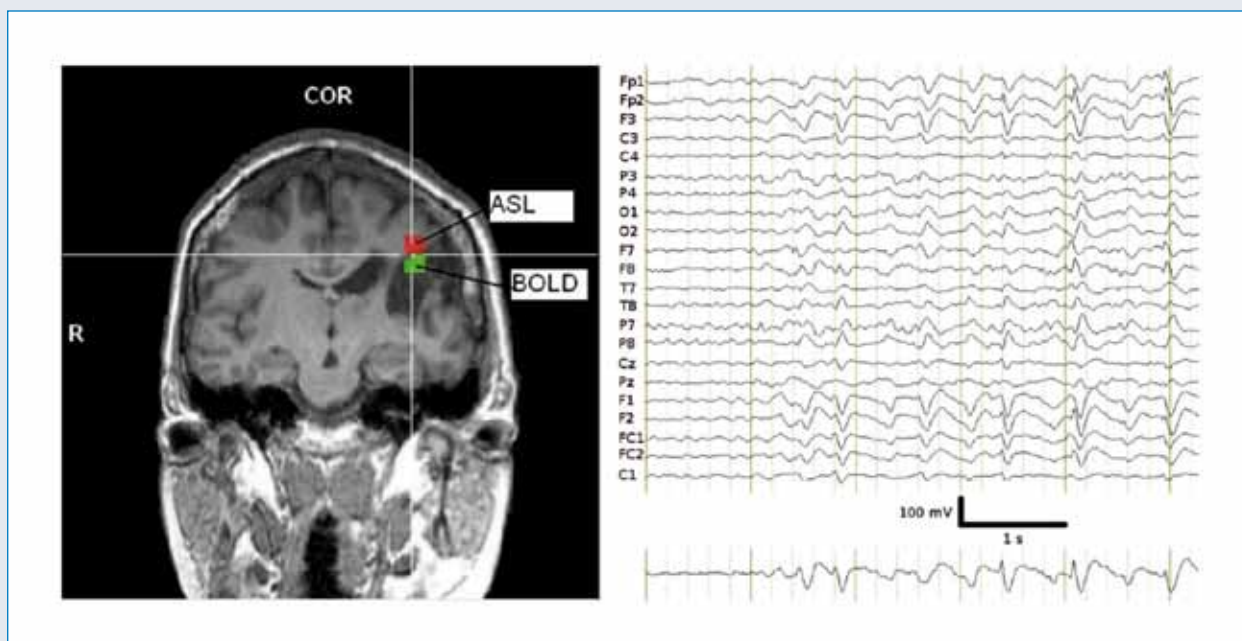


Figure 4: Illustrative Case III

since Penfield's experiments in 1933 and was consistently detected during ictal brain perfusion studies [54, 55]. Ictal EEG/fMRI recordings consistently show positive BOLD correlates encompassing the presumed SOZ. The intensity of the ictal neuronal and metabolic processes frequently result in widespread HR patterns, occasionally limiting the interpretability of EEG/fMRI recordings [56]. Illustrative case IV shows the tight spatial relation between the positive BOLD correlates adjacent to a chronic vascular epileptogenic lesion and the associated ictal hyper-perfusion. To date there is no evidence that the localization of HR in ictal EEG/fMRI recordings is more reliable in respect to the SOZ identification than in interictal recordings.

#### Illustrative case IV

Ictal EEG/fMRI during simple motor seizures - Left side: Structural T1 weighted MRI with chronic ischemic lesion in the territory of the left middle cerebral artery. Overlay of the maximum HR to epileptic EEG activity during simple motor seizures (BOLD in green) and the maximum of focal cerebral blood flow as measured by arterial spin labeling during an consecutive seizure (ASL in red). Right side: scalp EEG (average reference montage) and IC factor coding for the ictal epileptic activity with left frontal predominance during twitches of the right arm.

#### 4. Summary

Simultaneous EEG/fMRI recordings offer a unique approach of characterizing epileptic brain activity. Scalp EEG/fMRI is a non-invasive, safe and reproducible brain imaging technique. The underlying processes giving raise to epileptic EEG signal fluctuations and the associated hemodynamic changes on BOLD fMRI may not be completely identical and make interpretation of the EEG/fMRI results complex. The current state of research suggests that EEG/fMRI analysis results in a comparable sensitivity compared to PET and SPECT imaging [57, 58] to identify the SOZ. It may consequently be implemented as a complementary tool for presurgical evaluation of epilepsy patients. In addition, in the individual patient simultaneous EEG/fMRI may support the planning of intracranial EEG electrodes. Adding converging evidence to a clinical and EEG-derived hypothesis by non-invasive EEG/fMRI, may elude techniques that carry radiation exposure or, in selected cases, invasive EEG. From a scientific perspective, the technique provides a powerful opportunity to study functional changes in the entire epileptic brain aiming towards better understanding of the precise spatio-temporal pathophysiological mechanisms of epilepsy.

#### References

1. Ives JR, Warach S, Schmitt F et al. Monitoring the patient's EEG during echo planar MRI. *Electroencephalogr Clin Neurophysiol* 1993; 87: 417-420
2. Ogawa S, Lee TM, Kay AR, Tank DW. Brain magnetic resonance imaging with contrast dependent on blood oxygenation. *Proc Natl Acad Sci U S A*

- 1990; 87: 9868-9872
3. Allen PJ, Polizzi G, Krakow K et al. Identification of EEG events in the MR scanner: the problem of pulse artifact and a method for its subtraction. *Neuroimage* 1998; 8: 229-239
  4. Krakow K, Wieshmann UC, Woermann FG et al. Multimodal MR imaging: functional, diffusion tensor, and chemical shift imaging in a patient with localization-related epilepsy. *Epilepsia* 1999; 40: 1459-1462
  5. Lemieux L, Allen PJ, Franconi F et al. Recording of EEG during fMRI experiments: patient safety. *Magn Reson Med* 1997; 38: 943-952
  6. International Commission on Non-Ionizing Radiation Protection. Medical magnetic resonance (MR) procedures: protection of patients. *Health Phys* 2004; 87: 197-216
  7. Sienkiewicz Z. Rapporteur report: implications for exposure guidelines. *Prog Biophys Mol Biol* 2005; 87: 365-372
  8. Gotman J, Kobayashi E, Bagshaw AP et al. Combining EEG and fMRI: a multimodal tool for epilepsy research. *J Magn Reson Imaging* 2006; 23: 906-920
  9. Gotman J, Pittau F. Combining EEG and fMRI in the study of epileptic discharges. *Epilepsia* 2011; 52(Suppl 4): 38-42
  10. Allen PJ, Josephs O, Turner R. A method for removing imaging artifact from continuous EEG recorded during functional MRI. *Neuroimage* 2000; 12: 230-239
  11. Srivastava G, Crottaz-Herbette S, Lau KM et al. ICA-based procedures for removing ballistocardiogram artifacts from EEG data acquired in the MRI scanner. *Neuroimage* 2005; 24: 50-60
  12. Vanderperren K, De Vos M, Ramautar JR et al. Removal of BCG artifacts from EEG recordings inside the MR scanner: a comparison of methodological and validation-related aspects. *Neuroimage* 2010; 50: 920-934
  13. Salek-Haddadi A, Diehl B, Hamandi K et al. Hemodynamic correlates of epileptiform discharges: an EEG-fMRI study of 63 patients with focal epilepsy. *Brain Res* 2006; 1088: 148-166
  14. Tyvaert L, Hawco C, Kobayashi E et al. Different structures involved during ictal and interictal epileptic activity in malformations of cortical development: an EEG-fMRI study. *Brain* 2008; 131: 2042-2060
  15. Thornton R, Laufs H, Rodionov R et al. EEG correlated functional MRI and postoperative outcome in focal epilepsy. *J Neurol Neurosurg Psychiatry* 2010; 81: 922-927
  16. Alarcon G, Guy CN, Binnie CD et al. Intracerebral propagation of interictal activity in partial epilepsy: implications for source localisation. *J Neurol Neurosurg Psychiatry* 1994; 57: 435-449
  17. Tao JX, Ray A, Hawes-Ebersole S, Ebersole JS. Intracranial EEG substrates of scalp EEG interictal spikes. *Epilepsia* 2005; 46: 669-676
  18. Vulliemoz S, Carmichael DW, Rosenkranz K et al. Simultaneous intracranial EEG and fMRI of interictal epileptic discharges in humans. *Neuroimage* 2011; 54: 182-190
  19. Jann K, Wiest R, Hauf M et al. BOLD correlates of continuously fluctuating epileptic activity isolated by independent component analysis. *Neuroimage* 2008; 42: 635-648
  20. Hesse C, James C. Tracking epileptiform activity in the multichannel ictal EEG using spatially constrained independent component analysis. *Conf Proc IEEE Eng Med Biol Soc* 2005; 2: 2067-2070
  21. Formaggio E, Storti SF, Bertoldo A et al. Integrating EEG and fMRI in epilepsy. *Neuroimage* 2011; 54: 2719-2731
  22. Levan P, Tyvaert L, Gotman J. Modulation by EEG features of BOLD responses to interictal epileptiform discharges. *Neuroimage* 2010; 50: 15-26
  23. Marques JP, Rebola J, Figueiredo P et al. ICA decomposition of EEG signal for fMRI processing in epilepsy. *Hum Brain Mapp* 2009; 30: 2986-2996
  24. Urrestarazu E, Iriarte J, Artieda J et al. Independent component analysis separates spikes of different origin in the EEG. *J Clin Neurophysiol* 2006; 23: 72-78
  25. Grouiller F, Thornton RC, Groening K et al. With or without spikes: localization of focal epileptic activity by simultaneous electroencephalography and functional magnetic resonance imaging. *Brain* 2011; 134: 2867-2886
  26. Michel CM, Lantz G, Spinelli L et al. 128-channel EEG source imaging in epilepsy: clinical yield and localization precision. *J Clin Neurophysiol* 2004; 21: 71-83
  27. Ebersole JS, Wade PB. Spike voltage topography and equivalent dipole localization in complex partial epilepsy. *Brain Topogr* 1990; 3: 21-34
  28. Glover GH. Deconvolution of impulse response in event-related BOLD fMRI. *Neuroimage* 1999; 9: 416-429
  29. Aguirre GK, Zarahn E, D'Esposito M. The variability of human, BOLD hemodynamic responses. *Neuroimage* 1998; 8: 360-369
  30. Re-examination of the evidence for low-dimensional, nonlinear structure in the human electroencephalogram
  31. Moeller F, LeVan P, Gotman J. Independent component analysis (ICA) of generalized spike wave discharges in fMRI: comparison with general linear model-based EEG-fMRI. *Hum Brain Mapp* 2011; 32: 209-217
  32. Kobayashi E, Bagshaw AP, Grova C et al. Negative BOLD responses to epileptic spikes. *Hum Brain Mapp* 2006; 27: 488-497
  33. Hawco CS, Bagshaw AP, Lu Y et al. BOLD changes occur prior to epileptic spikes seen on scalp EEG. *Neuroimage* 2007; 35: 1450-1458
  34. Makiranta M, Ruohonen J, Suominen K et al. BOLD signal increase precedes EEG spike activity – a dynamic penicillin induced focal epilepsy in deep anesthesia. *Neuroimage* 2005; 27: 715-724
  35. Jacobs J, Levan P, Moeller F et al. Hemodynamic changes preceding the interictal EEG spike in patients with focal epilepsy investigated using simultaneous EEG-fMRI. *Neuroimage* 2009; 45: 1220-1231
  36. Moeller F, Siebner HR, Wolff S et al. Changes in activity of striato-thalamo-cortical network precede generalized spike wave discharges. *Neuroimage* 2008; 39: 1839-1849
  37. Osharina V, Ponchel E, Aarabi A et al. Local haemodynamic changes preceding interictal spikes: a simultaneous electrocorticography (ECoG) and near-infrared spectroscopy (NIRS) analysis in rats. *Neuroimage* 2010; 50: 600-607
  38. Spencer SS. Neural networks in human epilepsy: evidence of and implications for treatment. *Epilepsia* 2002; 43: 219-227
  39. Weder BJ, Schindler K, Loher TJ et al. Brain areas involved in medial temporal lobe seizures: a principal component analysis of ictal SPECT data. *Hum Brain Mapp* 2006; 27: 520-534
  40. Federico P, Archer JS, Abbott DF, Jackson GD. Cortical/subcortical BOLD changes associated with epileptic discharges: an EEG-fMRI study at 3 T. *Neurology* 2005; 64: 1125-1130
  41. Kobayashi E, Grova C, Tyvaert L et al. Structures involved at the time of temporal lobe spikes revealed by interindividual group analysis of EEG/fMRI data. *Epilepsia* 2009; 50: 2549-2556
  42. Laufs H, Hamandi K, Salek-Haddadi A et al. Temporal lobe interictal epileptic discharges affect cerebral activity in „default mode“ brain regions. *Hum Brain Mapp* 2007; 28: 1023-1032
  43. Gotman J, Grova C, Bagshaw A et al. Generalized epileptic discharges show thalamocortical activation and suspension of the default state of the brain. *Proc Natl Acad Sci USA* 2005; 102: 15236-15240
  44. Jann K, Dierks T, Boesch C et al. BOLD correlates of EEG alpha phase-locking and the fMRI default mode network. *Neuroimage* 2009; 45: 903-916



45. Zijlmans M, Huiskamp G, Hersevoort M et al. EEG-fMRI in the preoperative work-up for epilepsy surgery. *Brain* 2007; 130: 2343-2353
46. Moeller F, Tyvaert L, Nguyen DK et al. EEG-fMRI: adding to standard evaluations of patients with nonlesional frontal lobe epilepsy. *Neurology* 2009; 73: 2023-2030
47. Lazeyras F, Blanke O, Perrig S et al. EEG-triggered functional MRI in patients with pharmacoresistant epilepsy. *J Magn Reson Imaging* 2000; 12: 177-185
48. Hauf M, Jann K, Schindler K et al. Localizing seizure-onset zones in pre-surgical evaluation of drug-resistant epilepsy by EEG/fMRI: Effectiveness of alternative thresholding strategies. *AJNR Am J Neuroradiol* 2012; accepted
49. Carmichael DW, Thornton JS, Rodionov R et al. Feasibility of simultaneous intracranial EEG-fMRI in humans: a safety study. *Neuroimage* 2010; 49: 379-390
50. Chaudhary UJ, Duncan JS, Lemieux L. Mapping hemodynamic correlates of seizures using fMRI: A review. *Hum Brain Mapp* 2011; Nov 14. doi: 10.1002/hbm.21448. [Epub ahead of print]
51. LeVan P, Tyvaert L, Moeller F, Gotman J. Independent component analysis reveals dynamic ictal BOLD responses in EEG-fMRI data from focal epilepsy patients. *Neuroimage* 2010; 49: 366-378
52. Thornton RC, Rodionov R, Laufs H et al. Imaging haemodynamic changes related to seizures: comparison of EEG-based general linear model, independent component analysis of fMRI and intracranial EEG. *Neuroimage* 2010; 53: 196-205
53. Tyvaert L, Levan P, Dubeau F, Gotman J. Noninvasive dynamic imaging of seizures in epileptic patients. *Hum Brain Mapp* 2009; 30: 3993-4011
54. Hauf M, Slotboom J, Nirkko A et al. Cortical regional hyperperfusion in nonconvulsive status epilepticus measured by dynamic brain perfusion CT. *AJNR Am J Neuroradiol* 2009; 30: 693-698
55. Hauf M, Wiest R, Nirkko A et al. Dissociation of epileptic and inflammatory activity in Rasmussen Encephalitis. *Epilepsy Res* 2009; 83: 265-268
56. Kobayashi E, Hawco CS, Grova C et al. Widespread and intense BOLD changes during brief focal electrographic seizures. *Neurology* 2006; 66: 1049-1055
57. Knowlton RC. Multimodality imaging in partial epilepsies. *Curr Opin Neurol* 2004; 17: 165-172
58. Kurian M, Spinelli L, Delavelle J et al. Multimodality imaging for focus localization in pediatric pharmacoresistant epilepsy. *Epileptic Disord* 2007; 9: 20-31

**Address for correspondence:**

**Dr. med. Martinus Hauf**

**Support Center of Advanced Neuroimaging (SCAN)**

**Institute of Diagnostic and Interventional Neuroradiology**

**Inselspital, Bern University Hospital**

**CH 3010 Bern**

**Phone 0041 31 632 26 55**

**Fax 0041 31 632 48 72**

**Martinus.Hauf@insel.ch**