

*Roderick Duncan, Lead Clinician, West of Scotland
Regional Epilepsy Service, Southern General Hospital,
Glasgow, Scotland*

Summary

The occurrence of changes in cerebral perfusion during seizures has been known for a long time^[1] but the use of ictal and postictal SPECT in focal epilepsy dates from the early eighties. The development, initially of HMPAO, then of ECD, has allowed the imaging of changes in brain perfusion patterns during and soon after seizures.

Epileptologie 2004; 21: 105 – 108

Iktales SPECT bei fokaler Epilepsie

Das Auftreten von zerebralen Durchblutungsveränderungen während Anfällen ist seit langer Zeit bekannt, aber die iktales und postiktalen SPECT-Untersuchungen in fokaler Epilepsie werden erst seit den frühen 80er Jahren angewandt. Die Entwicklung von HMPAO-, später auch von ECD, erlaubte die Visualisierung von Durchblutungsveränderungen im Gehirn während und direkt nach Anfällen.

SPECT ictale dans l'épilepsie focale

La survenue de changements dans la perfusion cérébrale lors des crises épileptiques est connue de longue date, toutefois l'utilisation de SPECT ictal et interictal dans les épilepsies focales n'a été introduite que depuis les années quatre-vingt. Le développement d'abord du SPECT à l'HMPAO puis à l'ECD a permis de mettre en évidence les changements perfusionnels dans le cerveau pendant et après les crises.

The ictal SPECT method

The tracer HMPAO^[2] is a lipophilic compound, which crosses the blood brain barrier and cell membranes freely. After intravenous injection, it distributes in brain substantially on first pass. Once inside the neurone, it is converted into a hydrophilic compound, which is trapped inside the cell membrane. Therefore, the distribution of the compound and radionuclide with which it is labelled (99mTc in this case) remains stable for many hours after injection. Effectively, this means that an image acquisition carried out at some time after the injection will show the pattern of perfusion that existed at the time of the injection. All that requires to be done at the time of the seizure is to give the injection. The acquisition can then wait until the patient has recovered and can easily lie still in the scanner. ECD^[3] works in a similar manner, although there are some significant differences between the images produced by the two tracers (see below).

An assumption underlies the use of HMPAO or ECD SPECT in focal seizures: that changes in perfusion reflect changes in neuronal activity. Most data suggest that this is the case, but the relationship may not be entirely straightforward. For example, HMPAO uptake underestimates perfusion at high flow rates^[4], and indeed, HMPAO and ECD uptake patterns are not the same (ECD relatively underestimates perfusion in the mesial temporal cortex and in the mesial occipital cortex). Nonetheless, most data suggest that in most circumstances increased uptake of both tracers represents increased neuronal activity, and vice versa. The baseline interictal scan may of course be affected by changes in anatomy due to the underlying pathology, but ictal modifications of perfusion do not appear to be correlated directly with any given type of lesion.

The important limiting factors of SPECT data relate to sampling errors and spatial resolution.

Ictal SPECT has a sampling error in time, which is determined by tracer uptake rate (**figure 1**). The image that is obtained is that of the blood flow pattern during the uptake period. That period begins approximately fifteen seconds after the injection, and goes on for forty seconds for HMPAO (a little longer for ECD). Nothing that happens outside that time period will be reflected in the final image. This may be usefully contrasted with the sampling error in time of EEG in recording a seizure,

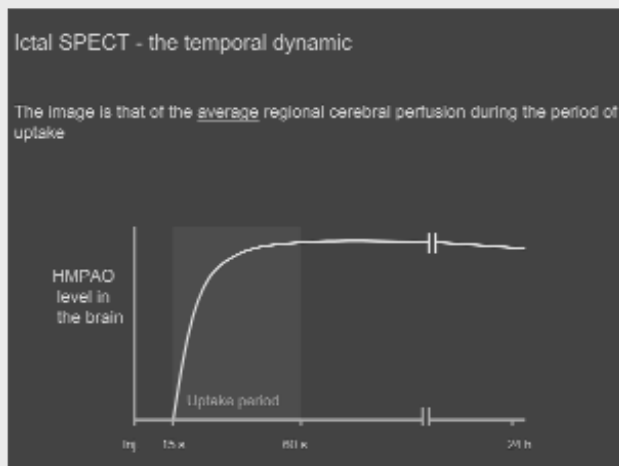


Figure 1. Graphic illustration of HMPAO uptake in the brain vs. time after injection.

which is effectively zero.

The temporal resolution of the image is also determined by the uptake period of the tracer. The image is effectively of the average perfusion pattern during the uptake period. If, for example, there is an area of high perfusion in the brain, the intensity of signal on the image is determined both by the duration of the high perfusion during uptake (it may last for all or part of the uptake period), and by its intensity. EEG has a temporal resolution in the order of milliseconds.

SPECT does not usually have a significant sampling error in space, as the whole of the brain is included in the 3-D dataset. The spatial resolution of the SPECT image is largely determined by the quality and design of the scanner itself, though other factors may be important. Most significantly, a high overall signal level will as a rule give better spatial resolution. This means that, up to a point, an increased tracer dose will give a better quality image, as will a shorter time between injection and acquisition, and a longer acquisition time.

Perfusion changes during and after temporal lobe seizures

Most data relating to the sensitivity and specificity of ictal SPECT relate to seizures originating in the mesial temporal lobe. Such seizures are common, and are relatively long, so are relatively easy to apply the technique to.

Early studies^[5-9] quickly identified a clear and typical sequence of changes in perfusion pattern that takes

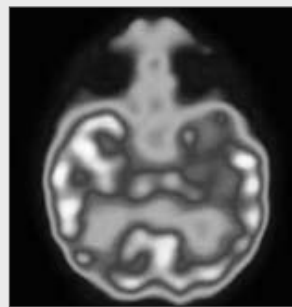


Figure 2. Right mesial temporal lobe seizure. Injection of HMPAO 45 seconds into the ictal discharge. Image shows a single axial slice in the plane of the long axis of the temporal lobe. There is hyperperfusion of the whole right temporal lobe.

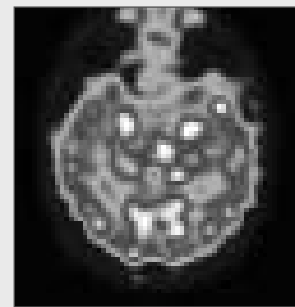


Figure 3. Left mesial temporal lobe seizure, showing bilateral changes on postictal SPECT. Injection of HMPAO was 60 seconds after termination of the ictal discharge. Image shows a single axial slice in the plane of the long axis of the temporal lobe. There is bilateral hypoperfusion of the temporal lobes with small foci of persisting hyperperfusion in the mesial temporal cortex on both sides.

place during and after mesial temporal lobe seizures. During the seizure, the whole temporal lobe is hyperperfused (**figure 2**). This persists until the discharge stops, and probably for a short time after if the discharge is of short duration. In the early postictal phase, perfusion in the lateral temporal lobe falls rapidly, leaving hyperperfusion of the mesial temporal cortex (**figure 3**). As the postictal phase progresses, the perfusion in the mesial temporal cortex also drops, and the whole temporal lobe is hypoperfused. This gradually recovers back to baseline, over a period that may be as long as several hours but is more typically several minutes.

If the seizure discharge is prolonged, the change from the ictal to the postictal pattern takes place before the termination of the ictal discharge, probably around 90 seconds from seizure onset.

While ictal SPECT has high sensitivity and specificity in temporal lobe seizures, both parameters diminish with time into the postictal period. At 1 minute after the end of the seizure discharge, over 90% of patients show persisting perfusion changes, but this does diminish rapidly after a few minutes. What is more limiting for postictal SPECT is that approximately 20% of patients show bilateral change (**figure 3**), giving some indication that the epilepsy is temporal, but no indication as to which side (in our experience, lateralisation based on the side that shows the most intense changes is not reliable).

The above changes in perfusion in the temporal lobe may be associated with changes elsewhere in the brain. These changes include reduction in perfusion in regions

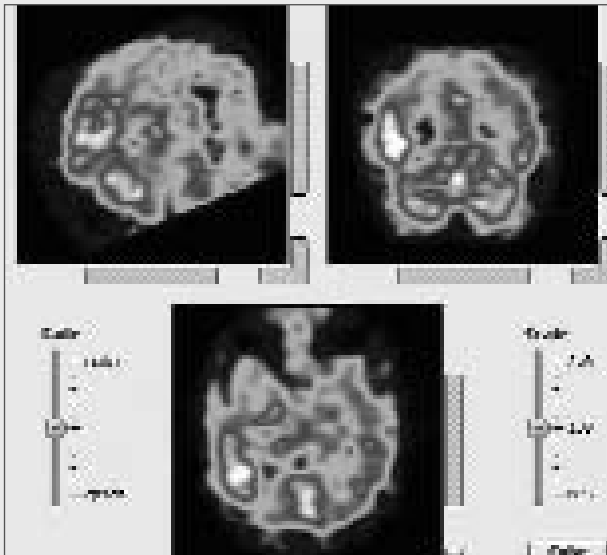


Figure 4. Seizure originating in the right Temporo-Parieto-Occipital junction (TPOJ) area. Injection of HMPAO 35 seconds into the ictal discharge. The image shows correlated sagittal, coronal and axial views. There is intense hyperperfusion of the right TPOJ area. Much of the rest of the cortical mantle is hypoperfused (bilaterally), especially the right temporal lobe, hence the relatively poor quality of the image.

of the cortical mantle not directly involved in seizure activity, as well as increases in perfusion in the insula and in subcortical structures such as the basal ganglia and thalamus. Hyperperfusion of the basal ganglia correlates with contralateral tonic posturing of the upper limb [7].

There is little information on anterior lateral temporal lobe seizures, but what exists suggests an ictal increase in perfusion which involves the whole temporal lobe but which is predominant in the lateral cortex.

Perfusion changes during frontal lobe seizures

There are less data in the literature regarding SPECT in frontal lobe seizures [10-13]. As one might expect, the range of changes in perfusion pattern is broad, and the changes seen appear to vary with the intralobar localisation. The accuracy of such localisation has not been extensively evaluated. Associated increases in perfusion in subcortical structures and in the cerebellum are common. Basal ganglia and thalamic hyperperfusion may be ipsilateral, contralateral or bilateral. Hyperperfusion of the cerebellum is usually contralateral to hyperactivity in the motor cortex. Decreases in perfusion of the cortical mantle are usually ipsilateral.

Postictal injection does not usually show useful changes after frontal lobe seizures.

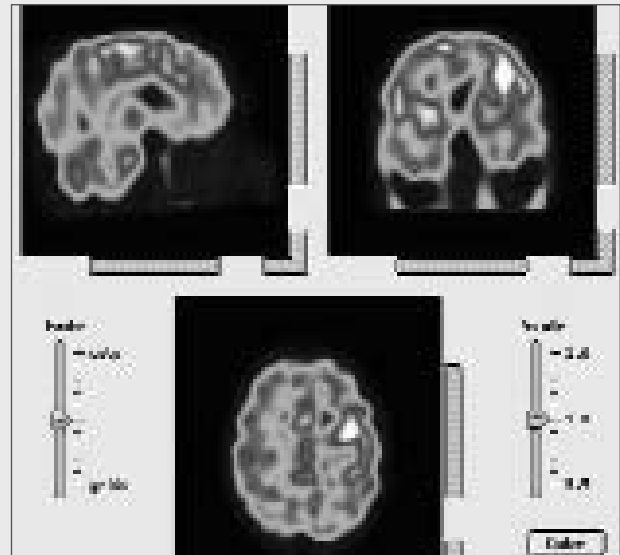


Figure 5. Seizure originating near Broca's area. Injection of HMPAO 15 seconds into the ictal discharge. The image shows correlated sagittal, coronal and axial views. There is hyperperfusion adjacent to Broca's area.

Seizures originating in the posterolateral cortex and mesial occipital lobe

It is convenient to consider together the posterior lateral temporal cortex, the area surrounding the temporo-parieto-occipital junction (TPOJ), the lateral occipital cortex, and the mesial occipital cortex, as the ictal SPECT findings appear to be analogous.

The core finding is of hyperperfusion in the area of the epileptogenic zone [14-17], wherever that lies. This may or may not be accompanied by hyperperfusion of the ipsilateral temporal lobe, (presumably due to forward propagation of the seizure discharge).

In the postero-lateral cortex, the hyperperfusion may be intense and, in that event, may be surrounded by ictal hypoperfusion. When the epileptogenic zone is at the TPOJ, there may also be a small area of hyperperfusion at the contralateral TPOJ [15]. If the ipsilateral temporal lobe is involved, the changes may resemble those seen in the ictal or in the postictal phase of a mesial temporal lobe seizure [15,16].

Importantly, changes in the temporal lobe may last into the postictal phase, after hyperperfusion of the epileptogenic zone has resolved. Therefore, postictal SPECT is not able to reliably distinguish between mesial temporal seizures and seizures originating in the posterolateral cortex.

Analysis of images

In most centres, analysis of images and assessment of per-ictal changes is primarily visual. SISCOM (subtracted ictal SPECT with coregistration of MRI^[18]) allows coregistration of SPECT data with MRI and subtraction of per-ictal and interictal images. Some reports suggest that it may provide better information than simple visual analysis, but the author's experience has failed to reproduce reported results. Statistical parametric mapping^[19] allows statistical comparison of a perfusion pattern with a normal database, and has proved successful in interpretation of PET and MRI functional data. It is not yet able to provide a method for statistically comparing two images, though per-ictal and interictal images can be analysed separately. The results may be misleading if large volumes of the brain are abnormal, especially if both hypoperfusion and hyperperfusion are present, as may be the case during seizures.

The practical use of ictal SPECT

The practicalities of ictal SPECT to some extent limit its use^[20]. Before tracer uptake begins, the seizure has to be recognized, the tracer must be given and must reach the brain. This means that most seizures of less than 30 seconds duration are not possible to capture (unless they can be induced), even when the tracer is premixed.

Local radioprotection rules may affect how ictal SPECT is used. In some countries, it is mandatory to use a premixed tracer (e.g. where mixing is not allowed on the monitoring unit). ECD is stable over several hours and may be used in this way. HMPAO is also available in stabilized form.

Whatever tracer is used, it is important that it be used consistently, as the patterns of uptake differ. This may cause problems in reporting (e.g. if the reporting doctor is accustomed to the normal pattern for one tracer, and then has to interpret images made using the other), and in assessing interictal – per-ictal changes.

References

1. Gibbs FA, Lennox WG, Gibbs EL. Cerebral blood flow preceding and accompanying seizures in man. *Archives of Neurology and Psychiatry* 1934; 32: 257-272
2. Andersen AR, Friberg H, Schmidt JF, Hasselbach SG. Quantitative measurements of blood flow using SPECT and Tc99m HMPAO compared to Xenon 133. *J Cereb Blood Flow Metab* 1988; 8: 69-81
3. Friberg L, Andersen AR, Lassen NA et al. Retention of 99mTc Bisicate after intracarotid injection. *J Cereb Blood Flow Metab* 1994; 14: 19-27
4. Duncan R, Patterson J, Macrae IM. HMPAO as a regional cerebral blood flow tracer at high flow levels. *J Nucl Med* 1996; 37: 661-664
5. Rowe CC, Berkovic SF, Sia STB et al. Localisation of epileptic foci with postictal single photon emission computed tomography. *Ann Neurol*

1989; 26: 600-668

6. Newton MR, Berkovic SF, Austin MC et al. Postictal switch in blood flow distribution and temporal lobe seizures. *J Neurol Neurosurg Psychiatry* 1992; 55: 891-894
7. Newton MR, Berkovic SF, Austen MC. Dystonia, clinical lateralisation and regional blood flow changes in temporal lobe seizures. *Neurology* 1992; 42: 371-377
8. Harvey AS, Bowe JM, Hopkins JJ et al. Ictal 99mTc HMPAO single photon emission computed tomography in children with temporal lobe epilepsy. *Epilepsia* 1993; 34: 869-877
9. Duncan R, Patterson J, Roberts R et al. Ictal/postictal SPECT in the presurgical localisation of complex partial seizures. *J Neurol Neurosurg Psychiatry* 1993; 56: 141-148
10. Marks DA, Katz A, Hoffer P, Spencer SS. Localisation of extratemporal epileptic foci during ictal single photon emission computed tomography. *Ann Neurol* 1992; 32: 250-253
11. Harvey AS, Hopkins JJ, Bowe JM et al. Frontal lobe epilepsy: clinical seizure characteristics and localisation with ictal 99mTc HMPAO SPECT. *Neurology* 1993; 43: 1966-1980
12. Newton MR, Berkovic SF, Austin MC et al. SPECT in the localisation of extratemporal and temporal seizure foci. *J Neurol Neurosurg Psychiatry* 1995; 59: 26-30
13. Duncan R, Patterson J, Hadley DM, Roberts R. Ictal regional cerebral blood flow in frontal lobe seizures. *Seizure* 1997; 6: 393-401
14. Ho SS, Berkovic SF, Newton MR et al. Ictal 99mTc HMPAO SPECT findings in parietal lobe epilepsy. *Epilepsia* 1993; 34: 112
15. Duncan R, Rahi S, Bernard AM et al. Ictal cerebral blood flow in seizures originating in the posterolateral cortex. *J Nucl Med* 1996; 37: 1946-1951
16. Duncan R, Patterson J, Hadley D et al. Ictal SPECT in occipital lobe seizures. *Epilepsia* 1997; 38: 839-843
17. Sturm JW, Newton MR, Chinvarun Y et al. Ictal SPECT and interictal PET in the localisation of occipital lobe epilepsy. *Epilepsia* 2000; 41: 463-466
18. O'Brien TJ, So EL, Mullan BP et al. Subtraction SPECT co-registered to MRI improves postictal SPECT localisation of seizure foci. *Neurology* 1999; 52: 137-146
19. Friston JJ, Frith CD, Liddee PF et al. The relationship between global and local changes in PET scans. *J Cereb Blood Flow Metab* 1990; 10: 458-466
20. Duncan R. Single photon emission computed tomography in focal epilepsies. In: Oxbury J, Polkey C, Duchowney M (eds): *Intractable Focal Epilepsy*. London: WB Saunders, 2000: 324-325

Address for correspondence:

Roderick Duncan, MD, PhD, FRCP

Lead Clinician

West of Scotland Regional Epilepsy Service

Southern General Hospital

Glasgow G51 4TF

Scotland

Tel. 0044 1412 01 2517

Fax 0044 1412 01 2509

r.duncan@clinmed.gla.ac.uk