

Olaf Blanke^{1,2} and V Castillo²

¹Laboratory of Cognitive Neuroscience, Brain Mind Institute, Ecole Polytechnique Fédérale de Lausanne (Swiss Federal Institute of Technology), Lausanne

²Department of Neurology, University Hospital, Geneva

Summary

Autoscopic phenomena are complex illusory perceptions of one's body during which human subjects experience a second own body or double in their environment. Although doubles may also be felt or heard autoscopic phenomena most commonly refer to visual doubles, and consist of autoscopic hallucinations, out-of-body experiences, and heautoscopy.

Recently, many neurological reports have focussed on only one type of autoscopic phenomena: out-of-body experiences. Here we review neurological data on autoscopic hallucinations and present a case during complex partial seizures due to neurocysticercosis.

Epileptologie 2007; 24: 90 – 95

Key words: Neurology, self, body, neuroimaging, epilepsy

Klinische Bildgebungsverfahren bei Epilepsiepatienten mit autoskopischen Halluzinationen und ausserkörperlichen Erfahrungen

Autoskopische Erfahrungen sind komplexe Illusionen, die den eigenen Körper betreffen und sich durch die Wahrnehmung eines zweiten eigenen Körpers oder Doppelgängers, der im extrapersonalen Raum wahrgenommen wird, definieren. Autoskopische Erfahrungen beziehen sich meistens auf visuelle Doppelgänger, obwohl der Doppelgänger auch nur gefühlt oder gehört werden kann. Es gibt drei unterschiedliche Formen von visuellen autoskopischen Erfahrungen: autoskopische Halluzinationen, ausserkörperliche Erfahrungen und Heautoskopie. In der letzten Zeit sind einige detaillierte neurologische Berichte über Patienten mit ausserkörperlichen Erfahrungen veröffentlicht worden. Hier stellen wir deshalb eine Übersicht über neurologische Patienten mit autoskopischen Halluzinationen vor, sowie die detaillierte Beschreibung einer Patientin, die unter autoskopischen Halluzinationen aufgrund komplex-partieller epileptischer Anfälle bei Neurozystizerkose litt.

Schlüsselwörter: Neurologie, Selbst, Körper, Bildgebung, Epilepsie

Les techniques de l'imagerie clinique pour les patients épileptiques avec hallucinations autoscopiques et expériences extracorporelles

Les expériences autoscopiques sont des illusions complexes qui concernent le propre corps d'une personne et qui se définissent par la perception d'un deuxième corps propre ou d'un double qui est ressenti dans l'espace extrapersonnel. Les expériences autoscopiques se rapportent généralement à des doubles visuels, mais ce double peut aussi être seulement ressenti ou entendu. Il existe trois formes distinctes d'expériences visuelles autoscopiques : les hallucinations autoscopiques, les expériences extracorporelles et l'heautoscopie. Quelques rapports neurologiques détaillés sur des personnes ayant connu des expériences extracorporelles ont été publiés ces derniers temps. C'est pourquoi nous présentons ici une synopsis de patients neurologiques avec des hallucinations autoscopiques, ainsi que la description détaillée d'une patiente qui souffrait d'hallucinations autoscopiques lors de crises complexes partielles associées à une neurocysticercose.

Mots-clés : Neurologie, perception du soi, corps, imagerie, épilepsie

Introduction

Autoscopic phenomena are complex illusory perceptions of one's body during which human subjects experience a second own body or double in their environment. Autoscopic phenomena most commonly refer to visual doubles [1], although doubles may also be felt or heard [2 - 4]. Autoscopic phenomena and doubles have fascinated mankind from time immemorial. Three main visual forms of autoscopic phenomena have been described that can be separated based on phenomenological and anatomical criteria [5]: out-of-body experience, autoscopic hallucination, and heautoscopy [6, 7, 1]. During an out-of-body experience people feel

that their "self", or center of awareness, is located outside of the physical body and somewhat elevated. It is from this elevated extracorporeal location that the subjects experience seeing their body and the world [8, 7, 1]. The subjects' reported perceptions are organized in such a way as to be consistent with this elevated visuo-spatial perspective. The following example from Lunn

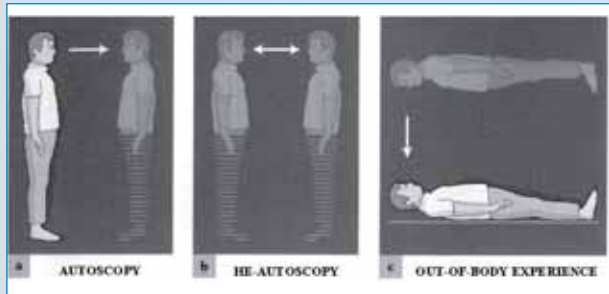


Figure 1: Phenomenology of autoscopic phenomena. In this figure the phenomenology of autoscopic hallucinations (left), heautoscopy (middle) and out-of-body experiences (right) is represented schematically. The experienced position and posture of the patient is indicated by a full body and the hallucinated position of the "disembodied" body (OBE) or double's body (AH, HAS) as a transparent body. The finding that autoscopic hallucinations and heautoscopy were mainly reported from a sitting/standing position and out-of-body experiences in a supine position is integrated into the figure. The experienced visuo-spatial perspective during the autoscopic phenomenon is indicated by the arrow pointing away from the location in space from which the patient has the impression to see from (autoscopic hallucination: from the physical body; out-of-body experiences: from a disembodied body or location; heautoscopy: alternating or simultaneous fashion between physical and autoscopic body; modified from Blanke [1].

([9], case 1) illustrates what individuals commonly experience during an out-of-body experience: "Suddenly it was as if he saw himself in the bed in front of him [...] as if he were floating in space below the ceiling in the corner facing the bed from where he could observe his own body in the bed. [...] he saw his own completely immobile body in the bed." An out-of-body experience can thus be defined as the presence of the following three phenomenological elements: the feeling of being outside one's physical body (disembodiment); the presence of a distanced and elevated visuo-spatial perspective; and the seeing of one's own body (autoscopy) from this elevated perspective. These three aspects are shown graphically in **Figure 1**.

During an autoscopic hallucination people experience seeing a double of themselves in extrapersonal space without the experience of leaving one's body (no disembodiment). As compared to out-of-body experiences, individuals with autoscopic hallucination experience to see the world from their habitual visuo-spatial perspective and experience their "self", or center of awareness inside their physical body (**Figure 1**). The

following example of an autoscopic hallucination is taken from Kölmel ([10], case 6). "[. . .] the patient suddenly noticed a seated figure on the left. "It wasn't hard to realize that it was I myself who was sitting there. I looked younger and fresher than I do now. My double smiled at me in a friendly way". The third form of autoscopic phenomena is heautoscopy, which is an intermediate form between autoscopic hallucination and out-of-body experience. These individuals also have the experience of seeing a double of themselves in extrapersonal space. However, it is difficult for the subject to decide whether he is disembodied or not and whether the self is localized within the physical body or in the illusory body that is seen [1]. In addition, the subjects often report to see, in an alternating or simultaneous fashion, from different visuo-spatial perspectives (physical body, double's body) as reported by patient 2B in Blanke et al. ([1], see **Figure 1**). "[The patient] has the immediate impression as if she were seeing herself from behind herself. She felt as if she were "standing at the foot of my bed and looking down at myself." Yet, [. . .], the patient also has the impression to "see" from her physical [or bodily] visuo-spatial perspective, which looked at the wall immediately in front of her. Asked at which of these two positions she thinks herself to be, she answered that "I am at both positions at the same time".

With respect to their etiology, autoscopic phenomena have been reported in various generalized and focal diseases of the central nervous system. Generalized neurological etiologies include cerebral infections such as meningitis and encephalitis, intoxications, as well as generalized epilepsies [1]. Autoscopic phenomena following focal brain damage also emerge from a large variety of etiologies including most often focal epilepsy [8], traumatic brain damage [11], and migraine [12], vascular brain damage [10], neoplasia [11], dysembryoblastic neuroepithelial tumor [1] and arteriovenous malformation [8]. Regarding their underlying anatomy, autoscopic phenomena of focal origin primarily implicate posterior brain regions and with respect to lobar anatomy most studies found the temporal, parietal, or occipital lobe to be involved [13, 11, 9, 8, 1]. Some of these authors have either suggested a predominance of temporal lobe involvement [8, 6], a predominance of parietal lobe involvement [14, 13], or no brain localization at all [15]. Menninger-Lerchenthal [14] speculated on different anatomical substrates for the different autoscopic phenomena, suggesting that autoscopic hallucinations originate at the junction of the parietal and occipital lobe (junction of Brodmann's areas 39, 40, and 19), heautoscopy from the angular and supramarginal gyrus (Brodmann's areas 40 and 41), and out-of-body experiences from the superior parietal lobule (Brodmann's area 7). These anatomical dissociations have been partly confirmed by Blanke et al. [1] showing that autoscopic phenomena might be related to damage to the temporo-parietal junction although no

lesion analysis was carried out for each of the three forms of autoscopic phenomena. With regard to predominant hemispheric involvement the reported data are quite divergent as well. Some authors found no hemispheric predominance for autoscopic phenomena [13, 8, 16], while others have suggested a right hemispheric predominance for autoscopic phenomena [14, 6, 5]. Despite the description of over 100 cases in the neurological literature [17] and despite their relevance to neurological and neurobiological models of self and self consciousness [18] only few cases with sufficient clinical detail have been reported. Only more recently, autoscopic phenomena have received greater interest from neurologists [8, 2, 5, 7, 19, 1, 17]. This is surprising when looking at the large number of studies investigating illusory own body perceptions that are restricted to certain body parts such as phantom limbs [20, 21]. In addition, these studies on phantom limbs have led to the neuroscientific investigation and description of some of the underlying neurocognitive mechanisms for illusory own body perceptions enhancing not only our understanding of phantom limbs, but also improving our models of corporeal awareness, bodily processing and self consciousness for the affected body parts [21, 20, 22]. This is not yet the case for autoscopic phenomena and detailed knowledge about their underlying neurological mechanisms remains sparse, especially as recent research has largely focussed on the neurology of out-of-body experiences. Here, we present the case of a patient who suffered from autoscopic hallucinations during complex partial seizures due to neurocysticercosis. We will discuss our findings especially with respect to the etiology, neuroanatomy and associated neurological symptoms of autoscopic hallucinations. These findings will also be discussed and compared to the neurology of out-of-body experiences as well as figural visual hallucinations and experiential phenomena that may be difficult to distinguish from autoscopic hallucinations.

Case report

This 27 year-old female, right handed, patient, citizen of Cap Verde, was admitted to the hospital for complex partial seizures with secondary generalization. Complex partial seizures were diagnosed 4 years ago and the patient had been seizure free under anti-epileptic treatment (phenobarbital 100 mg daily). Due to irregular medication during her vacation in Geneva (Mai/June 2003) she presented several complex partial seizures (see description below) that were twice followed by secondary generalization. The neurological examination during the post-ictal period at the emergency room revealed only somnolence and preserved oral comprehension and expression and simple task execution without any focal deficits. Follow-up examinations were also normal including general physical

and neurological examination, haematological examination, blood chemical analyses, and screening of the serum for toxic substances. Blood analysis did not reveal eosinophilia. Radiographs of the chest were also normal. Lumbar puncture was performed and analysis of the cerebro-spinal fluid was normal. Magnetic resonance imaging (MRI) of the brain demonstrated bilateral multiple small parenchymal cystic lesions compatible of neurocysticercosis. Stages of cysts were variable and included all stages from vesicular cysts (with scolex), to colloidal cysts and nodules [23]. Lesions were generally hypointense in T1 and hyperintense in T2. Many cysts were enhanced by Gadolinium. All lesions had a diameter < 1 cm. Cysts were also found at the subcortical level (thalamus and central grey matter) as well as the corpus callosum. A CT scan revealed several degenerated, calcified cysts. There were a large number of cysts in right mesial occipital cortex (**Figure 2C**) extending to right mesial occipito-parietal cortex. These occipital and occipito-parietal cysts were surrounded by a prominent perilesional edema suggestive of active cysts. Standard EEG was normal. Complex partial seizures due to neurocysticercosis were diagnosed based on neuroradiological findings and treatment with Prazyquantel and corticoid therapy (15 mg/d for 20 days) initiated. Phenobarbital (100 mg/d) was restarted as an anti-epileptic treatment as the patient planned to return to Cap Verde where no other medications were easily accessible. A search for systemic cysticerci in blood and cerebro-spinal fluid (western blot) was negative. We followed the patient for six months. No further seizures were noted in this period. For about 1 year prior to the investigations reported here the patient suffered from the following visual hallucinations. In the central visual field or in the right parafoveal region she sees bright and colored lights consisting of many little stars that flickered (~1-2 Hz) within a circle of ~20 cm diameter at a distance of 2 meters. There were many different colors, but mainly yellow. These visual hallucinations were replaced progressively by a small image of herself that she saw in the central visual field, superimposed on the bright lights. The image was described as two-dimensional, showing her entire body in front-view. The image was fully dressed wearing the clothes that the patient was wearing at the moment. The image was not blurred, quite detailed and not transparent. The image did not move and the face was always motionless and expressionless (eyes and mouth were closed). This occurred with a frequency between 1x/week to 1x/month over the last year. The duration of these autoscopic hallucinations was variable and could last from several seconds up to ~2 minutes. The image did not speak nor were there any auditory hallucinations. There was no sensation of disembodiment, change in visuo-spatial perspective, or affinity with the autoscopic image (as is the case in out-of-body experiences and heautoscopy). There were no associated vestibular hallucinations of falling, flying,

elevation, rotation (but she mentioned the feeling as if she were falling towards the right without actually having fallen down). The patient did not notice any other illusory own body perceptions. She did not notice any mirror reversal between her body and the image nor any shared movements between her body and the image (as described by Zamboni et al. [24]. During the first occurrences of these visual manifestations she was afraid, but anxiety vanished during later autoscopic hallucinations.

Discussion

Based on the clinical symptoms and history as well as the results of the neuroradiological examinations we argue that the present patient suffered from autoscopic hallucinations due to complex partial seizures due to neurocysticercosis. To the best of our knowledge no previous case of autoscopic hallucinations due to neurocysticercosis has been reported although neurocysticercosis, caused by the infection of the central nervous system by the larval stage of the tape-worm *Taenia solium*, is the most common parasitic disease of the human central nervous system and is worldwide the most common cause of symptomatic epilepsy [23, 25]. Complex partial seizures leading to autoscopic hallucinations disappeared under anti-parasitic and anti-epileptic treatment. As epileptic seizures are the most frequent cause of autoscopic hallucinations [17], we suggest that autoscopic hallucinations might actually be quite common in regions with endemic neurocysticercosis especially if epileptogenic cysts are localized in occipital or occipito-parietal cortex as in the present patient. Autoscopic hallucinations are generally described as pseudo-hallucinations and patients report seeing a static image of their body in the central visual field without disembodiment or changes in their visuo-spatial perspective. Further classical findings about the seen double were present in our case. The double was seen in front-view, expressionless [26, 1 (case 6), 24], and was performing no actions or movements ([26, 1 (case 6)]; for exceptions see Zamboni et al. [24] and Bhaskaran et al. [27]). There also was no affinity or thought communication between patient and hallucinated double and this was also absent in all previous cases of autoscopic hallucinations [17]. The present observation is corroborating very early case descriptions of autoscopic hallucinations that have been called visual or "specular" hallucinations ([28, 29]; see also Brugger et al. [2], Blanke and Mohr [17] as well as 7 more recent case reports in whom CT or MRI data were available [10, 27, 1, 26, 24]). In these latter cases, the double was localized either in the central visual field [1 (case 6), 24] or in the contralesional visual field [10, 27, 26], associated with lateralized or central elementary visual hallucinations. These data suggest that autoscopic hallucinations in our patient were due to

interference with visual mechanisms in occipital cortex. Accordingly, no vestibular hallucinations of falling, flying, elevation, or of rotation were mentioned by our patient as well as no auditory hallucinations or body schema disturbances. This is compatible with previous reports and allows to distinguish autoscopic hallucinations from out-of-body experiences of neurological origin who are frequently associated with all latter three symptoms [17]. Although we could not objectify hemianopia or visual field loss in the present case, we speculate that a more fine-grained quantitative visual field analysis, especially in the ictal or postictal phase, might have revealed such a deficit [2]. As in the present case, autoscopic hallucinations are almost never associated with sensori-motor deficits [17] allowing to exclude interference with more anterior structures in fronto-parietal cortex (especially as many neurocysticercosis lesions were also found in this region in the present patient). Presence of elementary visual hallucinations and an occipital origin in autoscopic hallucinations was also found by Blanke and Mohr [17] who analyzed 20 neurological cases with autoscopic hallucinations due to focal brain damage (occipital involvement was found in 60% of cases with autoscopic hallucinations, but only in 20% of cases with out-of-body experiences). In the 7 aforementioned cases of autoscopic hallucinations that were confirmed by CT

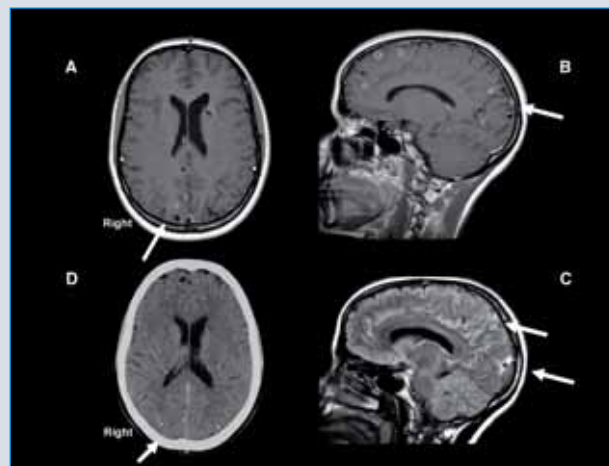


Figure 2: Neurocysticercosis. Multiple small parenchymal cystic lesions compatible of neurocysticercosis are shown. Stages of cysts were variable and included all stages from vesicular cysts (with scolex), to colloidal cysts and nodules (Figures 2A, B). A CT scan showed several calcified cysts ((Figure 2D). There were a large number of cysts in right mesial occipital cortex extending to right mesial occipito-parietal cortex (Figures 2B, C). These occipital and occipito-parietal cysts were surrounded by a prominent perilesional edema (Figure 2C) suggestive of active cysts.

and MRI [10 (case 6), 27, 1 (case 6), 26 (cases 1,2,3), 24], occipital lobe involvement was found in all cases (Figures 3A-G), parietal lobe involvement in 71% and temporal only in 14% pointing to interference with occi-

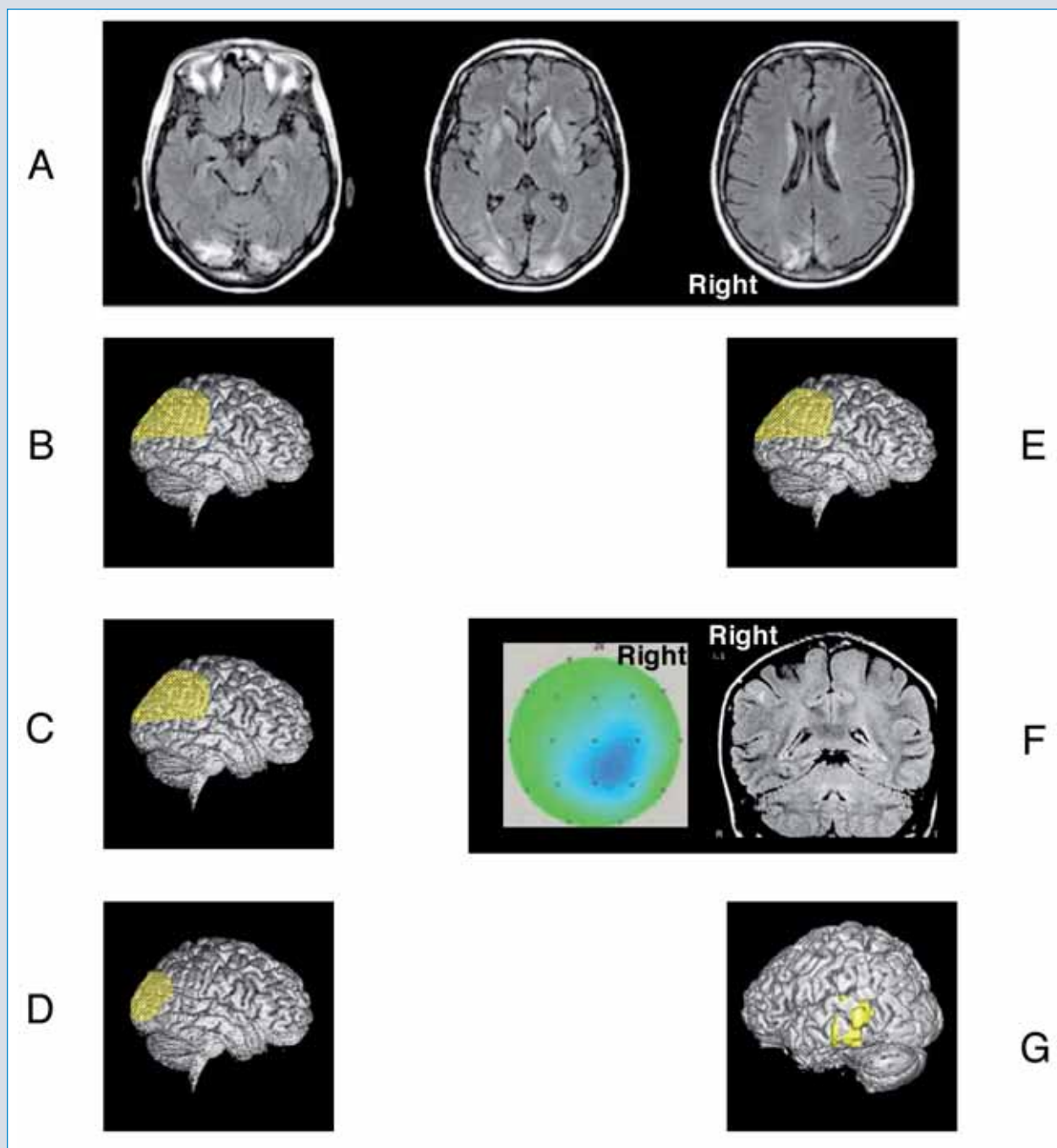


Figure 3: Lesion location in 7 previous cases with autoscopic hallucinations. Figure 3A shows a MRI-defined bi-occipital lesion extending to the right parieto-occipital cortex as reported by Zamboni et al. [24], reproduced with permission. Lesion location (indicated in yellow) of patients described by Maillard et al. [26] (case 2, Figure 3B), Maillard et al. [26] (case 3, Figure 3C), Bhas-karan et al. [27] (Figure 3D), and Kölmel et al. [10] (Figure 3E) is estimated on a lateral cortical view for all patients. Note the predominance of parieto-occipital and occipital lesions. The MRI-defined right temporoparieto-occipital lesion reported by Maillard et al. [26] (case 1, Figure 3F) is shown with topographic distribution of interictal epileptic activity over the right parie-to-occipital region. Figure 3G shows lesion location of the patient reported by Blanke et al. [1] (case 6) in temporo-occipital cortex.

pito-parietal mechanisms in autoscopic hallucinations (Figure 4A). The occipital and parieto-occipital origin in the present patient was confirmed by MRI and CT revealing large and active lesions in this region (Figure 2). Moreover, this parieto-occipital lesion location in autoscopic hallucinations is distinct from that observed

in out-of-body experiences that have been linked to right temporo-parietal cortex (Figure 4B). The fact that most previous studies have analyzed the lesion location for all three forms of autoscopic phenomena together (including cases with heautoscopy) might thus explain why some authors reported no lobar or hemispheric

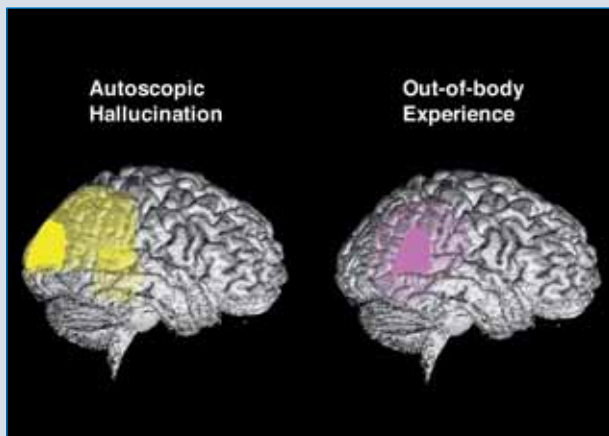


Figure 4: Mean lesion location in cases with autoscopic hallucinations and out-of-body experiences. The lesions of the seven patients of figure 3 and the present patient with autoscopic hallucinations (light yellow) have been drawn onto the same lateral brain showing that lesion overlap (dark yellow area) centers in parieto-occipital cortex. The same approach for patients with out-of-body experiences (see Blanke and Mohr, [17]) revealed the center of lesion overlap at the temporo-parietal junction (pink area) with maximal lesion overlap at the dark pink area.

predominance [16, 8, 13]. That patients with autoscopic hallucinations have significantly more often involvement of the occipital lobe is also concordant with the association with visual hallucinations and hemianopia and the frequently observed bright coloring of the double that contrasted with the colorless, pale, and misty appearance of the double in heautoscopy or out-of-body experiences [5].

Autoscopic hallucinations need to be distinguished from experiential phenomena and figural hallucinations. Experiential phenomena are defined as dreamlike scenic hallucinations that combine elements of complex visual and/or auditory perception and memory [30 - 33]. During experiential phenomena patients experience to see or hear a complex scene with many different objects and persons often related to previous life events [30, 33] and caused by epileptic discharge or electrical stimulation of the lateral temporal cortex and/or medial temporal structures. Figural hallucinations refer to non-scenic visual hallucinations of single or multiple people, not including the own body, and have been described after damage to extrastriate temporo-occipital cortex. In conclusion, patients suffering from autoscopic hallucinations typically experience to see a static and expressionless image of themselves without any sensation of disembodiment or altered visuo-spatial perspective. This image is localized either in the central visual field or lateralized to the side of visual field deficits and associated with bright and colourful elementary visual hallucinations due to damage to occipital or parieto-occipital cortex. Recently reported neurological cases of autoscopic hallucinations were due to epilepsy, stroke, hematoma, and

tumor. Autoscopic hallucinations are easily distinguishable from out-of-body experiences during which an image of one's body is seen in the central visual field, but associated with a strong sensation of disembodiment and from an elevated, non-body centered visuo-spatial perspective. Moreover, patients with out-of-body experiences do not suffer from visual, but frequent vestibular hallucinations of flying, floating, and falling and are due to damage in right temporo-parietal cortex due to similar neurological etiologies.

References

1. Blanke O, Landis T, Spinelli L, Seeck M. Out-of-body experience and auto-copy of neurological origin. *Brain* 2004; 127: 243-258
2. Brugger P, Regard M, Landis T. Unilaterally felt « presences »: The neuropsychiatry of one's invisible Doppelgänger. *Neuropsychiatr Neuropsychol Beh Neurol* 1996; 9: 114-122
3. Blanke O, Ortigue S, Coeytaux A et al. Hearing of a presence. *NeuroCase* 2003; 9: 329-339
4. Arzy S, Seeck M, Ortigue S et al. Induction of an illusory shadow person. *Nature* 2006; 443: 287
5. Brugger P, Regard M, Landis T. Illusory reduplication of one's own body: phenomenology and classification of autoscopic phenomena. *Cogn Neuropsychiatr* 1997; 2: 19-38
6. Grüsser OJ, Landis T. The splitting of "I" and "me": heautoscopy and related phenomena. In: Cronly-Dillon JR (ed) : *Visual Agnosias and Other Disturbances of Visual Perception and Cognition*. Amsterdam: MacMillan, 1991: 297-303
7. Brugger P. Reflective mirrors: perspective taking in autoscopic phenomena. *Cogn Neuropsychiatr* 2002; 7: 179-194
8. Devinsky O, Feldmann E, Burrows K, Bromfield E. Autoscopic phenomena with seizures. *Archives Neurology* 1989; 46: 1080-1088
9. Lunn V. Autoscopic phenomena. *Acta Psychiatrica Scandinavia* 1970; 46(Suppl 219): 118-125
10. Kölmel HW. Complex visual hallucinations in the hemianopic field. *J Neurol Neurosurg Psychiatry* 1985; 48: 29-38
11. Todd J, Dewhurst K. The double: its psycho-pathology and psychophysiology. *J Nerv Ment Dis* 1955; 122: 47-55
12. Lippman CW. Hallucination of physical duality in migraine. *J Nerv Ment Dis* 1953; 117: 345-350
13. Hécaen H, Ajuriaguerra J. L'Héautoscopie. En: *Méconnaissances et hallucinations corporelles*. Paris: Masson, 1952: 310-343
14. Menninger-Lerchenthal E. *Das Truggebilde der eigenen Gestalt*. Berlin: Karger, 1935
15. Lhermitte J. Les phénomènes héautoscopiques, les hallucinations spéculaires et autoscopiques. En : *L'image de notre corps*. Paris: L'Harmattan, 1939: 170-227
16. Denning TR, Berrios GE. Autoscopic phenomena. *Brit J Psychiatr* 1994; 165: 808-817
17. Blanke O, Mohr C. Out-of-body experience, heautoscopy, and autoscopic hallucinations of neurological origin. Implications for neurocognitive mechanisms of corporeal awareness and self-consciousness. *Brain Res Reviews* 2005; 50: 184-199
18. Metzinger T. *Being No One*. Cambridge: MIT Press, 2003
19. Blanke O, Ortigue S, Landis T, Seeck M. Stimulating illusory own-body-perceptions. *Nature* 2002; 419: 269-270

20. Ramachandran VS, Hirstein W. The perception of phantom limbs. *Brain* 1998; 121: 1603-1630
21. Halligan PW. Phantom limbs: The body in mind. *Cogn Neuropsychiatr* 2002; 7: 251-268
22. Tsakiris M, Hesse MD, Boy C et al. Neural signatures of body ownership: a sensory network for bodily self-consciousness. *Cer Cortex* (in press)
23. DeGiorgio CM, Medina MT, Duron R et al. Neurocysticercosis. *Epilepsy Currents* 2004; 4: 107-111
24. Zamboni G, Budredi C, Nichelli P. "Seeing oneself": a case of autoscopia. *Neurocase* 2005; 11: 212-215
25. Wallin MT, Kurtzke JF. Neurocysticercosis in the United States. *Neurology* 2004; 64: 1559-1564
26. Maillard L, Vignal JP, Anxionnat R et al. Semiologic value of ictal autoscopia. *Epilepsia* 2004; 45: 391-394
27. Bhaskaran R, Kumar A, Nayar PC. Autoscopia in the hemianopic field. *J Neurol Neurosurg Psychiatry* 1990; 53: 1016-1017
28. Féré C. Note sur les hallucinations autoscopiques ou spéculaires et sur les hallucinations altruistes. *Comptes Rendues Hebdomadaires des Séances et Mémoires de la Société de Biologie* 1891; 3: 451-453
29. Naudascher MG. Trois cas d'hallucinations spéculaires. *Ann Médico-Psychol* 1910; 68: 284-296
30. Penfield W. The role of the temporal lobe in certain psychical phenomena. *J Ment Sci* 1955; 101: 451-465
31. Gloor P, Olivier A, Quesney LF et al. The role of the limbic system in experiential phenomena of temporal lobe epilepsy. *Ann Neurol* 1982; 12: 129-144
32. Blanke O, Landis T, Seeck M. Electrical cortical stimulation of the human prefrontal cortex evokes complex visual hallucinations. *Epilepsy & Behavior* 2000; 1: 356-361
33. Vignal J-P, Maillard L, McGonigal A, Chauvel P. The dreamy state: hallucinations of autobiographical memory by temporal lobe stimulations and seizures. *Brain* 2006; 130: 88-99
34. Lukianowicz N. Autoscopical phenomena. *Arch Neurol Psychiatr* 1958; 80: 199-220

Address for correspondence:

Prof. Olaf Blanke

Laboratory of Cognitive Neuroscience

Brain-Mind Institute

Ecole Polytechnique Fédérale de Lausanne (EPFL)

CH 1015 Lausanne

Tel. 0041 21 6939621

Fax 0041 21 6939625

olaf.blanke@epfl.ch